

## Main Article

Martin Sylvester Otte takes responsibility for the integrity of the content of the paper

**Cite this article:** Otte MS, Mueller V, Burkhardt P, Endler CH-J, Klussmann JP, Luers JC, Grosheva M, Lang-Roth R. Cochlear measurement in computed tomography and magnetic resonance imaging data sets by the Otoplan measurement tool: a retrospective comparative study. *J Laryngol Otol* 2024;**138**: 869–873. <https://doi.org/10.1017/S0022215124000239>

Received: 20 August 2023

Revised: 4 November 2023

Accepted: 13 November 2023

First published online: 19 February 2024


### Keywords:

Cochlear implants; inner ear; cochlear implantation; hearing loss; sensorineural hearing loss

### Corresponding author:

Martin Sylvester Otte;  
Email: [martin.otte@uk-koeln.de](mailto:martin.otte@uk-koeln.de)

# Cochlear measurement in computed tomography and magnetic resonance imaging data sets by the Otoplan measurement tool: a retrospective comparative study

Martin Sylvester Otte<sup>1</sup> , Verena Mueller<sup>1</sup>, Pauline Burkhardt<sup>1</sup>,  
Christoph Hans-Juergen Endler<sup>2</sup>, Jens Peter Klussmann<sup>1,3</sup>,  
Jan Christoffer Luers<sup>1</sup>, Maria Grosheva<sup>1</sup> and Ruth Lang-Roth<sup>1</sup>

<sup>1</sup>Department of Otorhinolaryngology, Head and Neck Surgery, Faculty of Medicine and University Hospital Cologne, University of Cologne, Cologne, Germany, <sup>2</sup>Department of Diagnostic and Interventional Radiology, University Hospital Bonn, Bonn, Germany and <sup>3</sup>Center for Molecular Medicine Cologne, Faculty of Medicine and University Hospital Cologne, University of Cologne, Cologne, Germany

## Abstract

**Background.** Using Otoplan software, it is possible to measure the cochlea before cochlear implant surgery. Until now, computed tomography (CT) of the cochlea has been necessary for this purpose. The aim of this study was to find out whether measuring the cochlea with magnetic resonance imaging (MRI) using Otoplan is possible with the same accuracy.

**Methods.** The cochlea of 44 patients of the local cochlear implant centre was measured by Otoplan using high-resolution CT-bone and MRI images, and the determined lengths were compared.

**Results.** No significant difference was found between the cochlear lengths measured, regardless of whether the length measurement was based on a CT or an MRI data set.

**Conclusion.** For the determination of cochlear length prior to cochlear implant surgery, MRI images are just as suitable as CT images, therefore CT is not mandatory for length measurement by Otoplan, which could reduce the patient's radiation exposure.

## Introduction

The purpose of this study was to investigate the hypothesis that the measurement of cochlear duct length based on magnetic resonance imaging (MRI) data sets is as good as that based on computed tomography (CT) temporal bone images. To this end, a retrospective comparative study of these two imaging modalities was designed.

Cochlear implants enable hearing rehabilitation in cases of profound sensorineural hearing loss or deafness by electrical stimulation of the auditory nerve. The individualised planning of a cochlear implant operation is becoming more and more important.<sup>1–3</sup> The providers of implants have specific electrodes in their portfolio to optimally utilise the anatomical length of the cochlea, to take anatomical peculiarities into account or to provide individualised frequency-specific hearing loss.

For the pre-operative measurement of the cochlear duct length, Otoplan (CAScination AG, Bern, Switzerland, in collaboration with Med-El Corporation, Innsbruck, Austria) has recently become available. It is a tool to determine the length of the cochlear duct from a Dicom-formatted data set of a thin-slice CT temporal bone. Other features of the program also make it possible to estimate the cochlear place frequency using the Greenwood function.<sup>1,4</sup> Until now, a thin-slice CT scan of the temporal bone was required for evaluation with Otoplan.<sup>5</sup>

However, not all centres do a CT scan of the temporal bone prior to cochlear implant surgery. By contrast, a thin-slice magnetic resonance imaging (MRI) scan of the inner ear is always available, as this can confirm the fluid filling of the cochlea and the presence of the auditory nerve.<sup>6–8</sup> We therefore wanted to investigate with this study whether measuring the cochlea with Otoplan using MRI and CT data sets provides comparable results.

## Methods

The study used data sets from 27 patients who had both MRI inner-ear and CT temporal bone scans collected in preparation for cochlear implant surgery. Patients with structural abnormalities of the cochlea described in the original radiological report of CT or MRI were excluded from the study. This retrospective study was conducted in accordance with the principles of the Declaration of Helsinki and its later amendments as well as the regulations of the Ethics Commission of the Medical Faculty of the University of Cologne.

The high-resolution CT scans were obtained using a Philips Brilliance 64-slice CT scanner (Philips Healthcare, Best, The Netherlands). The scan volume included the

petrous bone region with the external auditory canal, the middle ear and the inner ear. Reformatted images were reconstructed with a slice thickness of 0.67 mm and an increment of 0.33 mm in the axial and oblique coronal planes using a soft tissue and bone window.

Magnetic resonance images were acquired using a whole-body 3.0 Tesla (T) Philips Ingenia System (Philips Healthcare) with a dedicated head coil. A standard T2-weighted turbo spin echo sequence with a slice thickness of 5 mm (matrix  $576 \times 576$ , FOV  $230 \times 200$  mm, in-plane resolution  $0.4 \times 0.35$  mm) was obtained of the entire head in the axial plane, followed by a three-dimensional T2-weighted turbo spin echo sequence with a driven equilibrium radio frequency reset pulse and a slice thickness of 1 mm (matrix  $512 \times 512$ , Field of View  $180 \times 162$  mm, in-plane resolution  $0.35 \times 0.32$  mm) through the region of the cerebellopontine angle and the inner ear. With the driven equilibrium radio frequency reset pulse applied at the end of a turbo spin echo train, an acceleration of image acquisition was achieved with high spatial resolution of the temporal bone and the facial and vestibulocochlear nerves within the internal auditory canal. Maximum intensity projection images of the vestibule, cochlear and semicircular canals were obtained.

The data sets were uploaded into tablet-based software (Otoplan, version 2). For measurement of the cochlear duct length, the user, a surgeon with expertise in the field of ear and cochlear implant surgery first identified the modiolus in the CT (defined as the centre of the modiolus in the three-dimensional rendered cochlear view). Then the round window and the outer boundary of the cochlea opposite the round window were marked. Subsequently, an orthogonal line was drawn through the connecting line of these two points and the modiolus, and their intersections with the outer cochlear wall were also marked (Figure 1). These points were entered manually by the user into the cochlear view of the program. For more precise placement of the measurement points, an external computer mouse was connected to the tablet.

Otoplan calculates the cochlear duct length according to the elliptic-circular approximation method, which allows a more

precise estimation of the cochlear duct length compared with other methods.<sup>9</sup> For this purpose, user-defined points are used to calculate the cochlear diameters (Figure 1), which are then used to derive the cochlear duct length.

The MRI data sets were also read into the Otoplan system and the above-mentioned landmarks were determined in the same way. The software then determined the cochlear duct length from these points.

First all CT and then all MRI data sets were evaluated, whereby the order of the evaluated imaging was random and anonymised. The measurements were all taken by the same examiner.

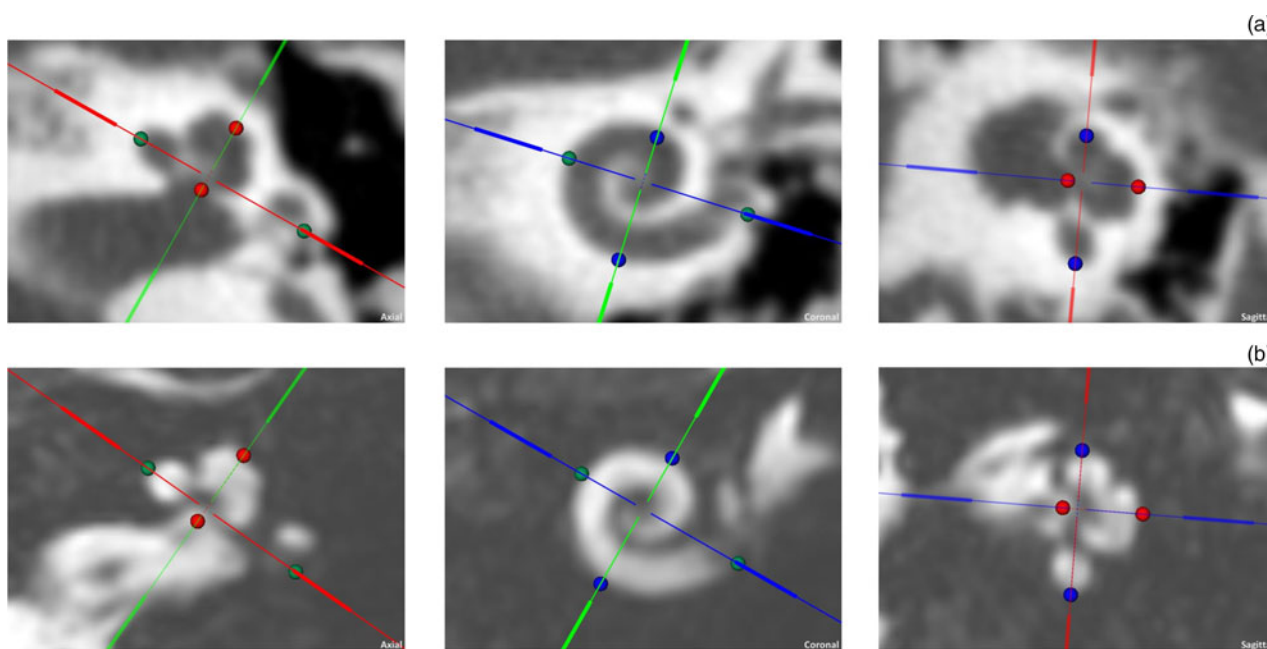
Statistical analysis was performed using SPSS v. 24 (SPSS Inc., Chicago, USA). The Kolmogorov–Smirnov test and the Shapiro–Wilk test were applied before to check the data distribution. As both tests showed that the data were normally distributed, a paired *t*-test was conducted to investigate the difference between the MRI and CT cochlear lengths. In addition, the comparability of the two measurement methods was visualised via a Bland–Altman plot.<sup>10</sup> The significance level was set to  $p \leq 0.05$ . The data are presented as average values ( $\pm$  standard error of the mean).

## Results

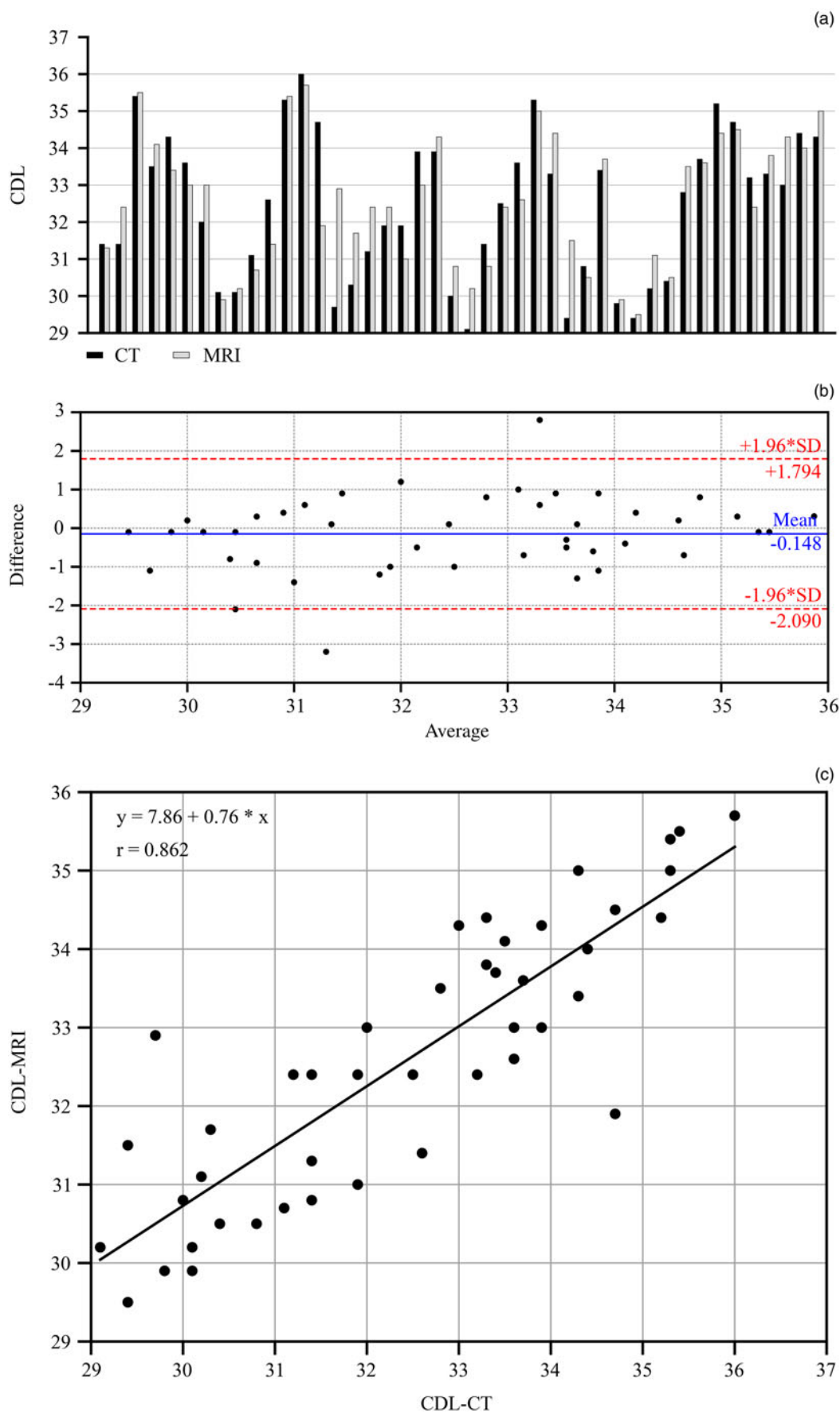
For this study, the data sets of 27 patients were analysed with a balanced gender ratio of 14 male patients and 13 female patients. The mean age of the patients was 55.22 years, with all but 2 patients having reached 18 years of age. In 10 patients, due to a cochlear implant already in place, only the other, non-operated, side was considered, so that a total of 44 corresponding CT and MRI data sets of the cochlea were used.

Cochlear duct length was measured in each case using the method described above. The mean cochlear duct length was 32.443 mm ( $\pm 0.294$  mm) from the CT scans and 32.591 mm ( $\pm 0.2605$  mm) from the MRI data.

The cochlear duct lengths collected using the MRI and CT data were not statistically different ( $t(43) = -0.989$ ,  $p = 0.328$ ). There was good correlation between the lengths determined by



**Figure 1.** Exemplary image of a cochlea in (a) computed tomography and (b) magnetic resonance imaging in Otoplan after manual definition of the outer boundaries of the cochlea and alignment of the connecting lines through the modiolus.



**Figure 2.** (a) Visualisation of the determined cochlear lengths in CT and MRI of all subjects. (b) With the exception of two outliers, all differences between the two measurement methods were in the interval of  $\pm 1.96$  times the standard deviation around the mean value of the differences. (c) With a correlation coefficient of 0.862, a good correlation was found between cochlear duct lengths measured by CT (CDL-CT) and MRI (CDL-MRI). CDL = cochlear duct length; CT = computed tomography; MRI = magnetic resonance imaging; SD = standard deviation

MRI and CT according to the Pearson analysis ( $r = 0.862$ ,  $p < 0.01$ ; Figure 2). The relationship between the two measurements could be described with the correlation function: cochlear duct length–MRI =  $7.86 + 0.76 \times$  cochlear duct length–CT.

The graphical representation of the data in the Bland–Altman plot showed that, except for two outliers, all differences between the paired measurements were within the required interval of  $\pm 1.96 \times$  standard deviation around the mean value of the differences (Figure 2).

## Discussion

The results from this study showed that the cochlear duct length calculated using Otoplan does not differ when it is determined from a CT or a thin-slice MRI data set. The results of the measurement methods correlated well with each other and did not differ significantly. With the exception of two outliers, the differences between the respective measurement methods were all within the interval required by Bland and Altman for the comparison of two measurement methods.<sup>10</sup>

It has been shown several times in the literature that MRI images can be used to measure the cochlear duct length.<sup>11–13</sup> With regard to the Otoplan program, however, there are different statements in the literature. While the study of Weber *et al.* produced different results in the application of MRI to CT data and thus cast doubts about the application of MRI imaging in Otoplan,<sup>14</sup> Thomas *et al.* had already produced consistent results in the application of both types of imaging.<sup>15</sup> Our study supports these results.

While imaging of the cochlear and auditory nerves by MRI is routinely performed prior to cochlear implant surgery,<sup>16</sup> the need for pre-operative CT imaging is questioned by some surgeons.<sup>17</sup> Even though other surgeons value CT because of the better visualisation of bony structures before cochlear implant surgery, it can be concluded from this study that CT imaging is not necessary solely for the application of Otoplan.

- The Otoplan tool provides a way to measure the cochlear duct length before cochlear implant surgery. This can help with individual surgery planning and the choice of electrode length
- So far, Otoplan has been used mainly for computed tomography (CT) imaging
- This study shows that it is possible to calculate the cochlear duct length based on magnetic resonance imaging slice images with the same quality as on CT images
- It was found that Otoplan can also be used when CT is not available

The reduction of one imaging can bring a cost saving.<sup>18</sup> In addition, a significantly increased radiation exposure for the patient can be prevented by omitting CT examination of the temporal bone.<sup>19,20</sup> This is particularly critical in view of the fact that many patients also undergo further CT imaging post-operatively or intra-operatively to check their position.<sup>16,21</sup> Especially in children, the saving of radiation doses is particularly important due to the carcinogenicity of CT radiation<sup>22</sup> and fortunately there are efforts to also carry out post-operative quality control after cochlear implant surgery by MRI.<sup>23</sup>

Setting the points in the Otoplan cochlear view on the MRI slides is more difficult than in CT, where the bony boundaries and the round window stand out better (Figure 1), therefore, as in our case, the recordings should be as thin as possible. Nevertheless, the use of Otoplan with MRI alone could be more difficult for the inexperienced examiner and lead to

incorrect measurements. To explore this, further prospective studies should follow to determine the predictive power of MRI-based Otoplan analysis on the choice of the correct electrode.

**Acknowledgements.** This study was supported by Med-El, who provided the tablet-based version of Otoplan.

**Competing interests.** None declared

**Data availability statement.** The data for the study are with the corresponding author.

## References

- 1 Dhanasingh A. Research software in cochlear duct length estimation, Greenwood frequency mapping and CI electrode array length simulation. *World J Otorhinolaryngol – Head Neck Surg* 2021;7:17–22
- 2 Lovato A, Marioni G, Gamberini L, Bonora C, Genovese E, de Filippis C. OTOPLAN in cochlear implantation for far-advanced otosclerosis. *Otol Neurotol* 2020;41:e1024
- 3 Ricci G, Lapenna R, Gambacorta V, Della Volpe A, Faralli M, Di Stadio A. OTOPLAN, cochlear implant, and far-advanced otosclerosis: could the use of software improve the surgical final indication? *J Int Adv Otol* 2022;18:74–8
- 4 Greenwood DD. A cochlear frequency-position function for several species – 29 years later. *J Acoust Soc Am* 1990;87:2592–605
- 5 Chen Y, Chen J, Tan H, Jiang M, Wu Y, Zhang Z *et al.* Cochlear duct length calculation: comparison between using otoplan and curved multiplanar reconstruction in nonmalformed cochlea. *Otol Neurotol*. 2021;42:e875–80
- 6 Guirado CR, Martínez P, Roig R, Miroso F, Salmerón J, Florensa F *et al.* Three-dimensional MR of the inner ear with steady-state free precession. *AJNR Am J Neuroradiol* 1995;16:1909–13
- 7 Biller A, Bartsch A, Knaus C, Müller J, Solymosi L, Bendszus M. Neuroradiological imaging in patients with sensorineural hearing loss prior to cochlear implantation [in German]. *Rofo* 2007;179:901–13
- 8 Tanioka H, Shirakawa T, Machida T, Sasaki Y. Three-dimensional reconstructed MR imaging of the inner ear. *Radiology* 1991;178:141–4
- 9 Schurz D, Timm ME, Batsoulis C, Salcher R, Sieber D, Jolly C *et al.* A novel method for clinical cochlear duct length estimation toward patient-specific cochlear implant selection. *OTO Open* 2018;2:2473974X18800238
- 10 Bland JM, Altman DG. Statistical methods for assessing agreement between two methods of clinical measurement. *Lancet* 1986;327:307–10
- 11 Eser MB, Atalay B, Dogan MB, Gündüz N, Kalcioğlu MT. Measuring 3D cochlear duct length on MRI: is it accurate and reliable? *AJNR Am J Neuroradiol* 2021;42:2016
- 12 Nash R, Otero S, Lavy J. Use of MRI to determine cochlear duct length in patients undergoing cochlear implantation. *Cochlear Implants Int* 2019;20:57–61
- 13 Taeger J, Müller-Graff FT, Ilgen L, Schendzielorz P, Hagen R, Neun T *et al.* Cochlear duct length measurements in computed tomography and magnetic resonance imaging using newly developed techniques. *OTO Open* 2021;5:2473974X211045312
- 14 Weber L, Kwok P, Picou EM, Wendl C, Bohr C, Marcrum SC. Vermessung der Cochlea mittels eines Tablet-basierten Softwarepakets: Einfluss der Bildgebungsmodalität und des Untersucherhintergrunds. *HNO* 2022;70:769–77
- 15 Thomas JP, Klein H, Haubitz I, Dazert S, Völter C. Intra- and interrater reliability of CT- versus MRI-based cochlear duct length measurement in pediatric cochlear implant candidates and its impact on personalized electrode array selection. *J Pers Med* 2023;13:633
- 16 Aschendorff A. Imaging in cochlear implant patients. *GMS Curr Top Otorhinolaryngol Head Neck Surg* 2011;10
- 17 Ellul S, Shelton C, Davidson HC, Harnsberger HR. Preoperative cochlear implant imaging: is magnetic resonance imaging enough? *Otol Neurotol* 2000;21:528–33
- 18 Paul AB, Oklu R, Saini S, Prabhakar AM. How much is that head CT? Price transparency and variability in radiology. *J Am Coll Radiol* 2015;12:453–7
- 19 Giacomuzzi SM, Torbica P, Rieger M, Lottersberger C, Peer S, Peer R *et al.* Radiation exposure in single slice and multi-slice spiral CT (a phantom study) [in German]. *Rofo* 2001;173:643–9

- 20 Neufang KF, Zanella FE, Ewen K. Radiation doses to the eye lenses in computed tomography of the orbit and the petrous bone. *Eur J Radiol* 1987;**7**:203–5
- 21 Vogl TJ, Tawfik A, Emam A, Naguib NNN, Nour-Eldin A, Burck I *et al.* Pre-, intra- and post-operative imaging of cochlear implants. *Rofo* 2015;**187**:980–9
- 22 Joshi VM, Navlekar SK, Kishore GR, Reddy KJ, Kumar ECV. CT and MR imaging of the inner ear and brain in children with congenital sensorineural hearing loss. *RadioGraphics* 2012;**32**:683–98
- 23 Riemann C, Scholtz LU, Gehl HB, Schürmann M, Sudhoff H, Todt I. Evaluation of cochlear implant electrode scalar position by 3 Tesla magnet resonance imaging. *Sci Rep* 2021;**11**:21298