



Unexpected and atypical clinical presentation of myocardial infarction in infants and children: complex pathogenesis of progressive and lethal disease

Original Article

Cite this article: Matoq A, Patel G, and Tsuda T (2024). Unexpected and atypical clinical presentation of myocardial infarction in infants and children: complex pathogenesis of progressive and lethal disease. *Cardiology in the Young*, page 1 of 8. doi: [10.1017/S1047951124026271](https://doi.org/10.1017/S1047951124026271)

Received: 12 July 2024
Revised: 4 August 2024
Accepted: 6 August 2024

Keywords:

Coronary anomaly; coronary steal; microangiopathy; myocardial ischaemia; thromboembolism; mortality

Corresponding author:

Takeshi Tsuda; Email: tsuda@nemours.org

Amr Matoq^{1,2}, Gina Patel¹ and Takeshi Tsuda¹ 

¹Nemours Cardiac Center, Nemours Children's Health Delaware, Wilmington, DE, USA and ²The Heart Institute, Cincinnati Children's Hospital, Cincinnati, OH, USA

Abstract

Background: Myocardial infarction is rare in children but frequently occurs unexpectedly with atypical presentation. It can cause a progressive lethal course unless prompt treatment is initiated. **Methods:** Paediatric cases of myocardial infarction diagnosed by the presence of ischaemic myocardial insults and symptomatic ventricular dysfunction were reviewed retrospectively. **Results:** Eighteen patients (5 days to 14 years of age; median 3 months) with myocardial infarction were studied. The aetiology was variable, including congenital coronary anomalies: anomalous left coronary artery from pulmonary artery (five patients), pulmonary atresia with intact ventricular septum with right ventricle-dependent coronary circulation (four), anomalous aortic origin of left coronary artery (three), and Williams syndrome with supravalvar aortic stenosis (one). Two acquired coronary anomalies occurred in one patient with undiagnosed Kawasaki disease with complete thrombotic obstruction of the left coronary artery and another with post-transplant cardiac allograft microangiopathy. Three patients developed thromboembolic coronary artery incidents in normal coronary anatomy. Fourteen patients were less than 1 year of age (78%). Electrocardiographic abnormalities were noted in all patients. Four patients required extracorporeal membrane oxygenation support for severe ventricular dysfunction, none of whom survived. Five patients underwent heart transplant. Five patients died during the same hospitalisation, and one patient died after discharge (overall mortality 33%). Transplant-free survival was 39%. **Conclusion:** Most myocardial infarction occurred in infants who presented with abrupt onset of non-specific clinical manifestations with progressively deteriorating haemodynamic status resulting in poor transplant-free survival rate. Early diagnosis and treatment are essential to prevent catastrophic outcomes.

Introduction

Myocardial infarction is defined as direct myocardial injury caused by disruption of myocardial oxygen delivery commonly accompanied by typical clinical manifestations, anginal chest pain and/or shoulder pain, in adults. Diagnosis of myocardial infarction is usually made by abnormal cardiac biomarkers indicating acute myocardial ischaemia and an abnormal electrocardiogram.¹ Myocardial infarction is rare in children, but myocardial necrosis is a relatively common coincidental autopsy finding.^{2,3} The most frequent cause of myocardial infarction in adults is coronary artery disease due to atherosclerosis,⁴ whereas the aetiology of myocardial infarction in infants and children are variable, including congenital or acquired coronary anomalies and thromboembolic events.^{2,5,6} Presentations of myocardial infarction in infants and children are non-specific and different from those known in adults, and outcomes are often devastating without timely diagnosis.⁶ However, available literature regarding myocardial infarction in childhood is scarce. In this study, we reviewed our experience in young patients diagnosed with myocardial infarction and aimed to characterise its underlying mechanisms in infants and children.

Materials and methods

This study was approved by the Institutional Review Board of Nemours Children's Health Delaware. We performed a retrospective chart review of patients diagnosed with myocardial infarction from 2014 to 2022 in Nemours Cardiac Center, Nemours Children's Health, Wilmington, Delaware, United States. We reviewed initial clinical presentation, serum biomarkers, electrocardiogram, echocardiogram, angiogram, treatment, and final outcomes. Diagnosis of myocardial infarction was determined by evidence of myocardial ischaemic injury (abnormal electrocardiogram and elevated serum troponin-I level) and disruption of

myocardial perfusion. Patients with myocarditis or trauma and those within 30 days after open heart surgery were excluded. Diagnostic electrocardiographic evidence of myocardial ischaemia was indicated by ischaemic ST-T abnormalities and/or prominent Q waves. Global or regional ventricular wall motion abnormality, echo-bright papillary muscle, and abnormal proximal coronary artery anomalies were regarded as positive echocardiographic findings for myocardial infarction. Normal range of troponin-I was defined as <0.03 ng/ml.

Results

Aetiology of myocardial infarction

Eighteen patients met the inclusion criteria. Ages ranged from 5 days to 14 years (median 3 months). Diagnosis and clinical presentation are summarised in Table 1.

Congenital coronary anomalies include five patients with anomalous left coronary artery from pulmonary artery, four patients with pulmonary atresia/intact ventricular septum with right ventricle-dependent coronary circulation, three patients with anomalous aortic origin of left coronary artery, and one patient with Williams syndrome with supravalvar aortic stenosis and proximal left coronary artery obstruction. Acquired coronary anomalies were found in two patients: one patient with multiple aneurysms and thrombotic occlusion of the left anterior descending coronary artery presumably after undiagnosed Kawasaki disease during infancy with coronary aneurysm (patient 14) and the other with post-transplant cardiac allograft microvasculopathy who showed normal coronary artery anatomy by recent coronary angiogram (patient 15). Three patients with myocardial infarction who were found to have angiographic evidence of coronary occlusion suggestive of thromboembolism revealed no evidence of underlying coronary abnormalities.

Clinical manifestations

Presenting symptoms varied widely according to the age of patients. Infants presented with non-specific clinical manifestations including fussiness, paleness, poor feeding, respiratory distress, congestive heart failure, and/or cardiogenic shock, whereas all three adolescents were encountered with more typical anginal chest pain and/or left shoulder pain. Three patients presented with sudden cardiac arrest following several hours of non-specific deteriorating clinical course: one with anomalous left coronary artery from pulmonary artery (patient 7), one with isolated thrombotic obstruction of left coronary artery aneurysm (patient 14), and the other with post-transplant cardiac allograft microangiopathy (patient 15). The presence of ventricular fibrillation was recorded by automated electronic defibrillator or hospital electrocardiographic monitor.

On admission, ST-T segment abnormalities and/or abnormal Q wave were noted in all 17 patients who had an ECG. All 14 patients who were tested for serum troponin I presented with elevated levels ranging from 0.07 to >440 ng/ml. Fourteen patients (78%) showed more than moderate-to-severe left ventricular systolic dysfunction by echocardiogram (including patient 18 with severe right ventricular dysfunction), whereas two patients presented with relatively preserved left ventricular systolic function (patients 11 and 15).

Three patients with anomalous aortic origin of left coronary artery presented with myocardial infarction. Patient 1, a 14-year-old male adolescent, who developed chest pain while playing

basketball, was brought to our emergency department because of worsening symptoms with dyspnoea and diaphoresis. Chest X-ray findings of cardiomegaly and pulmonary oedema prompted cardiology consultation when the diagnosis of anomalous aortic origin of left coronary artery was confirmed by echocardiogram. His serum troponin was markedly elevated (>440 ng/mL). As his clinical status continued to deteriorate after admission, he underwent reparative coronary surgery followed by extracorporeal membrane oxygenation support. He had one previous episode of syncope during exercise 2 years prior to the admission. Patient 2, a previously healthy 5-week-old infant, developed worsening respiratory distress and lethargy after 2 days of mild upper respiratory symptoms and subsequently presented with severe respiratory distress and cardiogenic shock. He underwent reparative coronary surgery because of poor haemodynamic status but did not recover ventricular function post-operatively on extracorporeal membrane oxygenation. Neither patient 1 nor patient 2 survived. Patient 3 was a previously healthy 14-year-old female adolescent who developed syncope during running at track practice following a similar episode occurred a week prior. On admission, she presented with severe chest pain, respiratory distress, poor peripheral perfusion, and pulmonary oedema on chest X-ray film. Echocardiogram confirmed the diagnosis of anomalous aortic origin of left coronary artery with moderately depressed left ventricular function. She was managed with supportive medical treatment for 4 weeks with complete resolution of symptoms and partial recovery of left ventricular systolic function, when she underwent unroofing of anomalous left coronary artery. She was discharged home 7 days after surgery in a stable condition.

All five patients with anomalous left coronary artery from pulmonary artery (patients 4–8) underwent surgical repair of anomalous coronary artery (two underwent Takeuchi procedure, two coronary reimplantation, and one subclavian anastomosis to left coronary artery). Although all anomalous left coronary artery from pulmonary artery patients survived the initial surgical procedures, one patient died at 41 days with sepsis (patient 6). One patient had persistent severe left ventricular dysfunction requiring mechanical circulatory support and later underwent heart transplant (patient 8). One patient underwent mitral valve repair at 9 months of age after initial anomalous left coronary artery from pulmonary artery repair, followed by mitral valve replacement at 3 years of age for progressive mitral regurgitation (patient 7).

Patient 9 with Williams syndrome who presented at 3 months of age with severe congestive heart failure due to myocardial infarction was found to have supravalvar aortic stenosis with a small left coronary cusp and redundant intimal tissue obstructing the orifice of diffusely hypoplastic left coronary artery (Figure 1A). No surgical intervention was offered due to the complex baseline anatomy. He was discharged home after 5 weeks of hospitalisation with multiple heart failure medications. Surprisingly, however, the left coronary artery demonstrated nearly normal growth with spontaneous regression of redundant intimal tissue at left coronary artery orifice and full recovery of left ventricular function by 16 months (Figure 1B).

Among the four patients with pulmonary atresia/intact ventricular septum with abnormal right ventricle-dependent coronary circulation, three had a prior Blalock–Taussig shunt. All were managed with inotropic support, and three underwent heart transplant. The fourth patient (patient 12) was discharged alive at 2 months of age, but later died at 6 months of age with necrotising enterocolitis and cardiac dysfunction.

Table 1. Clinical presentation of myocardial infarction in infants and children

	Diagnosis	Age	Presentation	Peak troponin* (ng/mL)	ECG	Echo	Intervention	Outcome (follow-up years)
1	AAOLCA (LCA from R sinus)	14 y	Exercise-related chest pain, diaphoresis, and pulmonary oedema	>440	ST segment abnormality; Q wave I and aVL	Global LV dysfunction	ECMO	Death†
2	AAOLCA (LCA from R sinus)	5 w	URI, cardiorespiratory failure	35.5	N/A	Global LV dysfunction	ECMO	Death†
3	AAOLCA (LCA from R sinus)	14 y	Exercise-related chest pain, dizziness, and syncope	>50	ST segment depression II, III, AVF, and V3–V6; ST segment elevation AVR, AVL, and V1–V2	Moderate LV dysfunction (LVEF 44%); hypokinesia of basal to apical anterior and antero-lateral segments	Systemic anticoagulation; surgical LCA unroofing	Asymptomatic, improving exercise capacity with PT (0.1)
4	ALCAPA	2 m	Cardiogenic shock	N/A	ST segment abnormality; T wave inversion; LVH	Severe LV dysfunction and dilation; echogenic papillary muscle; MR	Takeuchi repair	Asymptomatic (13)
5	ALCAPA	2 m	Cardiogenic shock; apnoea	N/A	Q waves I and aVL; T wave inversion	Severe LV dysfunction and dilation; echogenic papillary muscle; MR	Takeuchi repair	Asymptomatic (16)
6	ALCAPA	2 m	Cardiogenic shock; GBS meningitis	0.93	ST segment abnormality; T wave inversion; LVH	Severe LV dysfunction and dilation	Subclavian artery anastomosis to the LCA	Death†
7	ALCAPA	1.5 m	Cardiogenic shock; cardiac arrest (VF)	7.5	Q waves I and aVL; T wave inversion I, aVL, and V5–V6	Severe LV dysfunction, and dilation; echogenic papillary muscle; MR	LCA reimplantation, mitral valvuloplasty	Mitral valve repair (9 mo), mitral valve re-placement (3 yo)
8	ALCAPA	3 m	Feeding difficulty, respiratory failure	0.07	LVH; T wave inversion; LAE	Severe LV dysfunction, and dilation; echogenic papillary muscle; MR	LCA reimplantation, L-VAD	Transplant (0.7)
9	Williams syndrome with supraaortic AS, LCA obstruction	3 m	Respiratory distress, feeding intolerance	0.34	ST depression V3–V6, Q wave in aVL	Mild-to-moderate LV systolic dysfunction	Nitroglycerine, atenolol, and aspirin	Asymptomatic (3)
10	PA/IVS (RV-dependent coronary circulation)	3.5m	Hypotension, poor perfusion, fussiness	4.61	ST depression V2–V5; inverted T waves	Septal dyskinesia, severe LV dysfunction, mild MR	Inotropic support	Transplant (3)
11	PA/IVS s/p BT shunt	1m	Fussiness, hypotension, respiratory failure	0.37	ST depression V3–V6; inverted T waves	Mild LV dilation, mild MR, preserved systolic function	Inotropic support	Transplant (2)
12	PA/IVS s/p BT shunt (congenital absence of RCA)	5 d	Hypotension, tachycardia, lactatemia	41	ST depression V3–V4; diffuse T wave abnormality	Moderate LV systolic dysfunction, moderate MR, mild LV dilation	Inotropic support	Discharge alive. Death at 6 months
13	PA/IVS s/p BT shunt	15 d	Hypotension, non-sustained ventricular tachycardia	N/A	ST segment elevation V1–V2; depression V5–V6; diffuse T wave abnormality	Moderate LV systolic dysfunction, trivial MR, moderate LV dilation	Inotropic support	Transplant (13)
14	Undiagnosed atypical KD with LCA aneurysm	9 m	Cardiac arrest at home	106	ST segment abnormality; Q wave in I, aVL, and V1–V3	Severe LV dysfunction	LCA canalisation via hybrid approach; heart transplant	Transplant (4.5)

(Continued)

Table 1. (Continued)

Diagnosis	Age	Presentation	Peak troponin* (ng/mL)	ECG	Echo	Intervention	Outcome (follow-up years)
15 Post-transplant CAMV	2 y	Emesis, ascites, and lethargy; later cardiac arrest	N/A	Junctional rhythm, diffuse T-wave abnormality; RVH	Septal dyskinesia; low normal LV function	Anti-rejection regimen, ECMO	Death†
16 Thromboembolic, PFO, LCA occlusion, normal heart	14 y	Chest pain and upper extremity pain	66.9	ST segment abnormality, T wave inversion	LV regional wall hypokinesia; PFO	Systemic anticoagulation	Asymptomatic (4)
17 Thromboembolic, hypercoagulable, LCA occlusion, normal heart	3 m	Cardiac arrest upon induction for elective procedure	13.8	ST segment abnormality; Q wave I and aVL	Global LV dysfunction	Systemic anticoagulation	Asymptomatic (2)
18 HLHS s/p BDG; aortic root thrombus and occlusion of RCA	11 m	Lethargy, decreased intake and respiratory failure	191	Diffuse ST elevation; T wave abnormality; Q waves V1–4	Severe RV dysfunction, mild TR	Local thrombolysis, ECMO	Death†

*Normal troponin level: <0.03 ng/mL. AAOLCA = anomalous aortic origin of left coronary artery; ALCAPA = anomalous left coronary artery from pulmonary artery; AS = aortic stenosis; BDG = bidirectional Glenn; BT = Blalock-Taussig; CAMV = cardiac allograft microvasculopathy; ECG = electrocardiogram; ECMO = extracorporeal membrane oxygenation; GBS = group B streptococcus; HLHS = hypoplastic left heart syndrome; KD = Kawasaki disease; LAE = left atrial enlargement; LCA = left coronary artery; LV = left ventricle; L-VAD = left ventricular assist device; LVH = left ventricular hypertrophy; MR = mitral regurgitation; PFO = patent foramen ovale; PT = physical therapy; RVH = right ventricular hypertrophy; s/p = status post; TR = tricuspid regurgitation; URI = upper respiratory tract infection; VF = ventricular fibrillation.

In two patients with acquired coronary artery disease, the first patient with possible undiagnosed atypical Kawasaki disease (patient 14) presented with cardiogenic shock and was found to have complete occlusion of the left anterior descending coronary artery proximal to the diagonal branch (Figure 1C). The occluded left anterior descending coronary artery was recanalised with systemic anticoagulation and balloon angioplasty, when diffuse ectasia and aneurysm of coronary arteries were found (Figure 1D). However, because of persistent refractory heart failure, the patient subsequently underwent heart transplant. The second patient (patient 15) was a post-transplant patient who was admitted because of rejection. During the hospitalisation, the patient unexpectedly developed ventricular fibrillation and cardiac arrest, for which extracorporeal membrane oxygenation support was introduced. Coronary angiogram 7 months prior showed no identifiable abnormality in the major coronary arteries. The patient was subsequently weaned from extracorporeal membrane oxygenation support but eventually developed another cardiac arrest refractory to intensive resuscitation. Post-mortem histopathological examination of the heart demonstrated large areas of subendocardial necrosis and surrounding inflammation with all major coronary arterial branches showing areas of concentric fibrointimal proliferation with endothelial disruption and fibrin thrombi. Smaller intramyocardial venules and arterioles showed fibrin thrombi surrounding areas of ischaemia consistent with microangiopathy.

Two patients developed myocardial infarction due to thromboembolic events in normal coronary arteries. A previously healthy 14-year-old female presented with acute chest pain with elevation of serum troponin (patient 16) and was noted to have totally occluded left anterior descending artery by angiogram. After systemic anticoagulation, repeat angiogram revealed successful recanalisation of the occluded left anterior descending artery. She underwent transcatheter device closure of the patent foramen ovale before discharge. After discharge, an echocardiogram showed a full recovery of left ventricular function. A 3-month-old male infant (patient 15) developed cardiac arrest and persistent hypotension during the induction for elective surgery for cleft palate. An initial angiogram showed nearly obliterated left coronary artery ostia with delayed antegrade filling into the left coronary artery (Figure 1E and F). He was started on systemic anticoagulation and multiple heart failure medications and recovered left ventricular systolic function. Six weeks after the first cardiac catheterisation, however, a repeat coronary angiogram demonstrated complete ostial obliteration of the left coronary artery with retrograde filling of the left coronary artery from dominant right coronary artery system (Figure 1G and H). He was noted to have a hypercoagulable condition (antiphospholipid syndrome). A 19-month-old toddler (patient 18) with hypoplastic left heart syndrome with aortic atresia and mitral hypoplasia who underwent bidirectional Glenn surgical palliation presented a year later with myocardial infarction. Angiogram showed thrombus in the native aortic root with occlusion of the right coronary artery. The patient underwent intracoronary thrombolysis and required extracorporeal membrane oxygenation support but was complicated by severe multi-organ failure including massive stroke, for which the support was withdrawn.

Thirteen patients survived to hospital discharge (72%), but one patient died 4 months after discharge (patient 12). Transplant-free survival was 39% (7/18) with a mortality rate of 33% (6/18). Among patients with underlying coronary artery abnormalities (congenital or acquired), transplant-free survival was only

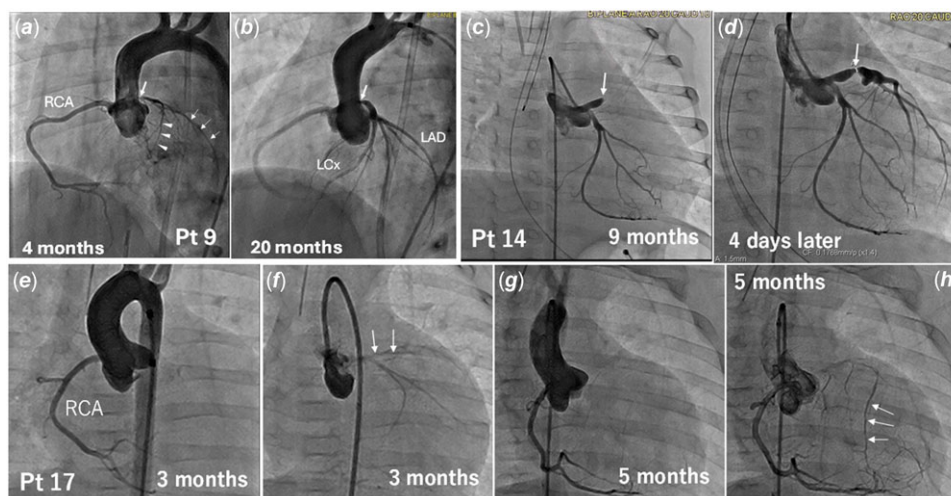


Figure 1. Coronary anatomy studied by angiography. (a and b) A 4-month-old male infant with Williams syndrome (patient 9) who presented with increased respiratory distress and feeding intolerance at 3 months of age. An initial aortogram at 4 months of age showing robust right coronary artery (RCA) and diffusely hypoplastic left coronary arteries: thin arrows pointing to the left anterior descending artery (LAD) and arrow heads indicating left circumflex artery (LCx). Note nearly obliterated proximal main left coronary artery (thick arrow) (a). Follow-up aortogram at 20 months of age. There is a substantial enlargement of proximal left main coronary artery (thick arrow) with normally grown left anterior descending artery and left circumflex artery (b). (c and d) Selective left coronary angiograms of patient 14 on admission (c) and after 4 days of systemic anticoagulation (d). Complete obliteration of the proximal left anterior descending artery (LAD) (arrow) (c). The left anterior descending artery was successfully recanalised with antegrade flow from the main coronary artery with dilated aneurysmal dilatation of proximal left anterior descending artery (d). Arrow indicates previous obliteration site. (e to h) Aortograms of patient 17. On admission at 3 months of age, an aortogram showed brisk filling of the robust right coronary artery (RCA) (e) with delayed antegrade filling of diffuse hypoplastic left coronary arteries (arrows indicate left anterior descending artery) (f). After 2 months of systemic anticoagulation with heparin, left ventricular function was significantly improved. However, a follow-up aortogram demonstrated complete obliteration of the proximal left coronary artery (g) with delayed retrograde filling via collateral vessels (arrows) from the dominant right coronary artery (h).

27% (4/15), whereas 67% (2/3) of patients with normal coronary anatomy survived.

Discussion

We studied 18 children who had variable presentations of myocardial infarction with and without underlying coronary anomalies. The majority of patients (78%) were infants who presented with a non-specific, acute progressive life-threatening illness. Diagnosis was made based on clinical presentation, electrocardiogram, serum troponin, and echocardiogram, but some cases required angiogram to confirm the anatomy of the coronary arteries. Patients with underlying coronary artery abnormalities, congenital or acquired, demonstrated poor prognosis compared with those without.

Clinical manifestations and diagnosis of myocardial ischaemia in young children

Typical anginal chest pain is present in adolescents and young adults, but not infants nor children which often precludes early clinical detection.⁶ In infants, non-specific irritability, respiratory distress, or gastrointestinal manifestation are the common presenting clinical manifestations representing direct myocardial impairment and subsequent haemodynamic deterioration or cardiorespiratory failure. Abnormal electrocardiogram findings suggestive of myocardial ischaemia were present in all 17 cases, in agreement with previous studies.^{7,8} Serum troponin was not studied in four of our patients, but the remaining 14 patients showed abnormally elevated troponin ranging from 0.07 to >440 ng/mL (normal < 0.03 ng/mL), which is consistent with a prior report.⁸

Early diagnosis of myocardial infarction and identification of underlying pathophysiology are essential for survival as

myocardial ischaemia can be reversed by appropriate treatment. Abnormal electrocardiogram and elevated serum troponin provide initial clues. Echocardiography will demonstrate ventricular systolic dysfunction with global or regional hypokinesia or echogenic papillary muscle suggestive of myocardial infarction and may identify abnormalities in proximal coronary artery anatomy.⁹ Coronary imaging studies are important in identifying the nature of underlying coronary vascular abnormalities; based on the findings, either surgical (coronary translocation or Takeuchi procedure for anomalous left coronary artery from pulmonary artery), interventional (angioplasty or stent placement for coronary stenosis), or medical management (local or systemic anticoagulation treatment for coronary embolism) may be indicated. As ischaemic myocardium worsens with time, prompt decision-making and execution of the procedure are of utmost importance.

Management of myocardial infarction in paediatrics

Management depends entirely on the underlying aetiology. Patients with congenital coronary anomalies frequently require surgical correction. Operative mortality of anomalous left coronary artery from pulmonary artery repair, regardless of the procedure, has been reported as 023%.¹⁰ When severe left ventricular dysfunction and/or significant arrhythmia is present, the use of post-operative mechanical circulatory support as a bridge to recovery has been reported with good results.¹¹ Recovery of left ventricular function over time occurs in most patients^{10,12,13} with or without re-operation for mitral regurgitation. The need for re-operation and/or transplant is higher when mechanical circulatory support is used.¹³ Surgical repair of anomalous aortic origin of coronary artery (both anomalous right coronary artery from left sinus or left coronary artery from right sinus) is reportedly safe and feasible with no accounts of mortality in several studies.^{14,15}

Acute myocardial infarction secondary to coronary thromboembolic disease is rare in paediatrics. In patients with giant aneurysm secondary to Kawasaki disease, the freedom from coronary thrombi at 9 years mean follow-up was 64%.¹⁶ In another report, incidence of death, myocardial infarction, and coronary artery bypass graft were 6%, 23%, and 37% respectively, at median follow-up of 20 years.¹⁷ Coronary artery thromboembolism has also been reported in patients with a hypercoagulable state secondary to nephrotic syndrome¹⁸ and has been reported in a patient with hypoplastic left heart syndrome following second stage palliation.¹⁹ Management of these conditions includes local and/or systemic thrombolysis and anticoagulation. In patient 16, no specific aetiology for coronary thromboembolism was found except that the patient had patent foramen ovale.

Responses to treatment were variable and unpredictable in some children with coronary flow obstruction (Figure 1). An infant with Williams syndrome (patient 9) showed spontaneous regression of redundant intimal tissue at the left coronary artery orifice with normal growth of entire left coronary artery from diffusely hypoplastic status without any interventions other than heart failure management. After systemic anticoagulation, patient 14 revealed successful recanalisation of the proximal left anterior descending artery but with no recovery of damaged left ventricular myocardium, whereas patient 17 demonstrated full recovery of left ventricular function despite complete obliteration of proximal left coronary artery with a retrograde filling by collateral vessels from the right coronary artery. In the latter case, supportive heart failure management to reduce ventricular load might have substantially contributed to the recovery of impaired young myocardium by the initial ischaemic insults.

Pathophysiology of myocardial infarction in infants and children

Incidence of myocardial infarction is not widely reported in infants and children. Incidence of myocardial necrosis in infants was reported to be 10–29% in random necropsy, but the causal relationship of myocardial infarction and death was not clearly identified.^{2,20} Acute myocardial ischaemic injury may induce two major pathological outcomes: myocardial infarction (local tissue damage) and sudden cardiac arrest due to ventricular fibrillation. The anomalous left coronary artery from pulmonary artery, pulmonary atresia/intact ventricular septum with right ventricle-dependent coronary circulation, and congenital coronary ostial obstruction commonly present with myocardial infarction (local myocardial necrosis due to disrupted oxygen delivery), whereas anomalous aortic origin of left coronary artery tends to present with syncope, ventricular fibrillation, or sudden cardiac death (abrupt disruption of cardiac rhythm).²¹ However, these clinical presentations may vary substantially and often overlap.

There are three major mechanisms in which myocardial ischaemia resulted in myocardial infarction in our patients. One is obstruction of antegrade coronary flow seen in coronary thromboembolism and acquired coronary diseases. There are a few studies reporting the incidence of atherosclerotic coronary artery disease in adolescents,^{22,23} but there were no cases of coronary artery disease in our cohort. The second mechanism is myocardial steal phenomenon seen in anomalous left coronary artery from pulmonary artery and pulmonary atresia/intact ventricular septum with right ventricle-dependent coronary circulation, in which the ischaemic event is, in part, induced by

haemodynamic changes, not solely by anatomical obstruction.¹² The third category is coronary microangiopathy or coronary microvascular dysfunction, as noted in patient 13. The diagnosis of coronary microvascular dysfunction is challenging without direct tissue examination or provocative study to assess coronary flow reserve, which are not commonly indicated for infants and small children.²⁴

Mechanisms of myocardial infarction in three anomalous aortic origin of left coronary artery cases remained undetermined. The post-mortem histopathological examination of the myocardium of two death cases with anomalous aortic origin of left coronary artery (patients 1 and 2) demonstrated massive myocardial necrosis and extensive scar formation with no specific clue regarding potential mechanisms. Although most anomalous aortic origin of left coronary artery patients present with either acute cardiac arrest or sudden cardiac death due to ventricular fibrillation during exercise or coincidental echocardiographic findings in asymptomatic patients,²⁵ there are a few isolated case reports of acute myocardial infarction by anomalous aortic origin of left coronary artery, none of which addressed possible mechanisms of myocardial infarction.^{26–28} In all three of our anomalous aortic origin of left coronary artery cases, proximal left coronary artery was wide open on admission. Initial myocardial insults might have caused severe left ventricular dysfunction and increased left ventricular filling pressure, resulting in poor cardiac output, decreased coronary perfusion, increased myocardial oxygen demand, and subendocardial ischaemia, which further deteriorated myocardial oxygen supply–demand mismatch. This uncontrolled vicious cycle involving ventricular dysfunction and progressive myocardial ischaemic insults might have caused the progressive lethal outcomes in these cases. In addition, detrimental effects of reperfusion injury may be considered, which can induce severe coronary microvascular injury by intraluminal microvascular obstruction and extravascular compression of the microcirculation.²⁹

Figure 2 summarises the underlying mechanisms of myocardial infarction in infants and children. Secondary haemodynamic derangement caused by initial ischaemic insults inevitably increases myocardial oxygen demand, which could be another target for medical management. It is crucial to delineate the underlying pathophysiology of myocardial infarction as the treatment is highly depending upon the mechanism of myocardial ischaemia. The onset and degree of ischaemia may play a role in determining the presenting symptoms.²¹ In chronic ischaemia, collateral vessel formation is enhanced,³⁰ which has been shown to be protective against sudden cardiac death.^{31–33}

Limitations

Our study is limited by certain factors. First, there is a selection bias in our case series as not all myocardial infarction victims were able to survive to reach a tertiary medical centre such as ours. More severe and lethal cases might not have been included in the study. Second, the description of clinical manifestations on the medical record was not always consistent; some records lack important objective information of true clinical pictures. Third, the definition of myocardial infarction may not be stringent when discussing myocardial infarction due to coronary microangiopathy as some advanced myocarditis may mimic myocardial infarction, which we excluded from the study. However, we included one patient with post-transplant microvasculopathy that may not have been distinct from myocardial inflammation secondary to acute myocarditis.

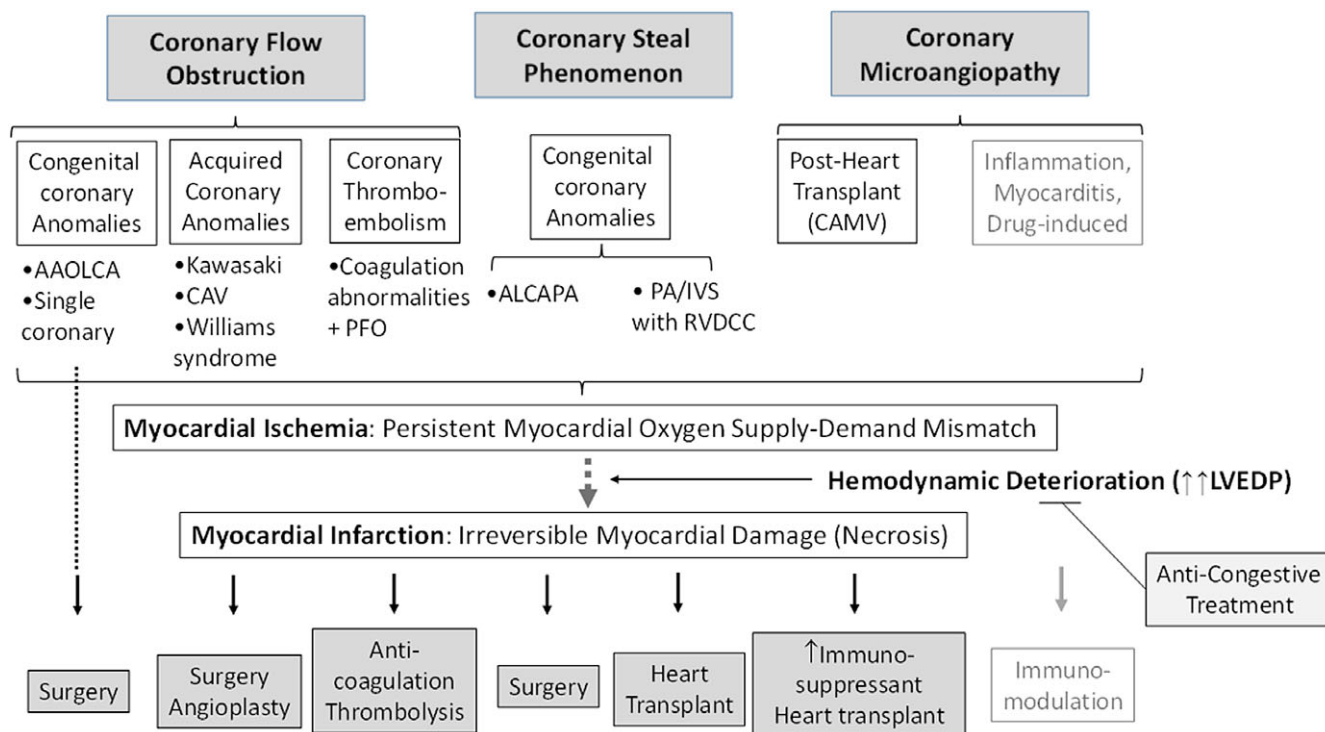


Figure 2. Overview of causes of acute myocardial infarction in infants and children. Three major mechanisms were proposed: coronary flow obstruction, coronary steal phenomenon, and coronary microangiopathy. These three mechanisms can coexist in certain situations. Ventricular fibrillations and sudden cardiac arrest are also a product of myocardial ischaemia. AAOLCA = anomalous aortic origin of left coronary artery, ALCAPA = anomalous left coronary artery from pulmonary artery, CAMV = cardiac allograft microvasculopathy, CAV = cardiac allograft vasculopathy, LVEDP = left ventricular end-diastolic pressure, PA/IVS = pulmonary atresia/intact ventricular septum, PFO = patent foramen ovale, RVDCC = right ventricle-dependent coronary circulation.

This is a controversial area that requires further investigation. Last, this is an observational case series in a single institution with a small cohort. To better understand the true nature of myocardial infarction in paediatrics, a multi-centre study is warranted.

Conclusions

In conclusion, myocardial infarction is a rare disease in children but more frequently occurred in infants who presented with non-specific but progressive signs of clinical deterioration. Other than known presence of underlying CHD (e.g. pulmonary atresia/intact ventricular septum with right ventricle-dependent coronary circulation), it is frequently challenging to make a correct diagnosis promptly. In young patients, even extensively impaired myocardium demonstrated full recovery in some cases, whereas transplant-free survival was very low in cases of late identification, especially with underlying coronary anomalies. High suspicion of myocardial infarction is essential when symptomatic patients present with an electrocardiographic abnormality and elevation of serum troponin to avoid late diagnosis.

Acknowledgements. None.

Financial support. None.

Competing interests. None.

Ethical standard. The authors assert that all procedures contributing to this work comply with the ethical standards of the relevant national guidelines on human experimentation (United States Department of Health and Human Services) and with the Helsinki Declaration of 1975, as revised in 2008.

References

1. Thygesen K, Alpert JS, Jaffe AS et al. Fourth universal definition of myocardial infarction, 2018. *J Am Coll Cardiol* 2018; 72: 2231–2264.
2. Bamber AR, Pryce J, Cook A, Ashworth M, Sebire NJ. Myocardial necrosis and infarction in newborns and infants. *Forensic Sci Med Pathol* 2013; 9: 521–527.
3. Berry CL. Myocardial ischaemia in infancy and childhood. *J Clin Pathol* 1967; 20: 38–41.
4. Anand SS, Islam S, Rosengren A et al. Risk factors for myocardial infarction in women and men: insights from the INTERHEART study. *Eur Heart J* 2008; 29: 932–940.
5. Bor I. Myocardial infarction and ischaemic heart disease in infants and children. Analysis of 29 cases and review of the literature. *Arch Dis Child* 1969; 44: 268–281.
6. Celermajer DS, Sholler GF, Howman-Giles R, Celermajer JM. Myocardial infarction in childhood: clinical analysis of 17 cases and medium term follow up of survivors. *Br Heart J* 1991; 65: 332–336.
7. Towbin JA, Bricker JT, Garson A Jr. Electrocardiographic criteria for diagnosis of acute myocardial infarction in childhood. *Am J Cardiol* 1992; 69: 1545–1548.
8. Nakana H, Saito A, Ueda K, Nojima K. Clinical characteristics of myocardial infarction following kawasaki disease: report of 11 cases. *J Pediatr* 1986; 108: 198–203.
9. Frommelt P, Lopez L, Dimas Wet al. Recommendations for multimodality assessment of congenital coronary anomalies: a guide from the American Society of Echocardiography: developed in collaboration with the Society for Cardiovascular Angiography and Interventions, Japanese Society of Echocardiography, and Society for Cardiovascular Magnetic Resonance. *J Am Soc Echocardiogr* 2020; 33: 259–294.
10. Dodge-Khatami A, Mavroudis C, Backer CL. Anomalous origin of the left coronary artery from the pulmonary artery: collective review of surgical therapy. *Ann Thorac Surg* 2002; 74: 946–955.

11. del Nido PJ, Duncan BW, Mayer JE Jr, Wessel DL, LaPierre RA, Jonas RA. Left ventricular assist device improves survival in children with left ventricular dysfunction after repair of anomalous origin of the left coronary artery from the pulmonary artery. *Ann Thorac Surg* 1999; 67: 169–172.
12. Matoq AA, Tsuda T. Effective myocardial perfusion and concomitant haemodynamic status determine the clinical diversity of anomalous left coronary artery from the pulmonary artery. *Cardiol Young* 2020; 30: 362–368.
13. Imamura M, Dossey AM, Jaquiss RDB. Reoperation and mechanical circulatory support after repair of anomalous origin of the left coronary artery from the pulmonary artery: a twenty-year experience. *Ann Thorac Surg* 2011; 92: 167–172.
14. Turner Turek JW II, Jaggars J, Herlong JR, Lawson DS, Lodge AJ. Anomalous aortic origin of a coronary artery: preoperative diagnosis and surgical planning. *World J Pediatr Congenit Heart Surg* 2011; 2: 340–345.
15. Mainwaring RD, Reddy VM, Reinhartz O, Petrossian E, Punnett R, Hanley FL. Surgical repair of anomalous aortic origin of a coronary artery. *Eur J Cardiothorac Surg* 2014; 46: 20–26.
16. McNeal-Davidson A, Fournier A, Scuccimarri R et al. The fate and observed management of giant coronary artery aneurysms secondary to Kawasaki disease in the Province of Quebec: the complete series since 1976. *Pediatr Cardiol* 2013; 34: 170–178.
17. Tsuda E, Hamaoka K, Suzuki H et al. A survey of the 3-decade outcome for patients with giant aneurysms caused by Kawasaki disease. *Am Heart J* 2014; 167: 249–258.
18. Hopp L, Gilboa N, Kurland G, Weichler N, Orchard TJ. Acute myocardial infarction in a young boy with nephrotic syndrome: a case report and review of the literature. *Pediatr Nephrol* 1994; 8: 290–294.
19. Kosaka Y, Sakamoto T, Takigiku K, Yasukochi S, Harada Y. Coronary thromboembolism in hypoplastic left heart syndrome. *Ann Thorac Surg* 2013; 95: 718.
20. Setzer E, Ermocilla R, Tonkin I, John E, Sansa M, Cassady G. Papillary muscle necrosis in a neonatal autopsy population: incidence and associated clinical manifestations. *J Pediatr* 1980; 96: 289–294.
21. Atkinson JB. Pathobiology of sudden death: coronary causes. *Cardiovasc Pathol* 1994; 3: 105–115.
22. Tanaka K, Masuda J, Imamura T et al. A nation-wide study of atherosclerosis in infants, children and young adults in Japan. *Atherosclerosis* 1988; 72: 143–156.
23. Stary HC. Evolution and progression of atherosclerotic lesions in coronary arteries of children and young adults. *Arteriosclerosis* 1989; 9: 119–132.
24. Tsuda T, Patel G. Coronary microvascular dysfunction in childhood: an emerging pathological entity and its clinical implications. *Am Heart J Plus* 2024; 42: 100392.
25. Molossi S, Martínez-Bravo LE, Mery CM. Anomalous aortic origin of a coronary artery. *Methodist DeBakey Cardiovasc J* 2019; 15: 111–121.
26. Law W, DiBardino DJ, Raviendren R, Devaney E, Davis C. Anomalous aortic origin of the left coronary artery: in-hospital cardiac arrest and death despite bed rest. *World J Pediatr Congenit Heart Surg* 2014; 5: 580–582.
27. Khalighi K, Sharma M, Toor A, Toor RS, Costacurta G. Anomalous left main coronary artery arising from the right sinus of valsalva in a young man presenting with recurrent syncope and myocardial infarction. *Case Rep Cardiol* 2018; 2018: 1–4.
28. Duke C, Rosenthal E, Simpson JM. Myocardial infarction in infancy caused by compression of an anomalous left coronary artery arising from the right coronary artery. *Cardiol Young* 2004; 14: 654–657.
29. Sezer M, van Royen N, Umman B et al. Coronary microvascular injury in reperfused acute myocardial infarction: a view from an integrative perspective. *J Am Heart Assoc* 2018; 7: e009949.
30. Zimarino M, D'Andreamatteo M, Waksman R, Epstein SE, De Caterina R. The dynamics of the coronary collateral circulation. *Nat Rev Cardiol* 2014; 11: 191–197.
31. Schaper W. Collateral anatomy and blood flow: its potential role in sudden coronary death. *Ann N Y Acad Sci* 1982; 382: 69–75.
32. Lavine KJ, Sintek M, Novak E et al. Coronary collaterals predict improved survival and allograft function in patients with coronary allograft vasculopathy. *Circ Heart Fail* 2013; 6: 773–784.
33. Traupe T, Gloekler S, de Marchi SF, Werner GS, Seiler C. Assessment of the human coronary collateral circulation. *Circulation* 2010; 122: 1210–1220.