



Letter to the Editor: New Observation

A Novel Presenilin-1 Mutation (Leu226Val) In Early Onset Alzheimer's Disease With Parkinsonism

Alessandro Zilioli¹ , Francesco Misirocchi¹ , Beatrice Pancaldi¹, Carlotta Mutti^{1,2}, Chiara Ganazzoli³, Irene Florindo¹ and Marco Spallazzi¹

¹Department of Medicine and Surgery, Unit of Neurology, University Hospital of Parma, Parma, Italy, ²Department of Medicine and Surgery, Sleep Disorders Center, University Hospital of Parma, Parma, Italy and ³Neuroradiology Unit, University Hospital of Parma, Parma, Italy

Keywords: early-onset Alzheimer's disease; PSEN1; NGS; parkinsonism

Dear Sirs,

Alzheimer's disease (AD) represents the most common cause of dementia, accounting for 60% of cognitive disorders worldwide. AD is defined as early-onset (EOAD) when the clinical onset occurs before the age of 65, and it presents a higher frequency of familial clustering than the late-onset subtype.

To date, variants in three causative genes such as presenilin 1 (PSEN-1), presenilin 2 (PSEN-2), and amyloid precursor protein (APP) have been identified as responsible for familial AD with Mendelian inheritance and almost complete penetrance. Overall, they account for less than 1% of all AD cases, although the prevalence peaks at about 20% in familiar EOAD.¹

PSEN-1, encoding a subunit of γ -secretase with a proteolytic activity on APP, is the main cause of monogenic AD. Thanks to the increasing availability of next-generation sequencing (NGS) panels, over 300 mutations in PSEN-1 have been discovered [<https://www.alzforum.org/mutations/psen-1>, accessed in March 2023], leading to a broad phenotypic variability.

In 2020, a 50-years-old right-handed Caucasian man presented with a progressive and insidious onset of episodic memory deficits, reduced working ability, and neglect in his self-care.

One year later, bradykinesia and left-hand action tremor appeared. Due to these symptoms, he underwent a DAT-SCAN (123I-Ioflupane) SPECT assessment, which revealed reduced uptake in the right basal ganglia. Consequently, he initiated dopaminergic treatment with L-dopa, titrated up to 200 mg/day, resulting in slight efficacy on the bradykinesia features.

Two years later, the patient was admitted to our Neurology unit due to the persistence of extrapyramidal and cognitive features. His personal medical history was unremarkable and the patient did not suffer from any comorbidities. However, the assessment of his familial medical history revealed that his father had been diagnosed with cognitive impairment at about 50 years of age, and his brother had committed suicide at the age of 50.

The initial clinical examination revealed a slight action tremor in the left hand, ipsilateral bradykinesia, along with plastic hypertonia and impaired visuospatial abilities. No anosmia, REM sleep behavior disorder, and dysautonomic signs were observed.

The cognitive and functional decline was defined by a Montreal Cognitive Assessment score of 17/30, indicating prominent deficits in memory and visuospatial functions. Three months later, the patient underwent a complete neuropsychological assessment, which is shown in Table 1.

During hospitalization, brain MRI showed a posterior gradient of atrophy characterized by a lateralized involvement of the right precuneus and occipital-parietal areas, with corresponding periventricular white-matter FLAIR alterations. In addition, the "Swallow Tail" sign was not recognized in the susceptibility-weighted angiography sequence, and low perfusion values, assessed by arterial spin labeling, were found in the right temporal-parietal-occipital lobe (Figure 1). CSF biomarkers defined an A + T-N-profile, showing low levels of beta-amyloid 1–42 (=155pg/ml, n.v. > 450 pg/ml) and beta-amyloid 1–42/1–40 ratio (=0.08, n.v. > 0.1) while tau and p-tau were normal.

Considering the young onset of the cognitive impairment and familial aggregation, we performed an NGS panel focused on dementia, targeting DCTN1, MAPT, GRN, PSEN-1, PSEN-2, and TARDBP genes.

It identified a heterozygous "missense" mutation (c.676 C > G) p. Leu226Val at codon 226 in the PSEN-1 gene.

This mutation is considered likely pathogenetic according to the American College of Medical Genetics and Genomics guidelines and Guerreiro's algorithm,² leading us to the diagnosis of monogenic EOAD.

The codon 226 is located in the transmembrane domain 5 (TM5) of the PSEN-1 gene and appears to play a critical role in the formation of the γ -secretase catalytic site, as well as in neurotransmission and synaptic mechanisms. Motor impairment, especially parkinsonism, is quite common in patients with TM5 mutations.

Since the finding of the earliest pathogenetic variants in the PSEN-1 gene, it was clear that EOAD may occur with remarkable phenotypic variability that also encompasses the EOAD of motor signs, going from spastic paraparesis to myoclonus and parkinsonism.³

The Leu226Val mutation was not previously reported in the literature, so we investigated a potential link with other codon 226 mutations (Table 2).

Corresponding author: A. Zilioli; Email: alessandro.zilioli@unipr.it

Cite this article: Zilioli A, Misirocchi F, Pancaldi B, Mutti C, Ganazzoli C, Florindo I, and Spallazzi M. (2024) A Novel Presenilin-1 Mutation (Leu226Val) In Early Onset Alzheimer's Disease With Parkinsonism. *The Canadian Journal of Neurological Sciences* 51: 703–706, <https://doi.org/10.1017/cjn.2023.285>

Table 1: Neuropsychological assessment. R.S: raw scores; C.S: correct scores

Global cognitive screening	r.s.	c.s	cutoff	Results
Montreal Cognitive Assessment (Santangelo et al '15)	13/30	12.52	15.51	Impaired
Language				
Phonemic Fluencies (Carlesimo et al., '96)	12	7.55	17.35	Impaired
Semantic Fluencies (Zarino '15)	26	25	23.59	Normal
SAND denomination (Catricalà '17)	14	14	14	Normal
Visuo spatial functions				
Rey's figure copy (Caffarra'02)	16	15.5	28.88	Impaired
Long term memory				
Rey's figure recall (Caffarra '02)	2.5	0.13	9.47	Impaired
Free and Cued Selective Reminding Test (Frasson, '11)				
IFR	20	16.83	19.60	Impaired
ITR	32	–	35	Impaired
DFR	7	6.24	6.32	Impaired
Short-term memory				
Digit span forward (Monaco '13)	3	2.79	4.26	Impaired
Digit span backward (Monaco '13)	<3	–	2.65	Impaired
Attentive and executive functions				
Frontal Assessment Battery (Apollonio '05)	9	8.2	13.5	Impaired
Stroop Test (Caffarra '02)				
Time	45.5	46	36.91	Impaired
Errors	3	2	4.23	Normal
Multiple Features Cancellation Test (Marra '12)				
Time	151	157.74	135.73	Impaired
Errors	4	4.3	2.77	Impaired
Accuracy	0.735	–	0.869	Impaired

Table 2: Currently known pathological variations at position 226 of the PSEN-1 gene

	<i>Our case index</i>	<i>Coleman et al. (2004)⁶</i>	<i>Zekanowski et al. (2006)</i>	<i>Gomez-Tortosa et al (2010)</i>	<i>Bagyinszky et al. (2016)</i>	<i>Bartasaghi et al. (2019)⁷</i>	<i>Bin Jiao et al. (2021)⁸</i>
<i>Mutations</i>	L226V	L226R	L226F	L226F	L226F	L226F	L226R
<i>Family history</i>	Father affected by dementia at 50 years. Brother suicided at 50 years	Mother affected by dementia died in 50s. Maternal aunt affected by dementia died at 50 years	Mother affected by dementia at age 33 and dead at the age of 44	Father affected by dementia at 36 years	Negative	Unknown	Positive (not further specified)
<i>Age at diagnosis</i>	52 years	49 years	33 years	33 years	37 years	36 years	44 years
<i>Cognitive and psychiatric symptoms</i>	Depression, Episodic memory, and visuospatial deficits	Encephalopathy (with the comorbid of childhood delay and various substances abuse)	Frontotemporal dementia-like syndrome with short-term memory deterioration	Depression, non-fluent speech, significant deficits in verbal memory, executive and visuo-construction abilities.	Anxiety and paranoid ideation. Severe deficits in multiple cognitive domains, mainly in memory functioning	Behavioral changes and cognitive impairment	Memory decline and behavior change

(Continued)

Table 2: (Continued)

	<i>Our case index</i>	<i>Coleman et al. (2004)⁶</i>	<i>Zekanowski et al. (2006)</i>	<i>Gomez-Tortosa et al (2010)</i>	<i>Bagyinszky et al. (2016)</i>	<i>Bartasaghi et al. (2019)⁷</i>	<i>Bin Jiao et al. (2021)⁸</i>
<i>Motor and other symptoms</i>	Bradykinesia and left-hand action tremor	Not reported	Slight parkinsonian symptoms	Lateralized intentional tremor with extrapyramidal signs	Not reported	Seizures	Not reported
<i>Neuroimaging features</i>	Posterior gradient of atrophy, cortico-subcortical white-matter FLAIR alterations, hypoperfusion in right temporal-parietal-occipital lobe, atrophy in CA3 and BA36.	Not reported	Symmetrical atrophy of frontal lobes with not involvement of limbic regions, frontal hypoperfusion on SPECT	Diffuse cortical atrophy, mainly biparietal. Normal SPECT with FP-CIT.	Bilateral hippocampal and parietal cortical atrophySevere biparietal hypometabolism on FDG-PET	Biparietal hippocampal and parietal atrophy. Hypometabolism of precuneus, posterior cingulate, temporoparietal and frontal areas on FDG-PET	Not reported
<i>Age death</i>	–	51 years	38 years	–	44 years	38 years	Not reported

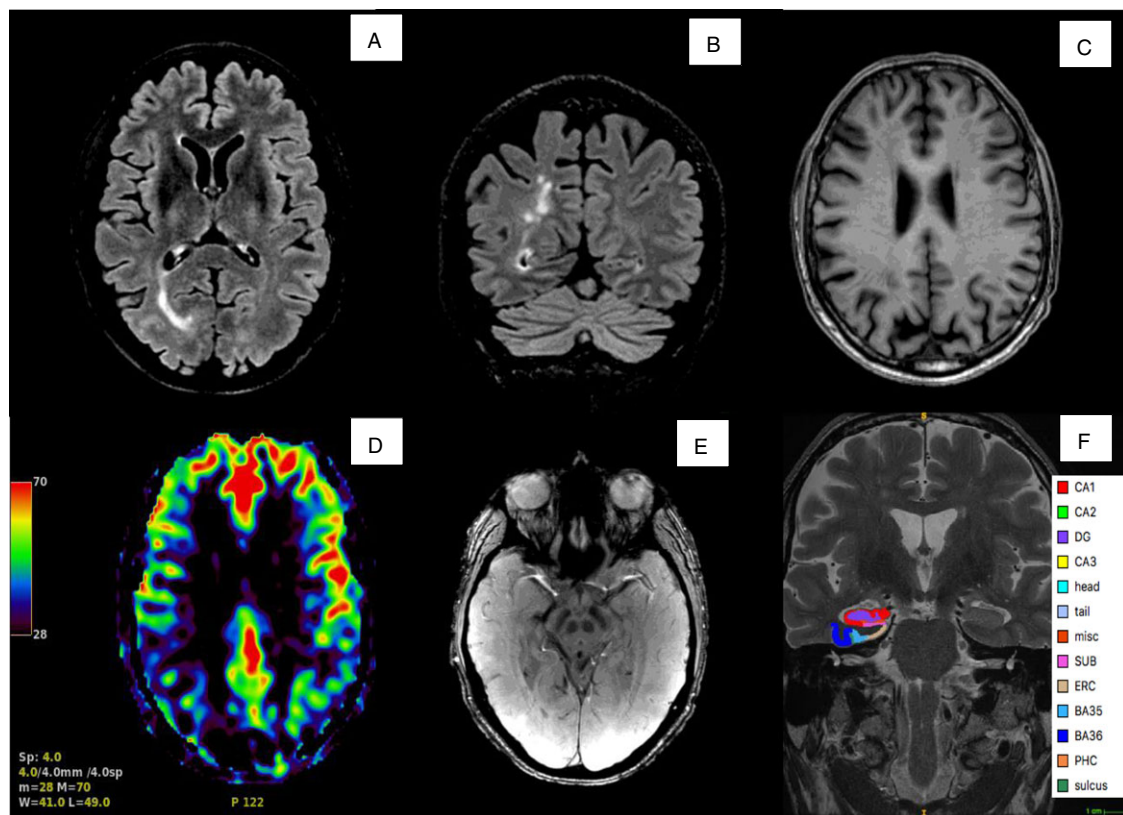


Figure 1: On top, axial (a) and coronal (b) fluid attenuated inversion recovery (FLAIR) showing occipital-parietal white-matter cortico-subcortical suspicious for microgliosis, and axial T1-weighted MRI (c) with correspondent atrophy in the precuneus regions. On bottom, ASL perfusion analysis (d) displaying an hypoperfusion of parietal lobe more prominent in the right hemisphere, susceptibility-weighted angiography (SWAN) sequence (E) with the bilateral lack of the “swallow tail” sign, and coronal high-resolution T2 with hippocampal subfields analysis [F] through ASHS (Automatic segmentation of hippocampal subfields) algorithm). CA = cornu ammonis; DG = dentate gyrus; SUB = subiculum; ERC = entorhinal cortex; BA35/36 = Brodmann area 35/36 (which together form the perirhinal cortex); CS = collateral sulcus.

One point of similarity among cases involving codon 226 is the presence of early behavioral and psychiatric symptoms along with extrapyramidal signs. Notably, the latter is the most frequent motor feature, described in over 40% of cases (3 out of 7), which surpasses the reported prevalence of extrapyramidal signs in PSEN-1 (14%).³

Compared to PSEN-2, PSEN-1 mutations are known to determine a more significant interaction with alpha-synuclein, to be more associated with Lewy body pathology, and to cause rarefaction in the substantia nigra (SN) and deposition of cotton wall plaques in basal ganglia.⁴ Our report confirmed these aspects, showing the absence of the swallow tail sign, which has been

reported to correlate with dopaminergic neuron depletion in the SN and to have good diagnostic accuracy for Parkinson's disease and dementia with Lewy bodies.

Another peculiar neuroimaging finding was the (right) lateralization of the neurodegeneration, considering that the notable asymmetry of atrophic and WM alterations is not typical in AD (Figure 1).

Furthermore, the occipital-parietal WM cortico-subcortical FLAIR alterations, both in shape and distribution, could potentially signify microgliosis due to genetic etiology rather than white-matter changes associated with chronic small vessel disease. This interpretation is supported by the absence of comorbidities, which are typically seen in the context of sporadic AD.

Despite the increasing interest in hippocampal subfield volume, accurate assessments in monogenic-defined EOAD are still lacking. Therefore, we conducted volumetric analysis of hippocampal subfields and the medial temporal cortex using a high-resolution coronal T2 sequence (Figure 1).

The results of our assessment showed low volumetric values in the Cornu Ammonis 3 (CA3) and Brodmann area 36 (BA36) compared to a group of controls and MCI patients, with almost comparable values in the other hippocampal subregions and overall hippocampus.⁵

In conclusion, we highlighted the hallmarks of a novel mutation in PSEN-1 gene causing EOAD.

We acknowledge that the primary limitation of the study is its status as a single case report. However, with the support of a literature review focused on various codon 226 mutations, we have confirmed the significant phenotypic and pathological heterogeneity associated with EOAD caused by PSEN-1 variations.

A careful clinical-neuroradiological assessment of young adults and middle-aged populations complaining of memory deficits and behavioral disturbances, especially when combined with the occurrence of extrapyramidal and motor symptoms, could play a key role in leading the clinicians to perform a proper NGS analysis and obtain a correct diagnosis, in the expectation of upcoming disease-modifying and gene therapy studies.

Acknowledgments. None.

Statements and declarations. The patient gave a written informed consent to the use of his personal data for research and teaching purposes.

Funding. None.

Competing interests. AZ, FM, BP, CM, CG, IF, and MS report no disclosures relevant to the article.

Statement of authorship. Conceptualization AZ, FM, BP, CG, and MS; Writing – Original Draft Preparation AZ, FM, BP, MS, and IF; Writing – Review & Editing AZ, FM, CM, IF, and MS.

References

1. Bartoletti-Stella A, Tarozzi M, Mengozzi G, et al. Dementia-related genetic variants in an Italian population of early-onset Alzheimer's disease. *Front Aging Neurosci.* 2022;14:969817. DOI: [10.3389/fnagi.2022.969817](https://doi.org/10.3389/fnagi.2022.969817).
2. Guerreiro RJ, Baquero M, Blesa R, et al. Genetic screening of Alzheimer's disease genes in Iberian and African samples yields novel mutations in presenilins and APP. *Neurobiol Aging.* 2010; 31:725–31. DOI: [10.1016/j.neurobiolaging.2008.06.012](https://doi.org/10.1016/j.neurobiolaging.2008.06.012).
3. Ryan NS, Nicholas JM, Weston PSJ, et al. Clinical phenotype and genetic associations in autosomal dominant familial Alzheimer's disease: a case series. *Lancet Neurol.* 2016;15:1326–35. DOI: [10.1016/S1474-4422\(16\)30193-4](https://doi.org/10.1016/S1474-4422(16)30193-4).
4. Takao M, Ghetti B, Hayakawa I, et al. A novel mutation (G217D) in the Presenilin 1 gene (PSEN1) in a Japanese family: presenile dementia and parkinsonism are associated with cotton wool plaques in the cortex and striatum. *Acta Neuropathol.* 2002;104:155–70. DOI: [10.1007/s00401-002-0536-6](https://doi.org/10.1007/s00401-002-0536-6).
5. Xie L, Shinohara RT, Ittyerah R, et al. Automated multi-atlas segmentation of hippocampal and extrahippocampal subregions in Alzheimer's disease at 3T and 7T: what atlas composition works best? *J. Alzheimers Dis.* 2018;63:217–25. DOI: [10.3233/JAD-170932](https://doi.org/10.3233/JAD-170932).
6. Coleman P, Kurlan R, Crook R, Werner J, Hardy J. A new presenilin Alzheimer's disease case confirms the helical alignment of pathogenic mutations in transmembrane domain 5. *Neurosci Lett.* 2004;364:139–40. DOI: [10.1016/j.neulet.2004.04.030](https://doi.org/10.1016/j.neulet.2004.04.030).
7. Bartesaghi F, Rosci CE, Rassiga C, et al. Psychiatric disorders in Alzheimer disease with the presenilin-1 L226F mutation. *Cogn Behav Neurol.* 2020;33:278–82. DOI: [10.1097/WNN.0000000000000249](https://doi.org/10.1097/WNN.0000000000000249).
8. Jiao B, Liu H, Guo L, et al. The role of genetics in neurodegenerative dementia: a large cohort study in South China. *NPJ. Genom Med.* 2021;6:69. DOI: [10.1038/s41525-021-00235-3](https://doi.org/10.1038/s41525-021-00235-3).