



## Neuroimaging Highlight

# Spontaneous Cervical Internal Carotid Artery Vasospasm (SCICAV): It's Unique

Taylor Dool<sup>1</sup> , Gagan Dhall<sup>2</sup>, Clare Enriquez<sup>2</sup>, Aviraj Deshmukh<sup>3</sup>, Howard Meng<sup>4</sup>, Leodante da Costa<sup>2</sup>  and Christine Hawkes<sup>2</sup>

<sup>1</sup>Department of Physiology and Pharmacology, Schulich School of Medicine & Dentistry, London, ON, Canada, <sup>2</sup>Division of Neurosurgery, Sunnybrook Health Sciences Center, Toronto, ON, Canada, <sup>3</sup>Department of Neurology, Health Sciences North South Tower, Sudbury, ON, Canada and <sup>4</sup>Department of Anesthesia, Sunnybrook Health Sciences Center, Toronto, ON, Canada

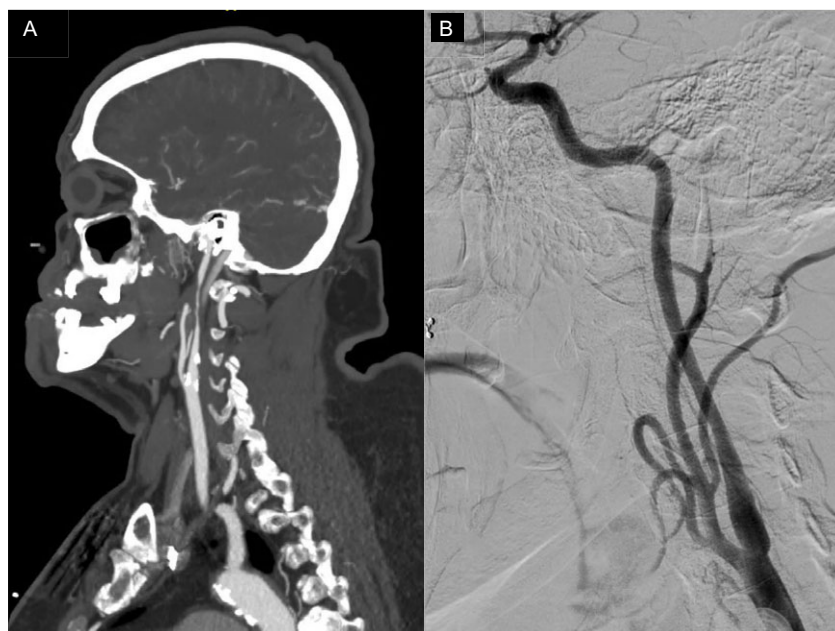
**Keywords:** Carotid artery stenosis; carotid artery stent; spontaneous cervical internal carotid artery vasospasm; stroke; stellate ganglion blockade

(Received 29 September 2024; date of acceptance 13 October 2024)

A 66-year-old male with a previous history of multiple vascular risk factors, including previous strokes in 2022 and 2023, hypertension, dyslipidemia, obesity, prior smoking, coronary artery disease, left bundle branch block, and dilated ischaemic cardiomyopathy with implantable cardioverter-defibrillator, was admitted with recurring episodes of right monocular vision loss accompanied by transient right-sided facial and arm weakness.

In May 2022, the patient presented to a different stroke centre with aphasia and right-sided weakness. Imaging revealed an acute left capsular stroke with 60% stenosis of the left internal

carotid artery (ICA). He was managed medically and recovered significantly, with residual mild right-sided weakness. Six months later, he presented again with blurred vision in the left eye and right leg weakness. CT angiography (CTA) demonstrated worsening left ICA stenosis, and given his cardiac history, carotid artery stenting was recommended (Figure 1a). During the procedure, selective left ICA angiography showed no stenosis (Figure 1b). There was a suspicion of a carotid web with contrast stasis. Based on these findings and the clinical history of left hemispheric strokes, the left ICA was stented.

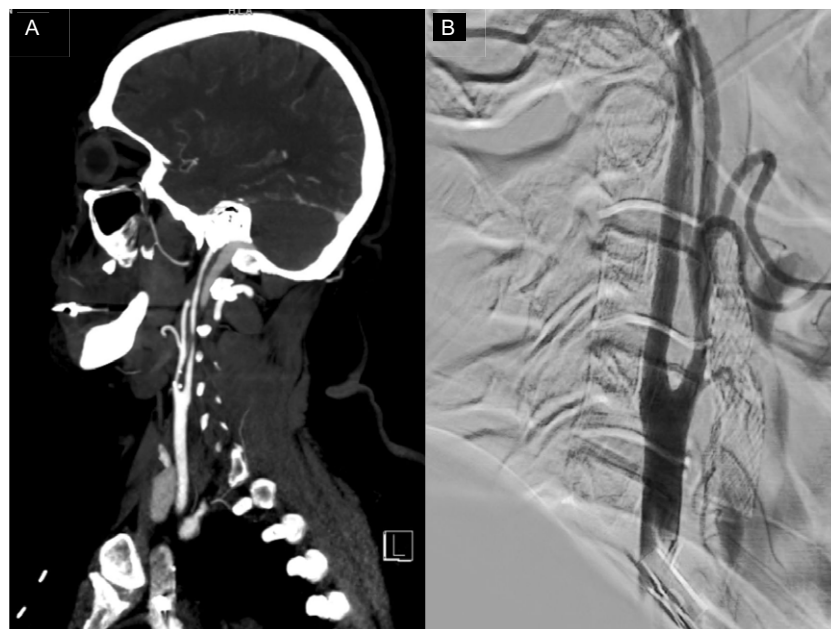

**Figure 1.** Imaging of patient presenting with blurring of vision in the left eye and weakness of the right leg in January 2023. (a) Cranial CT/CT angiogram showing worsening left internal carotid artery (ICA) stenosis. (b) Cerebral angiogram showing resolution of the left ICA stenosis.

**Corresponding author:** Taylor Dool; Email: [dooltaylor@gmail.com](mailto:dooltaylor@gmail.com)

**Cite this article:** Dool T, Dhall G, Enriquez C, Deshmukh A, Meng H, da Costa L, and Hawkes C. Spontaneous Cervical Internal Carotid Artery Vasospasm (SCICAV): It's Unique. *The Canadian Journal of Neurological Sciences*, <https://doi.org/10.1017/cjn.2024.330>

© The Author(s), 2024. Published by Cambridge University Press on behalf of Canadian Neurological Sciences Federation.



**Figure 2.** Imaging of patient presenting with recurring episodes of right monocular vision loss accompanied by transient right-sided facial and arm weakness in July 2024. (a) Cranial CT/CT angiogram showing severe (greater than 70%) stenosis of the right mid-cervical internal carotid artery (ICA). (b) Cerebral angiogram showing resolution of the right mid-cervical ICA stenosis.

During the most recent admission, the CTA demonstrated patency of the left ICA stent with severe (greater than 70%) stenosis of the right mid-cervical ICA (Figure 2a). Due to the unclear clinical history and the right facial droop, a diagnostic angiogram was performed. Surprisingly, again, the right ICA runs showed no stenosis (Figure 2b). No further endovascular intervention was performed.

Based on the previous documentation of reversible left ICA stenosis and evidence of the resolution of right ICA stenosis on the angiogram, this led to the diagnosis of Spontaneous Cervical Internal Carotid Artery Vasospasm (SCICAV). This is a rare cause of stroke, and the underlying pathophysiology remains poorly understood but may relate to vascular endothelial dysfunction or genetic factors influencing smooth muscle autoregulation.<sup>1</sup> It has been associated with trauma, mechanical manipulation, vasoconstricting medications and migraines.<sup>2</sup> There is no standardised treatment algorithm for this condition. A review of reported clinical cases of idiopathic extracranial ICA vasospasm found that oral medications (such as anticoagulants and calcium channel blockers [CCBs]) and endovascular interventions have been used, with all patients showing improvement and no recurrences after carotid artery stenting.<sup>3</sup> Stellate ganglion blockade is another potential treatment, particularly in medically challenging patients, but the long-term efficacy of these treatments remains uncertain.

In our patient, we did not identify any obvious trigger or reversible factor. Due to the patient's significant cardiac dysfunction, CCBs were not administered. As an alternative, he underwent a trial of ultrasound-guided right-sided stellate ganglion blockade with 5 ml of 1% ropivacaine. There is limited

literature on the efficacy of various medications, their optimal doses and the effects of stellate ganglion blockade on extracranial and cranial vasculature, but some evidence suggests it can reverse submandibular ICA spasms.<sup>4</sup> The patient's transient right hemiparesis has since resolved, and no additional symptoms have been reported since his discharge from the hospital. This case highlights a rare and dynamic condition that should be recognised by treating physicians.

**Acknowledgements.** None.

**Author contributions.** TD, GD, CE and CH contributed to the concept and design of the manuscript. All authors contributed to drafting and revising the manuscript, as well as providing final approval.

**Funding statement.** None.

**Competing interests.** None.

## References

1. Graham E, Orjuela K, Poisson S, Biller J. Treatment challenges in idiopathic extracranial ICA vasospasm case report and review of the literature. *eNeurologicalSci*. 2021;22:100304. DOI: [10.1016/j.ensci.2020.100304](https://doi.org/10.1016/j.ensci.2020.100304).
2. Huisa BN, Roy G. Spontaneous cervical internal carotid artery vasospasm. *Neurol Clin Pract*. 2014;4:461–4. DOI: [10.1212/CPJ.0000000000000067](https://doi.org/10.1212/CPJ.0000000000000067).
3. Kaneko M, Tateoka T, Kanemaru K, et al. Recurring cervical internal carotid artery vasospasm elicited by head rotation: illustrative case. *J Neurosurg Case Lessons*. 2022;4:CASE22254. DOI: [10.3171/CASE22254](https://doi.org/10.3171/CASE22254).
4. Yokoyama H, Yoneda M, Abe M, et al. Internal carotid artery vasospasm syndrome: demonstration by neuroimaging. *J Neurol Neurosurg Psychiatry*. 2006;77:888–9. DOI: [10.1136/jnnp.2005.079798](https://doi.org/10.1136/jnnp.2005.079798).