



## Neuroimaging Highlight

# Parasellar Extraventricular Neurocytoma: Magnetic Resonance and Angiographic Findings

Na Yeon Yoon<sup>1</sup>, Jung Youn Kim<sup>1</sup> , Hye Jeong Choi<sup>1</sup> , Jinhyung Heo<sup>2</sup> and Sang Heum Kim<sup>1</sup>

<sup>1</sup>Department of Radiology, CHA Bundang Medical Center, CHA University, Seongnam, Republic of Korea and <sup>2</sup>Department of Pathology, CHA Bundang Medical Center, CHA University, Seongnam, Republic of Korea

**Keywords:** Brain tumors; interventional neuroradiology; magnetic resonance imaging; neuroradiology

(Received 13 February 2023; final revisions submitted 20 July 2023; date of acceptance 4 August 2023; First Published online 14 August 2023)

A 40-year-old female, with no history of medical disease, consulted the outpatient clinic of the Neurosurgery Department for a headache lasting 1 year. No neurologic deficits were identified, and the visual field examination using Humphrey visual field analyzer yielded normal results. Laboratory examinations, including the pituitary hormone test, showed no abnormalities.

Enhanced brain magnetic resonance imaging revealed a well-defined lobulated extra-axial mass, measuring approximately  $6.1 \times 4.5 \times 3.4$  cm, in the sellar, suprasellar, and parasellar regions, with a slight hypointense signal on T1-weighted imaging and a hyperintense signal on T2-weighted imaging. Moderate homogeneous enhancement was observed on enhanced T1-weighted imaging (Fig. 1a–c). Although the tumor involved the sellar fossa, the pituitary gland was differentiated from the mass with different signal intensities on sagittal images (Fig. 1d). It exhibited insinuated growth around the structures, extending into the bilateral cavernous sinuses, Meckel's cave, retroclival area, and sphenoid sinus with sellar floor erosion (Fig. 1e–f). The distal segments of the bilateral internal carotid arteries (ICAs) were encased by the tumor, and optic chiasm compression was noted (Fig. 1b). The left side of the pons was mildly compressed by the mass; however, perilesional edema was not identified in the brain parenchyma.

Carotid angiography showed mild to moderate tumor staining primarily from the bilateral meningohypophyseal trunks with progressive contrast accumulation (Fig. 1g–n). On angiography, significant luminal stenosis was not observed even though the distal segments of the bilateral ICAs were encased by the tumor.

Therefore, the primary impression was a meningioma. To reduce the risk of tumoral bleeding during surgery, preoperative tumor embolization was performed using glue material after superselection of the left meningohypophyseal trunk. This resulted in an infarction of a significant portion of the left parasellar region of the tumor (Fig. 1o). Intraoperatively, tumor adhesions to the

surrounding tissues and profuse bleeding were noted. Hence, partial resection was performed. Histopathological assessment of the tumor confirmed as an extraventricular neurocytoma (EVN) (Fig. 2).

EVNs are rare tumors occurring outside the ventricular system with an incidence of 0.25%–0.5% among all brain neoplasms.<sup>1</sup> They share similar histologic features with central neurocytomas. However, EVN has a distinct morphology, cellularity, proliferation rate, and prognosis with a more diverse spectrum.<sup>2</sup> EVN was initially classified as a distinct tumor entity in the 2007 World Health Organization (WHO) tumor classification system and is categorized as a WHO grade 2 tumor.<sup>3,4</sup> EVN develops anywhere in the brain, predominantly in the cerebral hemisphere. Its clinical presentation varies depending on the tumor location.<sup>5</sup> An EVN arising from the parasellar region is rare and difficult to diagnose because its imaging findings overlap with that of other tumors, including a pituitary adenoma or meningioma, which commonly occur in this region.<sup>6,7</sup> Several studies have described imaging findings of parasellar EVNs. However, this is the first report on the angiographic findings of the tumor.

The treatment of choice for parasellar EVNs is maximal surgical resection. However, this may be complicated depending on the location, and radiotherapy should be considered to address residual lesions to improve the prognosis.<sup>6,8</sup>

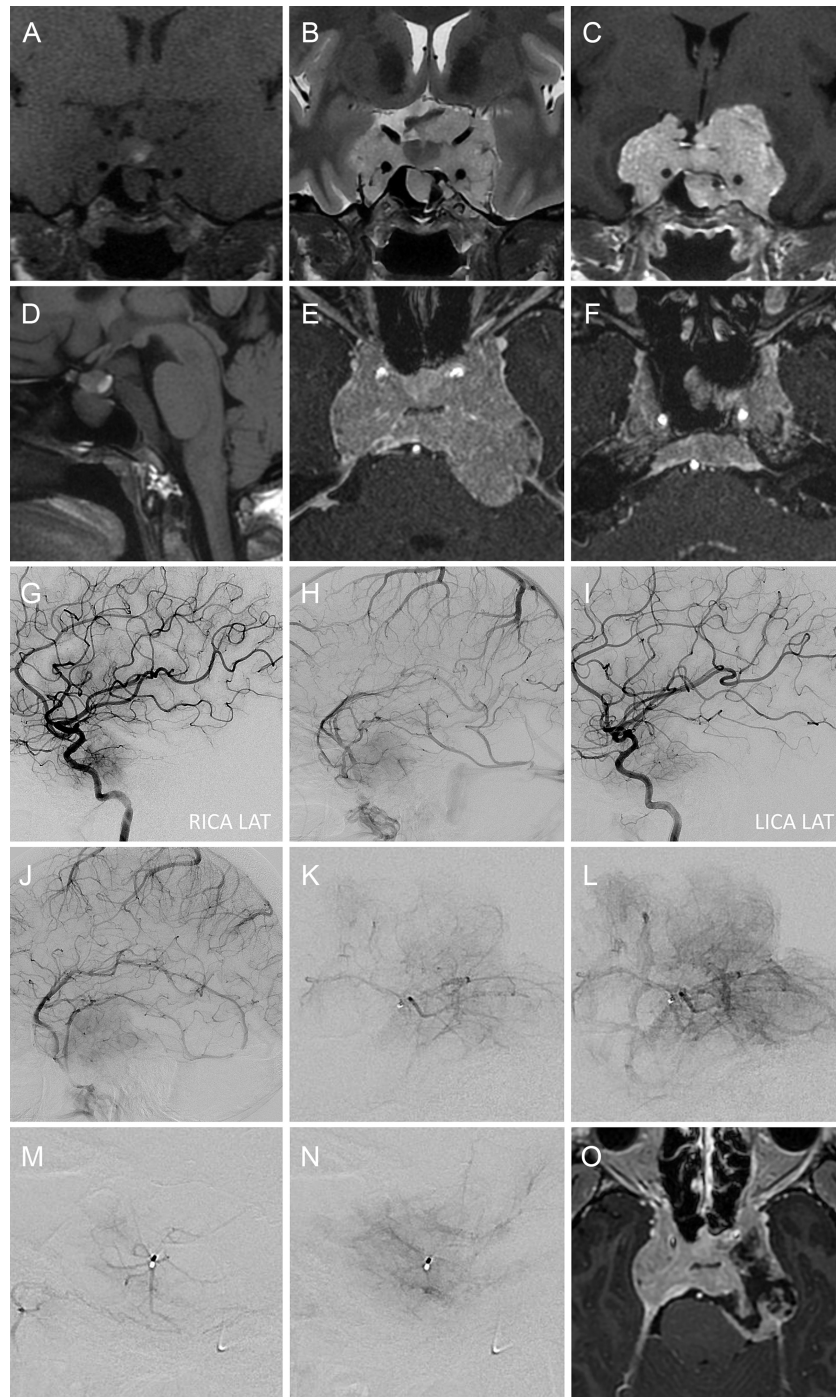
**Statement of authorship.** NYY organized the images and wrote the original manuscript. JYK conceptualized the study, performed the literature review, reviewed the radiologic findings, and revised the manuscript for intellectual content. HJC reviewed the radiologic findings and revised the manuscript for intellectual content. JH reviewed the histopathologic examinations. SHK reviewed the radiologic findings. All authors have read and approved the final manuscript.

**Funding.** There were no grants/funding from any public, private, or commercial interests.

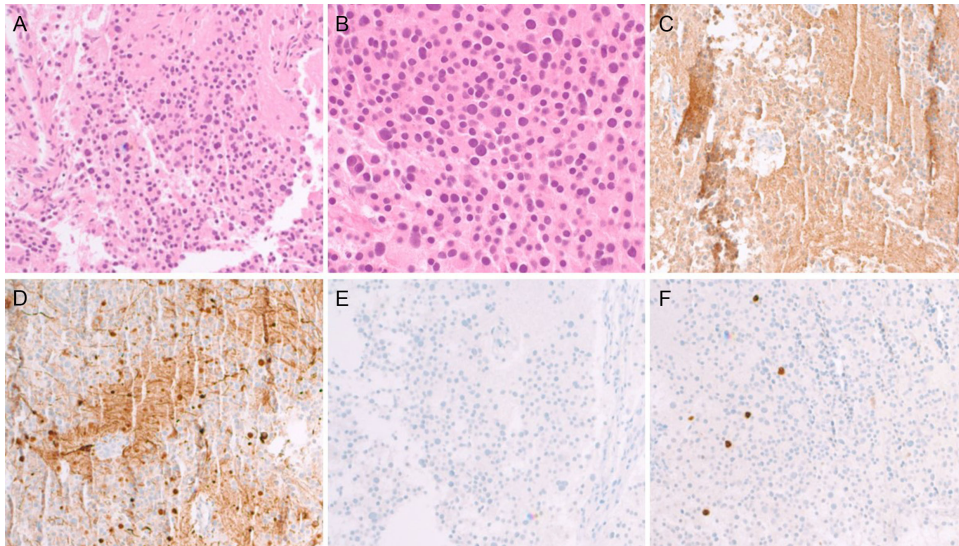
**Corresponding author:** J. Y. Kim; Email [cleopiece@gmail.com](mailto:cleopiece@gmail.com)

**Cite this article:** Yoon NY, Kim JY, Choi HJ, Heo J, and Kim SH. (2024) Parasellar Extraventricular Neurocytoma: Magnetic Resonance and Angiographic Findings. *The Canadian Journal of Neurological Sciences* 51: 566–568, <https://doi.org/10.1017/cjn.2023.272>

© The Author(s), 2023. Published by Cambridge University Press on behalf of Canadian Neurological Sciences Federation.



**Figure 1:** Radiologic findings of extraventricular neurocytoma in the sellar, suprasellar and parasellar region. Magnetic resonance imaging demonstrates a well-circumscribed extra-axial mass, exhibiting a hypointense signal intensity (SI) on coronal T1-weighted imaging (**a**) and, hyperintense SI on T2-weighted imaging (**b**) with moderate homogenous enhancement on enhanced T1-weighted imaging (**c**). Compression and upward displacement of the optic chiasm and encasement of the distal segments of the bilateral internal carotid arteries are noted. The normal pituitary gland is distinguished from the tumor on sagittal T1-weighted imaging (**d**). Enhanced axial T1-weighted imaging (**e, f**) shows the mass, extending bilaterally into cavernous sinuses, Meckel's cave, retroclival area, and sphenoid sinus. Based on carotid angiography (**g-n**), the tumor vascularity is primarily supplied by the bilateral meningohypophyseal trunks, with tumor staining observed in the venous phases of bilateral internal carotid angiography (**h, j**). Notably, angiography following supraselection of the left meningohypophyseal trunk reveals mild to moderate progressive contrast accumulation (**k, l**). Additionally, minor tumor supply from the left inferolateral trunk is also noted (**m, n**). Following tumor embolization at the left meningohypophyseal trunk using glue material, infarction of the left side of the tumor is noted on contrast-enhanced axial T1-weighted imaging (**o**).



**Figure 2:** Histopathological examination reveals uniform tumor cells with round nuclei and scanty cytoplasm on hematoxylin-eosin staining; magnification  $\times 100$  (a) and  $\times 400$  (b). The tumor cells are diffusely and strongly positive for synaptophysin (c) and neurofilament (d), but negative for GFAP (e). Ki-67 staining (f) yielded a proliferation index of 2%; magnification  $\times 100$ .

**Competing interests.** None.

## References

- Schmidt MH, Gottfried ON, von Koch CS, Chang SM, McDermott MW. Central neurocytoma: a review. *J Neurooncol.* 2004;66:377–84.
- Brat DJ, Scheithauer BW, Eberhart CG, Burger PC. Extraventricular neurocytomas: pathologic features and clinical outcome. *Am J Surg Pathol.* 2001;25:1252–60.
- Louis DN, Ohgaki H, Wiestler OD, et al. The 2007 WHO classification of tumours of the central nervous system. *Acta Neuropathol.* 2007;114:97–109.
- Louis DN, Perry A, Wesseling P, et al. The 2021 WHO classification of tumors of the central nervous system: a summary. *Neuro Oncol.* 2021;23:1231–51.
- Romano N, Federici M, Castaldi A. Imaging of extraventricular neurocytoma: a systematic literature review. *Radiol Med.* 2020;125:961–70.
- Zhang L, Fu W, Zheng L, et al. A clinicopathological and molecular analysis of sellar/Suprasellar neurocytoma mimicking pituitary adenoma. *Front Endocrinol (Lausanne).* 2022;13:861540.
- Zhao X, Li M, Zhang G, et al. Extraventricular neurocytoma at the sellar region: report of 8 cases and literature review. *J Clin Neurosci.* 2022;99:379–86.
- Kawaji H, Saito O, Amano S, Kasahara M, Baba S, Namba H. Extraventricular neurocytoma of the sellar region with spinal dissemination. *Brain Tumor Pathol.* 2014;31:51–6.