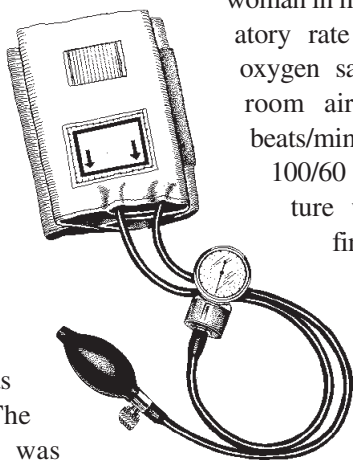


Abdominal pain in pregnancy

Kirk Hollohan, MD

A 21-year-old female presented to the emergency department (ED) with lower abdominal pain, which had started suddenly during urination. She noted at the time of onset that she felt hot and pre-syncopal. In the ED, she described the pain as “a stitch” and rated its severity as 6/10. It was constant in nature, with no aggravating or relieving factors. Her menstrual flow had started a day earlier and her last menstrual period was one month before. The past medical history was unremarkable, she took no prescription medication, and had no



allergies. She smoked “crack” cocaine regularly but had not done so on the day of presentation. She denied intravenous drug use and admitted to 12 drinks per week.

Examination revealed an alert woman in minimal distress. Respiratory rate was 16 breaths/min, oxygen saturation was 99% on room air, heart rate was 64 beats/min, blood pressure was 100/60 mm Hg, and temperature was 37.1°C. Physical findings included bilateral lower quadrant tenderness with mild guarding but no rebound. A speculum exam showed a small amount of bright red blood in the posterior vaginal vault, and bimanual exam revealed no adnexal masses but moderate bilateral tenderness, with the left more tender than the right. The uterus was slightly

enlarged but nontender.

The bedside urine pregnancy test was positive, and quantitative serum beta-hCG was subsequently reported at 600 mIU/ml. Transabdominal and endovaginal sonography revealed an empty uterus, unremarkable ovaries and follicles, no adnexal masses and no free fluid.

The patient was discharged with instructions to return in 2 days for a repeat beta-hCG measurement. She was also told to return immediately if her pain or bleeding worsened. The most likely diagnosis in this case is:

1. Ectopic pregnancy
2. Corpus luteum cyst with concealed hemorrhage
3. Intermittent ovarian torsion
4. Threatened abortion

Department of Emergency Medicine,
St. Paul's Hospital, Vancouver, BC

For the Answer to this Challenge,