

# Ocular and Cerebral Ischemic Mechanisms in Disease of the Internal Carotid Artery

R. T. Ross and Ian M. Morrow

**ABSTRACT:** Stenosis of the internal carotid artery reduces the flow velocity in the ophthalmic artery. Lowered velocity permits increased red cell aggregation and decreased red cell deformability which increases viscosity.

Contrary to the theory of remotely originating emboli, this is an alternate hypothesis regarding transient attacks of ocular and cerebral ischemia.

The ophthalmic artery circulation time was measured in two groups of patients. The circulation time was defined as the interval between the appearance of contrast media in the siphon of the internal carotid artery and in the ocular choroid. The measurement was made on 151 angiograms of 108 subjects. These vessels were normal. An additional 76 patients had 108 angiograms which showed various amounts of internal carotid artery stenosis. These 76 patients had transient ischemic attacks; retinal, cerebral, or both.

There is a significant difference in the ophthalmic artery circulation time in the two groups. The slowing in the ophthalmic artery is related to the degree of internal carotid artery narrowing.

The circulation time in a cerebral branch of the internal carotid was not measured. It is presumed that stenosis of the internal carotid artery would have the same effect on a cerebral artery as on the ophthalmic artery.

**RÉSUMÉ:** La sténose de la carotide interne réduit le flot dans l'artère ophtalmique, avec comme conséquence une aggrégation des érythrocytes et une augmentation de la viscosité. Ce mécanisme alternatif peut donc être proposé pour les attaques transitoires d'ischémie oculaire ou cérébrale.

Nous avons mesuré le temps de circulation dans l'artère ophtalmique chez deux groupes de patients. Ce temps est l'intervalle entre l'apparition du produit de contraste dans le siphon carotidien et dans la choroïde oculaire. Ce calcul fut fait sur 151 angiogrammes chez 108 sujets. Ces vaisseaux étaient normaux. 76 autres patients (108 angiogrammes) montraient un niveau variable de sténose de la carotide interne. Ces 76 sujets avaient des attaques ischémiques transitoires: cérébrales ou rétinienne, ou les deux.

Il existe une différence significative dans le temps de circulation de l'artère ophtalmique entre les 3 groupes étudiés. Le ralentissement est proportionnel au degré de sténose. Nous croyons que de telles sténoses auraient le même effet sur la circulation dans la branche cérébrale de la carotide interne.

*Can. J. Neurol. Sci. 1984; 11:262-268*

Decreased circulation time of blood through an artery changes the physical properties of the blood. When the flow velocity is reduced there is increased aggregation and decreased deformability of red cells which raises viscosity. Increased viscosity is often characterized by intermittent ischemic symptoms (Dintenfass, 1981; Thomas, 1982).

Because delayed passage of contrast media in an artery can be recognized and measured angiographically, this method was used to study the circulation time in the ophthalmic arteries in patients with normal carotid arteries, and in patients with vari-

ous amounts of carotid stenosis who had transient cerebral hemisphere attacks (TIAs) and/or transient monocular blindness (TMB). The ophthalmic artery lends itself to this type of study. It is possible to time the beginning of its opacification in an angiogram film and one can assign the end of its opacification as the appearance of the ocular choroid or choroidal "blush" (Figure 1). For this study the interval between the appearance of the contrast media at the carotid siphon and the choroid blush was defined as the ophthalmic artery circulation time. The carotid artery circulation time was defined as the interval

From the Section of Neurology, Departments of Medicine and Radiology, University of Manitoba and the Health Sciences Centre, Winnipeg, Canada

Received September 7, 1983. Accepted December 21, 1984

Reprint Requests to: R.T. Ross, GF543-700 William Avenue, Winnipeg, Manitoba R3E 0Z3 Canada

between the appearance of contrast media at the bifurcation of the common carotid artery and the appearance of contrast in any part of the carotid siphon.

### METHODS

To obtain normal ophthalmic artery circulation time, we reviewed 151 carotid angiograms of 108 patients (67 males). The ages ranged from 10 to 74 years and the only basis for selection was that the films were normal in all phases, and were of sufficient quality to be subtractable. The angiograms were all performed and interpreted by the same person (IMM). None of the 108 patients had TIAs, TMB, or fixed cerebral deficits due to vascular disease. Their angiograms had been done for a variety of reasons including seizure disorder, head injury, brain tumor suspect, elucidation of an uncertain computerized tomographic scan finding, suspect cerebral aneurysm, and others.

We also reviewed 108 abnormal angiograms from 76 patients (49 males). These had 25% or more stenosis at the origin of the internal carotid artery and the patients had a history of more than one transient ischemic attack; ocular, cerebral, or both.

A TIA was defined as an episode of weakness, numbness, speech or vision loss, within the territory of the internal carotid artery. The duration was less than 24 hours (and was usually less than 24 minutes) and recovery was complete. Transient monocular blindness was defined as an episode of loss or diminution of all vision in one eye of sudden onset, rapid progression (seconds), and short duration (minutes) with complete recovery and a normal eye examination.

Patients with transient ischemic attacks and normal angiograms, and patients with asymptomatic stenosis of the internal carotid artery were excluded. Patients with TIAs arising from posterior fossa structures were excluded.

These 76 patients were assessed by history, physical examination, consultation with the appropriate doctors, and the usual investigative procedures respecting heart and hematological disease, eye disease, epilepsy, migraine, and intracranial mass lesions. Every one of the 76 patients was thought to be having TIAs or TMBs as defined above.

The angiograms were performed under local anaesthetic in all patients over the age of 18 years. Under this age general anaesthetic was used. A 6.0 French 100 cm Gensini catheter was introduced into a femoral artery. The tip was placed in the mid ascending aorta and 45 ml of 76% Renografin (R) were injected. This revealed the origins and general state of the brachio-cephalic vessels. The selective carotid studies were then done with a 6.5 French 100 cm polyethylene catheter with an appropriate tip configuration. The tip was placed 2-3 cm into the common carotid and 8 ml of 60% Renografin (R) were injected. A Viamonte Hobbs (R) injector at a constant pressure was used. The timing and sequence of the x-ray film run was the same for every patient. The film exposures were made at three per second for the first three seconds and at two per second for the next three seconds. The first film was exposed at one-third of a second after the start of the injection and the last film (number 16) at six seconds after the start of the injection. One of the authors (IMM) then selected the first film which revealed the contrast at the carotid bifurcation, the carotid siphon, and the first and last film to show the choroid.

The other author (RTR) computed the time in seconds for the transit of contrast in the internal carotid artery and the ophthalmic

artery. This was done without knowing the patients' age, symptoms, or the interpretation of the angiogram.

### RESULTS

#### Normal Angiograms

All of the 151 normal angiograms revealed that the ophthalmic artery arose from the internal carotid. It has been reported as arising from the middle meningeal in 1 to 2% of cases (Handel et al., 1973; Hayreh and Dass, 1962). As all the injections in the cases presented here were made into the common carotid artery, the ophthalmic would fill regardless of its origin, but the sequence and timing of ophthalmic opacification would differ between an internal carotid origin as opposed to a middle meningeal origin.

All of the 151 normal angiograms revealed an ocular choroidal blush similar to other studies (Handel et al., 1973). Failure to visualize the choroid almost always indicates disease.

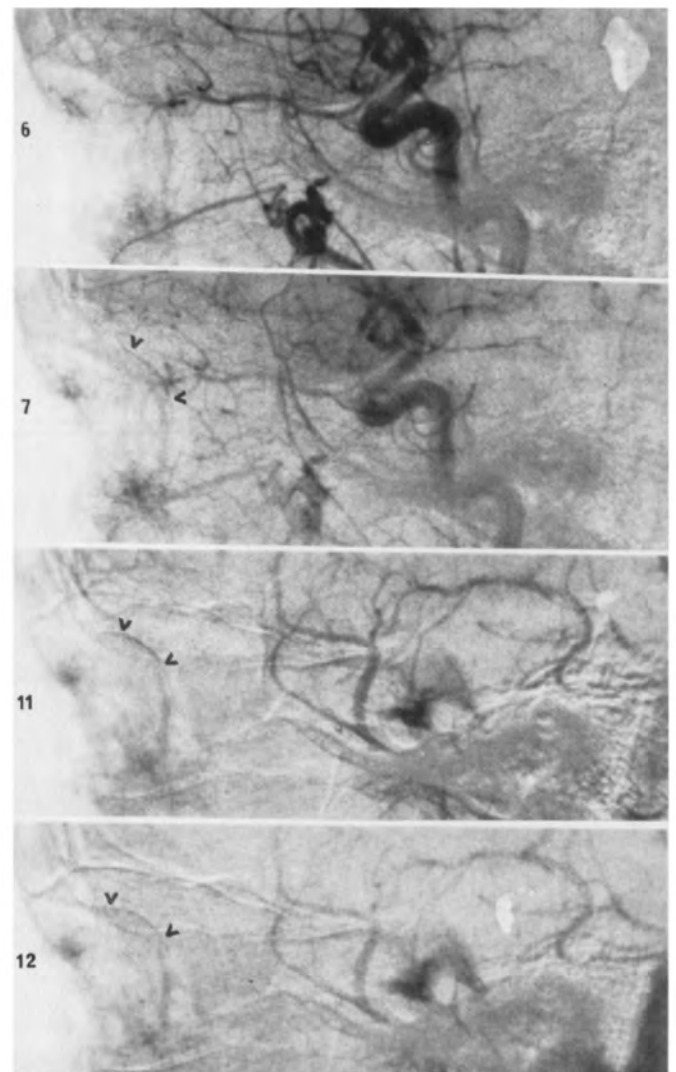


Figure 1 — Composite carotid angiogram films showing opacification of the ophthalmic artery (in 6) and the ocular choroid blush (in 7, 11 and 12) indicated by the arrow heads. The numbers on the left indicate the serial order of the films.

In order to verify the consistency and reproducibility of the method, the left and right ophthalmic artery circulation times were compared in subjects who had bilateral studies performed at the same examination time. Although 108 subjects had 151 angiographic studies, only 35 subjects had bilateral studies, one immediately following the other. There was no significant difference between the right and left ophthalmic artery circulation time in these 35 subjects (Figure 2).

Of the total of 151 angiographic studies, 73 were right carotid and 78 were left. Comparison of this whole group, right versus left ophthalmic artery circulation times, also revealed no significant difference (Student's t-test). Therefore the method was reliable and the results were consistent and reproducible.

Cerebral circulation time is known to increase with age (Moller and Wolschendorf, 1978; Green and Arana, 1948; Raney and Raney, 1950). It has been measured by these authors as the interval between the appearance of injected contrast material at the lower knee of the carotid siphon and the confluence of venous sinuses. The studies were done in normal subjects ranging from 6 to 69 years of age. The rate of contrast injection, cine film exposure and quotient densiometer detection of contrast at the start and end of the transit were the same in all subjects. The increase in cerebral circulation time is linear and the coefficient amounts to about 1% per year. The ophthalmic artery circulation time in normal subjects is similarly influenced by age as shown in Figure 3. This figure shows the positive relationship between age and ophthalmic artery circulation time in normal subjects 40 years of age and older. Because the purpose of the study was to compare ophthalmic artery circulation time between subjects with normal and diseased carotid arteries and as there were no subjects with diseased arteries under the age of 40 years, this selected group of normals was chosen for the comparison.

In the normal angiograms the duration of the choroidal blush had a mean of 2.38 seconds (S.D.  $\pm$  0.65). There was almost no correlation between the duration of the blush and the subject's age ( $r = -0.417$ ) and only a slightly greater correlation between the duration of the choroidal blush and the ophthalmic artery circulation time ( $r = -0.523$ ). There was little correlation between the carotid artery circulation time and 1) the subject's age ( $r = 0.364$ ), 2) the ophthalmic artery circulation time ( $r = 0.196$ ), or 3) the duration of the choroidal blush ( $r = -0.208$ ) (Pearson correlation index).

**Abnormal Angiograms**

All of the 108 angiograms in this group showed the ophthalmic artery arising from the internal carotid artery. All of these patients (76) had symptoms of transient ischemia; cerebral, ocular, or both, and all had diseased carotid arteries. Eighteen patients had transient monocular blindness only. The degree of carotid artery obstruction was classified by one of us (IMM) as: occluded, 75% or greater stenosed, about 50% stenosed, or about 25% stenosed. The numbers in each category are shown in Table 1. All of the group with 25% stenosis of the internal carotid revealed an ophthalmic artery and a choroidal blush. Of the group with 50% carotid stenosis all showed an ophthalmic artery and all but one showed a choroidal blush. Of the group with 75% carotid stenosis (N = 44) only 33 opacified their ophthalmic arteries and only 31 showed a choroidal blush.

Of the group with occlusion of the internal carotid artery no carotid artery or ophthalmic artery circulation time measurements were possible. Eighty percent of these patients filled their ophthalmic arteries in a retrograde direction and 30% of the whole group showed a faint choroidal blush. None of these patients' findings were used in this paper.

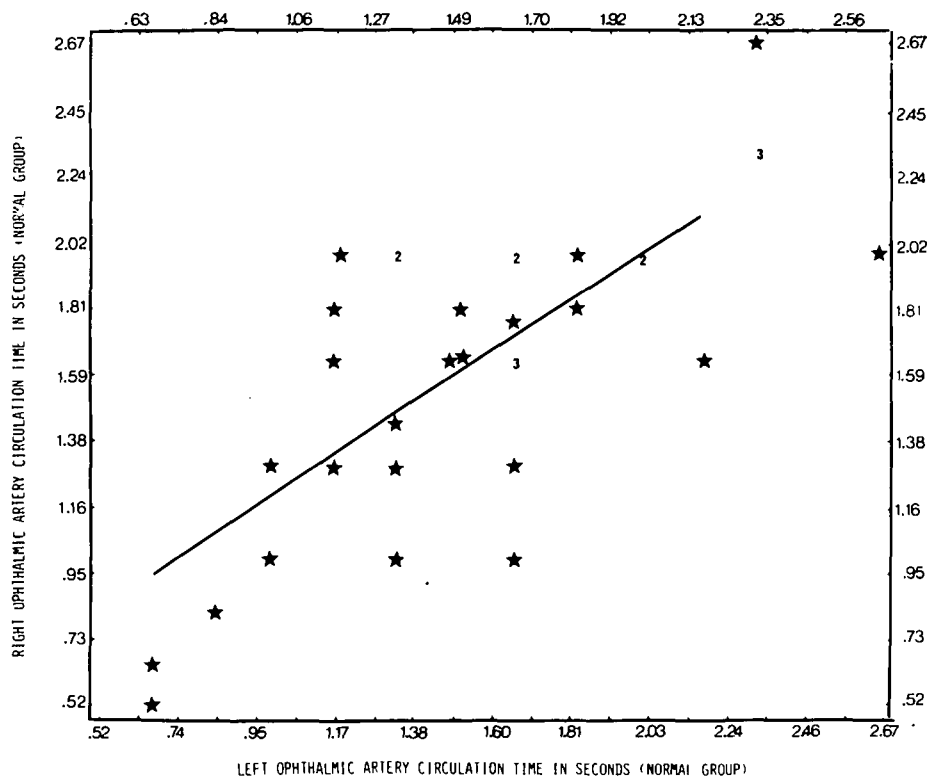


Figure 2 — Right and left ophthalmic artery circulation times compared in 35 normal subjects who had bilateral carotid angiographic studies one immediately following the other. The left ophthalmic artery mean time was 1.57 seconds (S.D.  $\pm$  .51) and the right was 1.66 seconds (S.D.  $\pm$  .51). The difference was not significant (paired Student's t-test). The numerals represent that number of patients with the same circulation times.

Analysis of the two groups (TIA with or without TMB versus TMB alone) revealed no significant difference in the degree of internal carotid artery stenosis or the frequency of occlusion. It is also apparent from Table 1 that more patients in both groups had major disease (i.e. occlusion or 75% greater stenosis) of their internal carotid arteries rather than minor disease. Thus, 53 out of 80 angiograms revealed one or other of these diseases in the TIA and TMB group while 20 out of 28 angiograms in the TMB only group showed the major changes.

### Overall Comparisons

All of the patients with abnormal angiograms were compared to an age related group with normal angiograms with respect to carotid and ophthalmic artery circulation times. The results are shown in Table 2. The circulation times in the ophthalmic and carotid arteries were significantly different in the diseased group than the normals. In both arterial systems the p value was less than .001. Furthermore, when a one way analysis of variance was applied to the carotid artery circulation times in the normal group and to the groups having 25%, 50%, and 75% stenosis of the internal carotid, there was a significant increase in time in relation to the degree of stenosis (Figure 4). The degree of significance between the carotid circulation time of the normal subjects and the patients with 75% stenosis showed a p value of less than .0001 (Student-Newman-Keuls procedure).

When the ophthalmic artery circulation times were compared by the same procedure there was also a gradient of increasing times showing a relationship to the degree of internal carotid artery stenosis (Figure 4). There was a significant difference in the ophthalmic artery circulation time between the normal group and the 50% and 75% internal carotid artery stenosis groups. There was also a significant difference in the time between the 25% stenosed and 75% stenosed group (all p values were less than .05).

The distribution of ages within the various groups was analyzed as a covariant. Age was not a significant factor in the different circulation times related to the various degrees of carotid artery stenosis.

The data on the patients with transient monocular blindness only (N = 18) was compared to that on the patients with cerebral TIAs with and without TMB (N = 58).

There was no significant difference in the proportion of patients in either group with 25%, 50%, 75% stenosis, or occlusion of the internal carotid artery. The mean ophthalmic artery circulation time for the group of patients with TMB only and 75% stenosis of the internal carotid was slightly longer than, but not significantly different than, the larger group of patients with 75% stenosis (chi-square analysis).

The ophthalmic artery circulation time was related only to the amount of internal carotid artery stenosis, not to whether symptoms were ocular or cerebral.

Table 1: Degree of carotid artery narrowing and type of symptom

	TIA* with/without TMB†	TMB† ONLY
INTERNAL CAROTID ARTERY		
OCCLUDED	22	7
75% STENOSED	31	13
50% STENOSED	18	7
25% STENOSED	9	1
NUMBER OF ANGIOGRAMS	80	28

\*TIA = cerebral hemisphere transient ischemic attack  
†TMB = transient monocular blindness

Table 2: Comparison of age and circulation time in carotid and ophthalmic arteries between all the normal subjects (over age 40) and all the patients with diseased carotid arteries

VARIABLE		NUMBER	MEAN	STANDARD DEVIATION	STANDARD ERROR
AGE	NORMAL	87	58.5		
	ABNORMAL†	65	59.9		
CAROTID ARTERY CIRCULATION TIME (SECS)	NORMAL	87	.37 <sup>§</sup>	.128	.021
	ABNORMAL†	65	.584 <sup>§</sup>	.326	.037
OPHTHALMIC ARTERY CIRCULATION TIME (SECS)	NORMAL	87	1.69 <sup>§</sup>	.500	.081
	ABNORMAL†	65	2.46 <sup>§</sup>	.830	.095

† - abnormal includes patients with hemisphere and retinal ischemic attacks and with retinal attacks only.

§ - p < .001

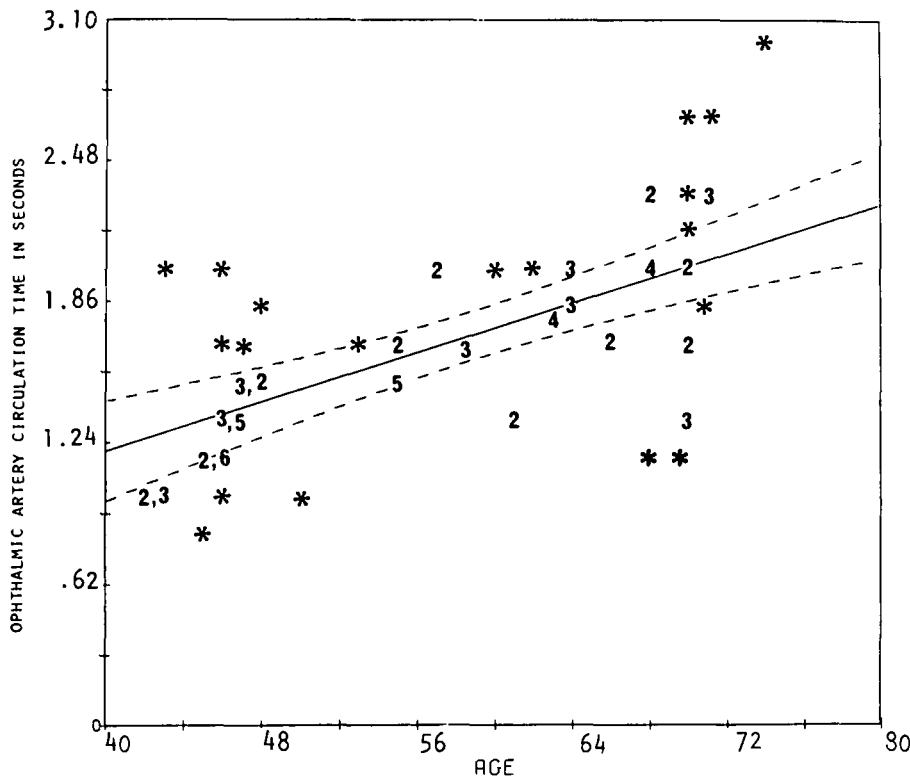
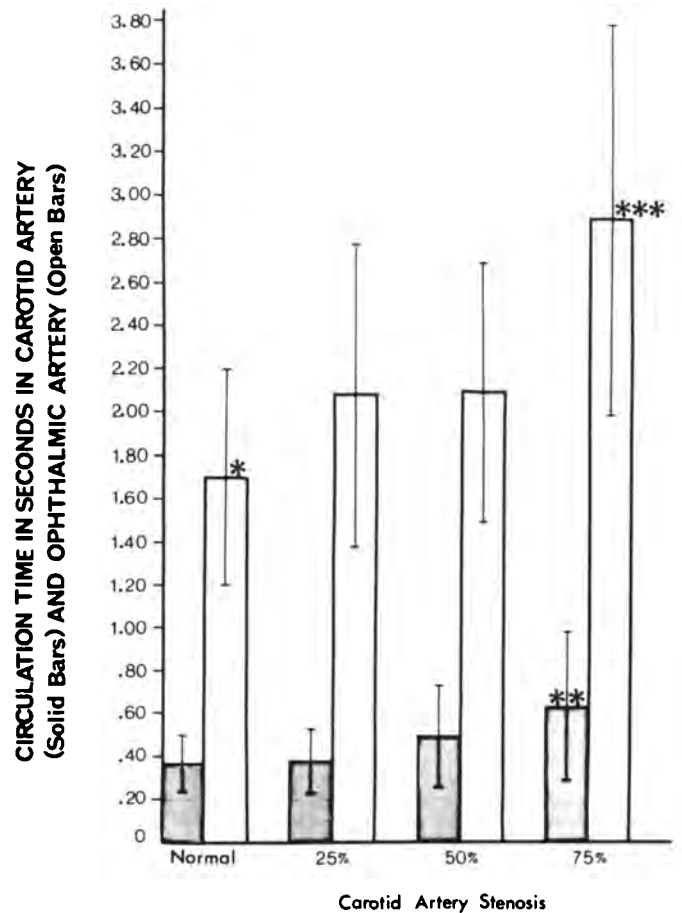


Figure 3 — Ophthalmic artery circulation time at various ages in the normal group. Broken lines represent 95% confidence limits. The numerals represent that number of patients with the same circulation time ( $r = .5945$ ).

Figure 4 — Carotid artery circulation time (solid bars) and ophthalmic artery circulation time (open bars) and standard deviation with normal and various amounts of carotid artery stenosis.



\* SIGNIFICANTLY DIFFERENT FROM THE 50% STENOSED,  $p < .05$   
 \*\* SIGNIFICANTLY DIFFERENT FROM NORMAL,  $p < .0001$   
 \*\*\* SIGNIFICANTLY DIFFERENT FROM NORMAL AND 25% STENOSED,  $p < .05$



## DISCUSSION

The purpose of this investigation was to examine the circulation time in the ophthalmic artery in patients with stenosis of the internal carotid artery who had a history of transient ocular and/or cerebral ischemia. The ophthalmic artery was chosen because its circulation time is measurable and it is part of a vascular system subject to recognizable intermittent ischemia. The circulation time in the middle or anterior cerebral arteries could not be estimated with the same reliability.

Some or most TIAs and TMB are thought to be embolic in nature (Moore and Hall, 1970; Millikan, 1965; Duncan et al., 1976). No doubt emboli account for many TIAs, but where they come from and what produces them is not always obvious. There are objections to this theory. Some patients have exclusively ocular ischemic episodes (Fisher, 1959; Ross, 1977). Eighteen out of 76 in the present series had ocular symptoms only. The ophthalmic artery (average diameter 1.2 mm) (Clay and Vignaud, 1971) leaves the carotid artery (average diameter 7.5 mm) at an angle of 90 degrees or less. The volume of blood in the carotid is many times greater than in the ophthalmic. Logic would suggest that hemisphere attacks should be much more common than ocular attacks if the proposed mechanism of emboli originating at the bifurcation of a stenotic common carotid artery is correct. It seems unlikely that a patient would have exclusively ocular episodes unless the pathogenesis of the blindness was located within the ophthalmic artery distal to its origin.

In addition, TIAs are often stereotyped in quality and area in an individual patient. This implies that blood flow is compromised in the same vessel and only this vessel in each episode. Single area stereotyped attacks are not characteristic of proven embolic diseases such as bacterial endocarditis.

The patient with transient attacks and occlusion of the internal carotid artery presents another problem in understanding mechanisms. The vascular pathway from the stump of an occluded internal carotid artery or from a stenosed contralateral internal carotid artery to the eye or hemisphere is long and circuitous involving a multitude of collateral and retrograde flowing vessels. For embolic material to do this and only this repeatedly, while possible, seems illogical.

Finally, angiography in many patients with ischemic attacks fails to show a source of embolic material and cardiac assessment reveals no disease. From 20 to 40% of patients with TIAs have normal carotid angiograms (Pessin et al., 1977; Easton and Hart, 1983). All of these considerations suggest that remotely originating emboli are an unlikely cause for a substantial number of cerebral or ocular ischemic attacks.

An alternative explanation is a change in blood viscosity. There is good evidence that increased viscosity may lead to ischemic episodes, either stroke or TIA (Dintenfass, 1981; Thomas, 1982). Viscosity is related directly to hematocrit and red cell aggregability and inversely to red cell flexibility and shear rate. Red cell aggregation and flexibility both relate directly to shear rate. The latter is dependent on the diameter of the vessel and the rate of flow and both of these factors change from second to second in a dynamic, pulsatile, system.

Data relative to the above in the present investigation concerns the rate of flow in the ophthalmic artery in the presence of disease of the internal carotid artery. The velocity in the ophthalmic artery is decreased with increasing age and carotid

artery stenosis. The greater the degree of stenosis the lower the velocity (Figure 4). It is presumed that disease of the internal carotid artery would affect the velocity in the middle cerebral and ophthalmic artery in the same way.

It is not known how much this change in velocity contributes to a hyperviscous state. However, it is known that at low flow rates (shear rates) viscosity can be increased five to ten fold in patients with ischemic disease relative to the normal (Tracy, Lord et al., 1981). The increase is attributed to excessive red blood cell aggregation.

Excessive red cell aggregation displaces platelets from the axial stream into the peripheral high shear rate zone. This increases platelet adhesiveness and these aggregates of platelets and red blood cells plug capillaries and arterioles. Local microcapillary stasis results and this adds to the hyperviscous state. It does so by enhancing red cell rigidity from hypoxia. The whole process is reversible (Dintenfass, 1966). As Thomas (1982) has so aptly put it "A viscous, viscous circle might be entered, with progressively slower flows favoring thrombus formation . . . any improvement in flow, results in an increase in shear rates and a reduction in viscosity."

Other factors which may add to the hyperviscous state, but which have not been fully examined in a large group of patients with TIAs are red cell flexibility, hematocrit and its diurnal variation, and the composition of the membrane of the red cell.

The red cell is stiffer and less flexible in patients with acute myocardial infarction or intermittent claudication (Drummond et al., 1980; Reid et al., 1976). Apparently, this has not been examined in patients with intermittent or fixed signs of cerebral ischemia.

Under normal conditions the red cell membrane is semifluid (Lee et al., 1973; Singer and Nicolson, 1972). The red cell membrane has a markedly different composition as well as being rigid in the stroke prone age group relative to subjects less than 30 years of age (Hegner et al., 1979). The relationship between hematocrit, viscosity and cerebral blood flow, TIA and stroke (Thomas et al., 1977) deserves further consideration.

In summary, there is reasonable evidence that cerebral flow velocity, shear rate, viscosity, red cell aggregability and deformability as well as relatively minor changes in hematocrit, all may play a role in the pathogenesis of TIAs and stroke.

When these factors are better understood and considered along with stenosis and atheroma of the cranio-cervical vessels, then TIA and stroke mechanisms may be better elucidated.

## ACKNOWLEDGEMENTS

It is a pleasure to thank Gail Landry for literature searches, graphic and art work, and manuscript preparation; Jackie Fraas for 259 angiograms which were retrieved, subtracted and refiled over a three year period; and Mary Sy Cheang, M.Math., Deputy Head, Statistics Section, Computer Department, Health Sciences Centre, University of Manitoba for statistical analysis. This was supported by the Mrs. James A. Richardson Foundation.

## REFERENCES

- Clay C, Vignaud J (1971) Vascularisation de l'orbite, *Encyclopedie Medico-Chirurgicale*, Editor A. Laffant, Paris, 21006: 1-17.  
 Dintenfass L (1966) A preliminary outline of the Blood High Viscosity Syndromes, *Ann. Int. Med.* 118: 427-435.

- Dintenfass L (1981) The clinical impact of the newer research in blood rheology: an overview. *Angiology* 32: 217-229.
- Drummond MM, Lowe GDO, Belch JJJ et al. (1980) An assessment of red cell deformability using a simple filtration method. *J. Clin. Path.* 33: 373-376.
- Duncan GW, Pessin MS, Mohr JP et al. (1976) Transient cerebral ischemic attacks. *Adv. Intern. Med.* 21: 1-20.
- Easton JD, Hart RG (1983) Underestimated causes of stroke. *Ann. Roy. Coll. Phy. & Surg.* 16 (1): 37-43
- Fisher CM (1959) Observations of the fundus oculi in transient monocular blindness. *Neurology* 9: 333-347.
- Green JR, Arana R (1948) Cerebral angiography. *Am. J. Roentg.* 59: 617-650.
- Handel S, Stargadter FL, Glickman MG, Newton TH (1973) Frequency of the ocular choroid blush during arteriography. *Neuroradiology* 6: 50-55.
- Hayreh SS, Dass R (1962) The ophthalmic artery I. Origin and intracranial and intra-canalicular course. *Brit. J. Ophthal.* 46: 65-98.
- Hegner D, Platt D, Heckers H et al. (1979) Age-dependent physicochemical and biochemical studies on human red cell membranes. *Mech. of Age & Dev.* 10: 117-130.
- Lee AG, Birdsall NJM, Metcalf JC (1973) Nmr. studies of biological membranes. *Chem. Br.* 9: 116.
- Millikan CH (1965) The pathogenesis of transient focal cerebral ischemia. *Circulation* 32: 438-449.
- Moller W-D, Wolschendorf K (1978) The dependence of cerebral blood flow on age. *Eur. Neurol.* 17: 276-279.
- Moore WS, Hall AD (1970) Importance of emboli from carotid bifurcation in pathogenesis of cerebral ischemic attacks. *Arch. Surg.* 101: 708-716.
- Pessin MS, Duncan GW, Mohr JP, Pokskanzer DC et al. (1977) Clinical and angiographic features of carotid transient ischemic attacks. *NEJM* 296: 358-362.
- Raney RB, Raney AA (1950) The contribution of cerebral angiography in diagnosis. *Calif. Med.* 72: 342-349.
- Reid HL, Dormandy JA, Barnes AJ et al. (1976) Impaired red cell deformability in peripheral vascular disease. *Lancet* 1: 666-668.
- Ross RT (1977) Transient monocular blindness. *Can. J. Neuro. Sci.* 4: 143-150.
- Singer SJ, Nicolson GL (1972) The fluid mosaic model of the structure of cell membrane. *Science* 175: 720.
- Thomas DJ, Marshall J, Ross-Russell RW et al. (1977) The effect of hematocrit on cerebral blood flow in man. *Lancet* 2: 941.
- Thomas DJ (1982) Whole blood viscosity and cerebral blood flow. *Stroke* 13: 285-286.
- Tracy GD, Lord RSA, McGrath MA (1981) The Role of Viscosity in Peripheral Vascular Disease. From Blood Viscosity in Heart Disease and Cancer. Eds., L. Dintenfass and G.V.F. Seaman, p. 82, Pergamon Press, New York.