

Main Article

Hussein A. El-Shirbeny takes responsibility for the integrity of the content of the paper

Cite this article: Elzayat S, El-Shirbeny HA, Barbara M, Covelli E, Elsheikh MN, Salem MA, Ebeed AI, Elfarargy HH. Does the scutum of the external auditory canal have a role in the stapedotomy operation? A radio-clinical evaluation. *J Laryngol Otol* 2025;1–5. <https://doi.org/10.1017/S002221512400121X>

Received: 16 December 2023

Revised: 9 May 2024

Accepted: 29 May 2024


Keywords:

stapedotomy; scutum length; scutum angle; computed tomography; prediction; otosclerosis

Corresponding author:

Hussein A. El-Shirbeny;
Email: hassien.med_0127@med.kfs.edu.eg;
hussienelshirbeny@gmail.com

Does the scutum of the external auditory canal have a role in the stapedotomy operation? A radio-clinical evaluation

Saad Elzayat¹, Hussein A El-Shirbeny¹ , Maurizio Barbara², Edoardo Covelli², Mohamed Nasser Elsheikh³, Mohammed Abdelbadie Salem⁴, Ahmed I Ebeed⁵ and Haitham H Elfarargy¹

¹Otorhinolaryngology Department, Faculty of Medicine, Kafrelsheikh University, Kafrelsheikh, Egypt, ²Department of Neuroscience, Mental Health and Sensory Organs, Faculty of Medicine and Psychology, Sapienza University, Rome, Italy, ³Otorhinolaryngology Department, Faculty of Medicine, Tanta University, Tanta, Egypt, ⁴Otorhinolaryngology Department, Faculty of Medicine, Mansoura University, Mansoura, Egypt and ⁵Radiology Department, Faculty of Medicine, Kafrelsheikh University, Kafrelsheikh, Egypt

Abstract

Objective. This study aimed to assess the impact of the scutum on oval window accessibility during stapedotomy surgery. Radio-clinical correlation was applied to determine the impact. **Methods.** This was a prospective observational case-series study that included 127 candidates for stapedotomy surgery. The oval fossa was classified into two types according to the accessibility of the stapes footplate.

Results. Both study groups showed a statistically significant difference in pre-operative radiological length as the p value was less than 0.001. The Spearman correlation coefficient revealed that the intra-operative oval window fossa was only significantly related to the radiological scutum length because the p value was less than 0.001.

Conclusion. Our results revealed that the pre-operative radiological length can predict the intra-operative oval fossa type with high sensitivity and specificity. Patients with a pre-operative scutum length of less than 2.35 mm were predicted to have an easily accessible oval window without requiring intra-operative scutum curettage.

Introduction

Otosclerosis is characterised by a change in the composition and architecture of the otic capsule, with ankylosis of the stapes footplate. Conductive hearing loss is the main consequence of otosclerosis, which may extend to the cochlea, causing sensorineural hearing loss (SNHL) or mixed hearing loss.¹

Stapedotomy is the optimal surgical choice to manage conductive hearing loss caused by otosclerosis. It was first described early at the end of the 19th century. Since then, many improvements in surgical techniques and prosthetic materials have been proposed.²

One of the most critical steps during a stapedotomy operation is the appropriate exposure of the oval window fossa. This helps the surgeon reach the stapes footplate with more accurate manipulation and better outcomes.³

Oval window fossa exposure may be problematic because of its close relation to the chorda tympani nerve and the bony overhang of the medial part of the external auditory canal's posterosuperior wall, the scutum.

After the elevation of the tympanomeatal flap and displacement of the chorda tympani nerve, there are variations in the exposed area of the oval window fossa. Sometimes, it is completely exposed; other times, only the lenticular process of the incus can be seen. In the latter case, part of the scutum must be removed by curettage or micro-drill to obtain an adequate exposed oval window fossa.⁴

The prediction of intra-operative variations and difficulties has been at the forefront of recent medicine. Using such predictions, surgeons can be ready for extra surgical steps to achieve the required outcome and prepare any additional tools that may be needed. This will improve the surgical outcome with minor consequences. Using high-resolution computed tomography (CT) before stapedotomy surgery has become routine in many otological centres. It is the gold standard method to evaluate the bony structures of the middle ear.^{5,6}

This study aimed to assess the impact of scutum length on intra-operative oval window accessibility during stapedotomy surgery. This was done by correlating the pre-operative radiological length of the scutum bone in high-resolution CT images with intra-operative oval window accessibility during stapedotomy surgery. This technique will help to predict the need for scutum curettage.

Methods

Ethics

We conducted this research after receiving the approval of the institutional review board. All included procedures were carried out according to the Declaration of Helsinki. We also obtained the patients' informed signed consent to use their data in our research (ethical approval no. KFSIRB200-33).

Study design

This was a prospective observational case-series study (Figure 1).

Settings

All surgical procedures were carried out in the period between February 2022 and May 2023.

Subjects

Sample size calculation revealed that our research should include at least 111 patients with a 95 per cent confidence level, 5 per cent margin of error and 50 per cent population proportion. We included candidates for stapedectomy surgery required because of conductive hearing loss or mixed hearing loss caused by otosclerosis.

Only cases with pre-operative high-resolution CT scans were included. Cases with pure SNHL, previous ear surgery, perforated tympanic membrane and congenital anomalies of the external auditory canal were excluded, therefore out of a total of 155 patients, 127 eligible patients were included. The diagnosis of otosclerosis was confirmed during the surgery.

High-resolution computed tomography protocol

Radiological imaging was performed using a high-resolution CT machine (Toshiba CT Aquilion one 320 multi-slice, Real Madrid, Spain). The CT scan data were acquired at 120 kV, 200 mA and using a 512 × 512 imaging matrix. The axial cuts were obtained parallel to the orbital-meatal baseline and viewed in standard bone window settings. Coronal cuts were made in a plane perpendicular to the axial images at 0.6–0.5-mm intervals.

High-resolution computed tomography evaluation

Two physicians assessed independently the coronal cut of the pre-operative high-resolution CT, which clearly showed the scutum and the incudo-stapedial joint in the oval fossa area. The scutum length was measured between two points, the first at the superior border of the external auditory canal and the second at the inferior border of the scutum.

On the other side, the scutum angle was measured between a line represented the upper border of the external auditory canal and a line represented the bony overhang of the scutum. The averages of the radiological length and angle of both high-resolution CT reviewers were considered (Figures 2 and 3).

Intra-operative evaluation

All surgical procedures were performed under general anaesthesia through the trans-canal approach. The surgeon, blind to the radiological measurements, judged the oval window fossa area after elevation of the tympano-meatal flap and the anteroinferior displacement of the chorda tympani nerve. According to the accessibility of the stapes footplate and the need to remove part of the scutum, we classified the oval fossa into two types: the type I oval window fossa, where the stapes footplate was entirely accessible without scutum removal (Figure 4), and the type II oval window fossa, where the stapes footplate was partially visible or inaccessible, requiring scutum removal to accomplish the stapedotomy operation (Figure 5).

Outcome measures

To find possible relationships, we correlated the intra-operative oval window fossa type with the pre-operative radiological parameters.

Statistical analysis

Statistical analysis was done using SPSS v27 (IBM© Inc., Chicago, IL, USA). Numerical variables were presented as the mean and standard deviation (SD). Categorical variables were presented as the frequency and percentage. We used Mann–Whitney *U* test to compare the numerical variables and the chi-square test to compare the categorical variables of both groups. A *p* value less than 0.01 was considered

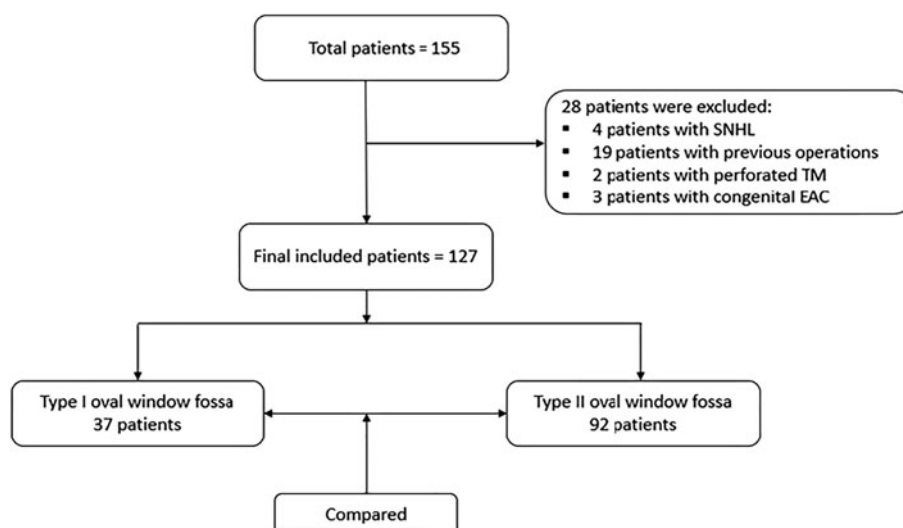


Figure 1. Study design. SNHL = sensorineural hearing loss; TM = tympanic membrane; EAC = external auditory canal

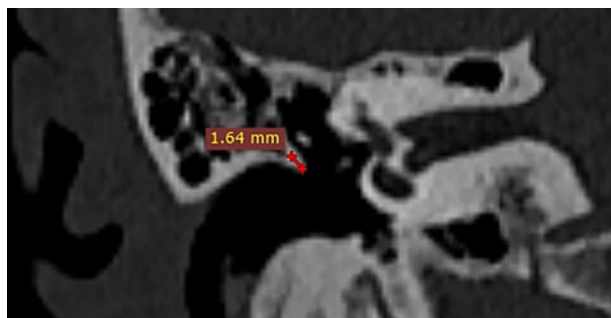


Figure 2. The right coronal cut of the pre-operative high-resolution computed tomography image shows a completely accessible stapes footplate (type I), angle 98.6° and length 1.64 mm.

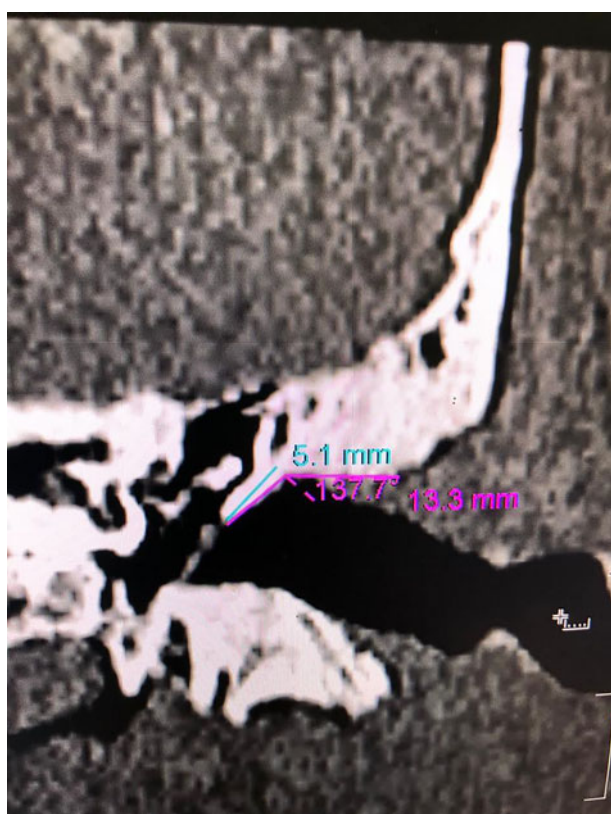


Figure 3. The left coronal cut of the pre-operative high-resolution computed tomography image shows a completely inaccessible stapes footplate (type II), angle 137.7° and length 5.1 mm.

significant. We used Spearman's correlation coefficient to detect the relationship between the intra-operative oval window fossa type and the other variables. There was a significant relationship if the p value was less than 0.01. We used the intra-class correlation coefficient test to assess the inter-observer variability.

Results

The included patients were divided into two groups according to the intra-operative oval window fossa type. Group A, in which the oval window fossa was accessible without any scutum curette (type I), included 35 patients (27.6 per cent). Group B, in which the oval window fossa was accessible after the curette of the scutum, involved 92 patients (72.4 per cent).

Overall, there were 59 males (56.5 per cent) and 68 females (53.5 per cent), aged 22 to 65 years, with a mean of $43.72 \pm$

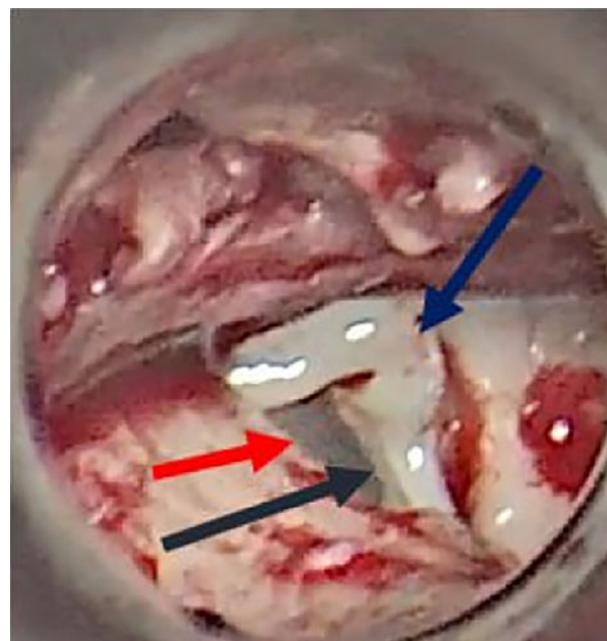


Figure 4. The right intra-operative high-resolution computed tomography image shows an entirely accessible stapes footplate without curettage (type I). Red arrow = non-curetted scutum; black arrow = stapes footplate; blue arrow = incudo-stapedial joint

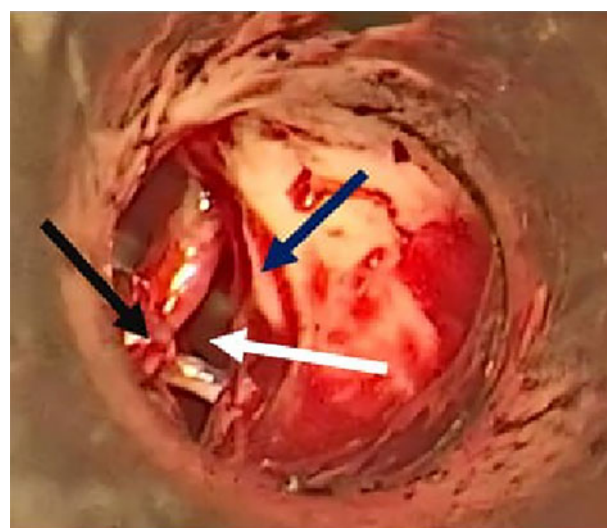


Figure 5. The left intra-operative high-resolution computed tomography image shows an entirely inaccessible stapes footplate after curettage (type II). White arrow = stapes footplate and oval window; black arrow = incudo-stapedial joint; blue arrow = curetted scutum

10.01 years. The operation was carried out on the right side in 77 patients (60.6 per cent) and on the left side in 50 patients (39.4 per cent). The reversal stapedotomy technique was used in 86 patients (67.7 per cent), while the traditional non-reversal technique was used in 41 patients (32.3 per cent). Neither group showed statistically significant differences regarding age, sex, operation side or technique used for stapedotomy ($p > 0.001$) (Table 1).

The radiological scutum length ranged from 1.6 to 2.8 mm, with a mean of 2.04 ± 0.25 in group A. It ranged from 2.6 to 5.6 mm with a mean of 3.67 ± 0.69 in group B, with a statistically significant difference between the groups because p was less than 0.001 (Table 2).

The radiological scutum angle ranged from 102° to 153°, with a mean of 136.21 ± 11.88 in group A and from 96° to

Table 1. Comparison between both groups A (type I oval fossa, accessible without curettage) and group B (type II oval fossa, accessible after curettage)

Parameter	Measurement	Group A (N = 35/127 (27.6%))	Group B (N = 92/127 (72.4%))	p value
Age (n; years)	Minimum	25	22	0.773
	Maximum	63	65	
	Mean \pm SD	43.29 \pm 9.16	41.88 \pm 10.36	
Sex (n (%))	Male	15 (42.9)	44 (47.8)	0.616
	Female	20 (57.1)	48 (52.2)	
Operation side (n (%))	Right	24 (68.6)	53 (57.6)	0.259
	Left	11 (31.4)	39 (42.4)	
Scutum length (mm)	Minimum	1.6	2.6	<0.001 *
	Maximum	2.8	5.6	
	Mean \pm SD	2.04 \pm 0.25	3.67 \pm 0.69	
Scutum angle (°)	Minimum	102	96	0.072
	Maximum	153	165	
	Mean \pm SD	136.21 \pm 11.88	139.88 \pm 13.19	
Technique used (n (%))	Reversal	25 (71.4)	61 (66.3)	0.581
	Traditional2	10 (28.6)	31 (33.7)	

*Significant, $p < 0.01$. SD = standard deviation; Traditional2 = Classic non-reversal stapedotomy

165° with a mean of 139.88 ± 13.19 in group B, without a statistically significant difference between the groups because p was 0.072.

The intraclass correlation coefficient between the measures of both high-resolution CT reviewers was 0.96 for the radiological length and 0.98 for the radiological angle, which indicates excellent agreement between their measurements.

The Spearman correlation coefficient revealed that the intra-operative oval window fossa related significantly only to the radiological scutum length because p was less than 0.001.

Moreover, the receiver operating characteristic curve revealed a significant correlation between the intra-operative oval window fossa and the radiological scutum length because the area under the curve was 0.997. According to this curve, the best cut-off point was 2.35 mm. At this point, the sensitivity was 100 per cent and the specificity was 94.3 per cent.

Discussion

Pre-operative imaging is not carried out routinely when evaluating otosclerosis, but it plays a role in identifying the extent and location of the otosclerotic lesion and determining the appropriate surgical approach and technique. One of the

most commonly used radiological techniques in the pre-operative evaluation of otosclerosis is high-resolution CT. High-resolution CT provides detailed images of the temporal bone, allowing accurate assessment.^{7,8}

Zanoletti *et al.*⁹ evaluated the correlation between high-resolution CT findings and surgical outcomes in 118 patients who underwent stapedectomy for otosclerosis. The authors found that high-resolution CT accurately identified the location and extent of otosclerotic lesions in all patients. The surgical outcomes were better in patients with isolated lesions than in those with more diffuse disease, reflecting the importance of pre-operative high-resolution CT in otosclerosis cases.¹⁰

The scutum bone is the medial part of the external auditory canal's posterosuperior bony overhang, which wholly or partially covers the oval window fossa. The scutum bone is variable in length and sloping angle.^{11,12} These anatomical variations of the scutum impact the visibility and accessibility of the oval window during stapedotomy surgery, impacting the surgical steps and time needed to expose the field to complete the procedure.

A single-arm observational study⁴ measuring the anatomical variations of the posterosuperior bony overhang of the external auditory canal in 100 patients with otosclerosis divided the included subjects into four groups according to the intra-operative scutum length. The researchers measured various parameters related to the posterosuperior bony overhang, such as its length, thickness and angle with the horizontal plane.

The overhang was present in all ears, but its size and shape varied considerably among individuals. According to their observations, the average length of the overhang was 2–2.5 mm. The scutum bone was observed in those with a sloping external auditory canal more often than in those with straight canals. The study found that the size and shape of the overhang were independent of age, sex and ear side. However, there was a significant correlation between the length and thickness of the overhang, suggesting that these parameters may be related to the strength and stability of the bony structure.⁴

Table 2. Bivariate correlation between the intra-operative oval window fossa and other variables

Parameter	Spearman correlation coefficient	p value
Age	0.026	0.774
Sex	−0.045	0.619
Operation side	0.1	0.262
Scutum length	0.77	<0.001 *
Scutum angle	0.16	0.072
Technique used	0.049	0.585

*Significant, $p < 0.01$.

The study also found that the bony overhang can affect the intra-operative exposure of the incudo-stapedial joint. Moreover, the authors mentioned that the presence of bony spurs or ridges in this region, which were observed in most patients, could potentially affect the visibility of the oval window.

Our study focused on the radiological pre-operative detection of scutum length and angles in high-resolution CT of the petrous bones with intra-operative correlation to reach an accurate cut-off point that can predict the accessibility of the oval window and help determine a detailed pre-operative plan. After the elevation of the tympanomeatal flap, all or a part of the incudo-stapedial joint can be seen. This is an essential landmark of the oval window, as illustrated in Miglets and Paparella's study.¹³ Only 27.6 per cent of cases show naturally accessible oval windows after the elevation of the tympanomeatal flap without scutum curettage.

Our study divided patients into two groups according to radiological scutum length: group A, where the scutum length ranged from 1.6 to 2.8 mm, and group B, where it ranged from 2.6 to 5.6 mm. This radiological classification followed with the operative classification of Glasscock and Shambaugh's study¹⁴ regarding scutum length.

Based on the operative classification illustrated by Roychaudhuri *et al.*,⁴ we introduced a pre-operative radiological complementary method to correlate and strengthen its results, which help to predict the oval fossa type.

This radio-clinical correlation may help in more precise planning for stapedotomy surgery. It can predict the surgery duration and the need for other ordinary instruments, such as those required for drilling for scutum removal. Moreover, in long scutum bone, an endoscope may be planned to help access the oval window, or the stapedotomy operation may be endoscopic from the start. We believe this prediction can help junior and senior stapedotomy surgeons improve the outcomes of stapedotomy surgery.

During stapedotomy surgery, there are two main techniques: the reversal technique, in which the prosthesis is inserted before separating the incudo-stapedial joint and cutting the stapedius tendon, and the conventional non-reversal technique, in which the prosthesis is inserted after separating the incudo-stapedial joint and cutting the stapedius muscles. Our results revealed that the scutum length and angle impacted the stapedotomy technique.¹⁵

- This prospective observational case-series study aimed to assess the impact of the scutum on oval window accessibility during stapedotomy surgery
- According to the accessibility of the stapes footplate, the oval fossa was classified into two types
- Both study groups showed a statistically significant difference in pre-operative radiological length because p was less than 0.001
- The Spearman correlation coefficient revealed that the intra-operative oval window fossa was significantly related only to the radiological scutum length because p was less than 0.001
- Patients with a pre-operative scutum length of less than 2.35 mm were predicted to have an easily accessible oval window without requiring intra-operative scutum curettage

Our research mainly focused on microscopic stapedotomy surgical procedures, which are common among otologists

worldwide, and we tried have to provide concise pre-operative planning regarding scutum status and oval window accessibility. Future research is needed to assess the applicability of our proposals for endoscopic stapedotomy surgery.

Conclusion

Our results on a relatively large number of patients show that pre-operative radiological length can predict the intra-operative oval fossa type with high sensitivity and specificity. The best cut-off point of the pre-operative radiological scutum length was 2.35 mm. Patients with a pre-operative scutum length of less than 2.35 mm were predicted to have an easily accessible oval window with a completely visible incudo-stapedial joint without requiring intra-operative scutum curettage. These variations in scutum length did not impact the stapedotomy technique (reversal or non-reversal).

References

- 1 Milanese U, Pasquariello B, Saibene AM, Felisati G, Atac M, Corbetta D. Three-dimensional exoscope-assisted laser stapedotomy: a preliminary experience. *Eur Arch Otorhinolaryngol* 2021;**278**:4593–8
- 2 Häusler R. General history of stapedectomy. *Adv Otorhinolaryngol* 2007;**65**:1–5
- 3 Wickemeyer J, Achim V, Redleaf M. Stapedectomy is rewarding: but how to prove it? *Ann Otol Rhinol Laryngol* 2019;**128**:911–14
- 4 Roychaudhuri BK, Roychowdhury A, Ghosh S, Nandy S. Study on the anatomical variations of the posterosuperior bony overhang of the external auditory canal. *Indian J Otolaryngol Head Neck Surg* 2011;**63**:136–40
- 5 Stenz NA, Hashmi S, Lehnick D, Treumann T, Linder T. Stellenwert der Computertomographie in der präoperativen Diagnostik der Otosklerose [Role of computed tomography in the preoperative diagnosis of otosclerosis]. *HNO* 2023;**71**:92–9
- 6 Tan TY, Lim CC, Boey HK. High resolution computed tomography of the temporal bone: preliminary experience. *Ann Acad Med Singap* 1994;**23**:869–75
- 7 Purohit B, Hermans R, Op de Beeck K. Imaging in otosclerosis: a pictorial review. *Insights Imaging* 2014;**5**:245–52
- 8 Révész P, Liktó B, Sziklai I, Gerlinger I, Karosi T. Comparative analysis of preoperative diagnostic values of HRCT and CBCT in patients with histologically diagnosed otosclerotic stapes footplates. *Eur Arch Otorhinolaryngol* 2016;**273**:63–72
- 9 Zanoletti E, Mazzoni A, Martini A, Abbritti RV, Albertini R, Alexandre E, *et al.* Surgery of the lateral skull base: a 50-year endeavour. *Acta Otorhinolaryngol Ital* 2019;**39**(Suppl 1):S1–146.
- 10 Kataria T, Sehra R, Grover M, Sharma S, Verma N, Sharma MP. Correlation of preoperative high-resolution computed tomography temporal bone findings with intra-operative findings in various ear pathologies. *Indian J Otolaryngol Head Neck Surg* 2022;**74**:190–9
- 11 Covelli E, Elfarargy HH, Filippi C, Margani V, Volpini L, Barbara M. Thulium laser in stapedotomy surgery. *Acta Otolaryngol* 2022;**142**:234–40
- 12 Cattaneo PM, Bloch CB, Calmar D, Hjortshøj M, Melsen B. Comparison between conventional and cone-beam computed tomography-generated cephalograms. *Am J Orthod Dentofacial Orthop* 2008;**134**:798–802
- 13 Miglets AW, Paparella MM. *Atlas of Ear Surgery*, 4th edn. Toronto: Saunders, 1986; 38
- 14 Glasscock ME, Shambaugh GE Jr. *Surgery of the Ear*, 2nd edn. Philadelphia: Saunders, 1990; 393
- 15 Barbara M, Elzayat S, El-Shirbeny HA, Salem MA, Ebeed AI, Covelli E *et al.* Assessment of the ability of the radiological incudo-stapedial angle to predict the stapedotomy technique type: a prospective case-series study. *Eur Arch Otorhinolaryngol* 2023;**280**:4879–84