

# Residual cervical lymphadenopathy after definitive treatment of nasopharyngeal carcinoma: fine needle aspiration cytology, computed tomography and histopathological findings

S-T TOH<sup>1</sup>, H-W YUEN<sup>3</sup>, K-H LIM<sup>2</sup>, Y-H GOH<sup>1</sup>, H-K C GOH<sup>1</sup>

<sup>1</sup>Departments of Otolaryngology – Head and Neck Surgery, <sup>2</sup>Pathology, Singapore General Hospital, and  
<sup>3</sup>Department of Otolaryngology – Head and Neck Surgery, Changi General Hospital, Republic of Singapore

## Abstract

**Background:** Patients with nasopharyngeal carcinoma may have residual cervical lymphadenopathy after definitive treatment of the primary tumour and regional cervical nodal disease. Whether such lymphadenopathy truly represents persistent disease is unclear. There are few published studies addressing this clinical problem.

**Methods:** We retrospectively and systematically reviewed the clinical records of 12 patients with nasopharyngeal carcinoma who had presented to a tertiary academic hospital, over an 11-year period, with suspected persistent cervical nodal disease after definitive radiotherapy or concurrent chemoradiotherapy. Findings on fine needle aspiration cytology and computed tomography scanning were correlated with final histopathological results.

**Results:** The incidence of negative neck dissection was 41.7 per cent. The positive and negative predictive values of fine needle aspiration cytology in identifying disease were 100 and 42.9 per cent, respectively. Computed tomography scanning had a positive predictive value of 58.3 per cent in identifying disease.

**Conclusion:** In patients treated definitively for nasopharyngeal carcinoma, residual cervical lymphadenopathy may not represent persistent disease. Head and neck surgeons involved in the management of these patients should bear in mind the current limitations of fine needle aspiration cytology and computed tomography in confirming the diagnosis pre-operatively. Salvage neck dissection may over-treat some of these patients.

**Key words:** Nasopharynx Neoplasms; Neoplasm Metastasis; Cervical Lymph Nodes

## Introduction

Nasopharyngeal carcinoma is a distinct clinical entity which is endemic in the southern Chinese population but rare in Caucasians. In Singapore, it is the commonest head and neck cancer, with age-standardised incidences in males and females of 10.8 and 3.7 per 100 000 per year, respectively.<sup>1</sup> This radiosensitive tumour is usually treated with radiotherapy.<sup>2,3</sup> In recent years, concurrent chemoradiotherapy has been used to treat advanced locoregional disease, with better survival results.<sup>4,5</sup>

After completion of their definitive treatment regimes, and with complete clinical response of the primary nasopharyngeal carcinoma, some patients have residual cervical lymphadenopathy. Such lymphadenopathy may harbour disease or may merely represent post-treatment necrosis or hyaline fibrosis, without viable tumour cells. There is a paucity of data addressing the management of this clinical problem. Furthermore, the best method of determining

the presence of persistent disease in this group of patients is currently not known. The treatment of persistent cervical nodal disease after definitive neck treatment in patients with nasopharyngeal carcinoma is controversial; studies have often combined this patient group with patients presenting with recurrent nodal disease. Some centres have advocated repeated radiotherapy for the treatment of such persistent cervical lymphadenopathy, while others have recommended surgery.<sup>6–11</sup>

Previously, we have published data on the use of fine needle aspiration cytology (FNAC) and computed tomography (CT) scanning in assessing recurrent cervical nodal disease, together with data on the incidence of negative neck dissection in cases of recurrent nodal disease.<sup>12</sup> We believe that residual cervical lymphadenopathy represents a distinct clinical challenge and should be addressed separately.

We postulate that, in patients with nasopharyngeal carcinoma who present with residual cervical

lymphadenopathy after completion of a definitive treatment regime, such lymphadenopathy may not necessarily represent persistent nodal disease. In this study, we aimed (a) to investigate the diagnostic value of FNAC and CT scanning in such patients, and (2) to determine the incidence of negative neck dissection in this clinical group. We hope that our results will clarify the management of this select group of patients.

### Methods and patients

This was a retrospective clinical review of patients who had undergone curative treatment for nasopharyngeal carcinoma and who subsequently presented with residual cervical lymphadenopathy to the Otolaryngology and Head and Neck surgery department of Singapore General Hospital over an 11-year period (April 1995 to December 2006). Twelve such patients were identified and their clinical, radiological, surgical and histological records reviewed. Patients with histologically proven residual disease at the primary site were excluded from the study.

All 12 patients received either a standard course of conventional radiotherapy or concurrent chemoradiotherapy, and all patients completed their treatment protocols. Patients who received standard radiotherapy received 70 Gy in 35 fractions, 2 Gy per fraction. The neck was treated with 60 Gy, and lymph nodes were boosted with electrons for another 10 Gy. All fields were treated once daily, five times a week. Patients who were treated with chemoradiotherapy received concurrent cisplatin administered during weeks one, four and seven of radiotherapy, plus further adjuvant cisplatin and fluorouracil chemotherapy between weeks 11 and 19.<sup>5</sup> Patients underwent a standardised post-treatment surveillance protocol involving both

the otolaryngologist and radiotherapist. In the first year post-treatment, all patients underwent monthly reviews to detect residual disease at the primary site and cervical lymph nodes.

'Residual or persistent nodal disease' was defined as persistence of lymphadenopathy, without complete remission, after completion of the entire treatment regime.<sup>6</sup> In the group of patients in question, there is currently no standardised time-frame for observation of lymphadenopathy prior to investigation or treatment for possible persistent nodal disease. In our institution, we perform a CT scan and FNAC if the patient has residual, clinically palpable lymphadenopathy three months after completion of definitive treatment.

We assessed the diagnostic value of FNAC and CT in determining residual nodal disease in this clinical setting. All patients with clinically palpable residual cervical nodes underwent standard FNAC. Briefly, aspiration of cells from palpable lymph nodes was performed using a 23-gauge needle mounted on a 10-ml syringe, making 10–15 passes in multiple directions. Both air-dried and wet-fixed slides were prepared, and the adequacy of the specimen was checked by a trained technician. The slides were reviewed by fellowship-trained pathologists who were part of the multidisciplinary head and neck tumour team. The FNAC result was defined as 'positive' if malignant cells with nuclear pleomorphism and scanty cytoplasm with ill-defined cytoplasmic borders were seen (Figure 1), 'negative' if no malignant cells were seen (Figure 2), and 'inconclusive' if atypical cells were seen which were suspicious for malignancy but inconclusive (Figure 3). We compared the FNAC findings with results for final histological examination of surgically resected lymph node specimens. We then calculated the sensitivity, specificity, and positive and negative predictive values of FNAC in assessing persistent nodal disease.

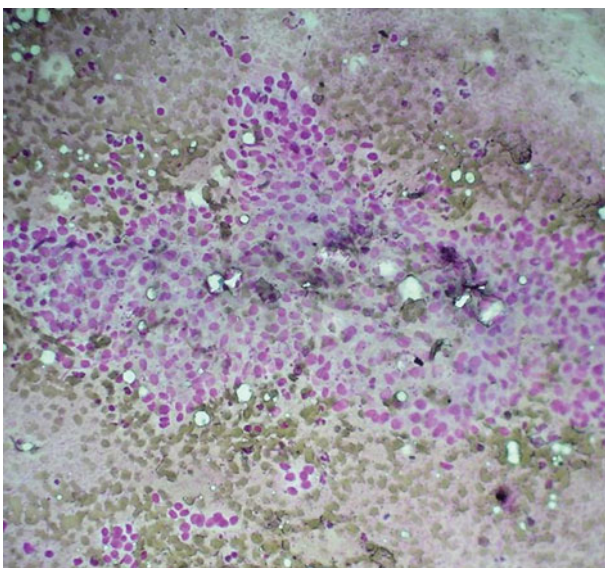


FIG. 1

Photomicrograph of fine needle aspirate from residual cervical lymph node persisting after definitive treatment, showing malignant cells. (Diff Quik (DQ);  $\times 200$ )

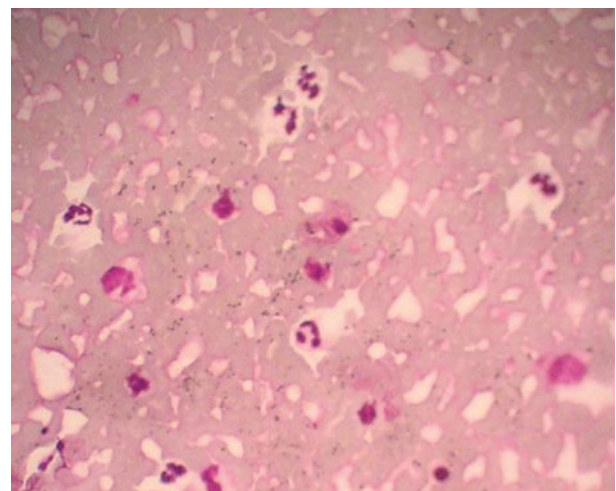


FIG. 2

Photomicrograph of fine needle aspirate from a residual cervical lymph node persisting after definitive treatment, showing neutrophils and lymphocytes on a background of red blood cells. (Diff Quik (DQ);  $\times 400$ )

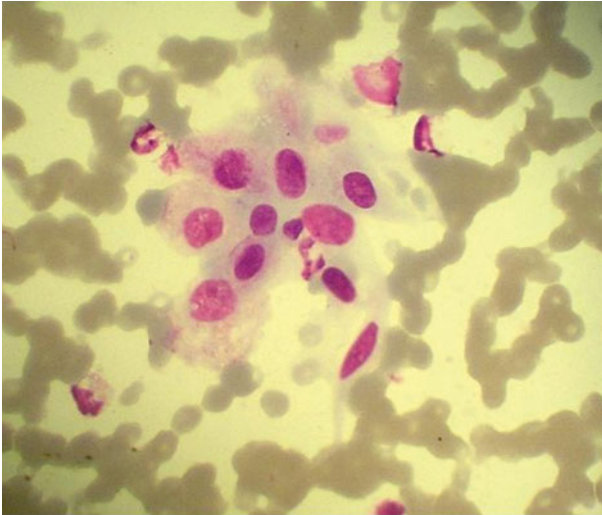


FIG. 3

Photomicrograph of fine needle aspirate from a residual cervical lymph node persisting after definitive treatment, showing a cluster of atypical cells. (Diff Quik (DQ);  $\times 600$ )

Computed tomography findings were also correlated with the final histopathological results. A CT scan was considered positive for pathological lymphadenopathy based on the following criteria: the presence of nodal necrosis, and/or the presence of lymph nodes with a greatest diameter of more than 10 mm.<sup>13–15</sup>

## Results

During the review period, 12 patients presented with suspected persistent nodal disease after completing their respective treatment regimes. All patients had World Health Organization type 2a or 2b nasopharyngeal carcinoma at primary diagnosis.

TABLE I  
CHARACTERISTICS OF STUDY POPULATION

Parameter	Value
<i>Age (years)</i>	
Mean	46.2
Range	38–63
<i>Sex (n (%))</i>	
Male	10 (83.3)
Female	2 (16.7)
<i>Treatment (n (%))</i>	
RT	9 (75)
Concurrent CRT	3 (25)
<i>FNAC result (n (%))</i>	
Positive	1 (8.3)
Negative	7 (58.4)
Inconclusive	4 (33.3)
<i>Post-RT lymph node size on CT (mm)</i>	
Mean	22
Range	16–36
<i>Final neck dissection specimen (n (%))</i>	
Positive	7 (58.3)
Negative	5 (41.7)
<i>Total (n (%))</i>	12 (100)

RT = radiotherapy; CRT = chemoradiotherapy; FNAC = fine needle aspiration cytology; CT = computed tomography

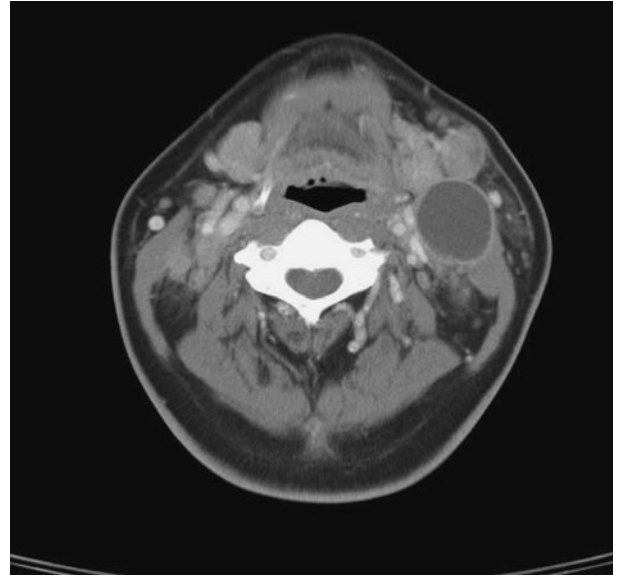


FIG. 4

Axial computed tomography neck scan with intravenous contrast, for a patient with untreated nasopharyngeal carcinoma and cervical nodal disease.

The demographics of the study population are shown in Table I.

All 12 patients had clinically and radiologically evident pathological residual cervical lymphadenopathy suggestive of persistent disease. All patients had previously had a complete response of the primary tumour to treatment, both clinically and radiologically. Figure 4 shows a CT scan of the pre-irradiated neck of a patient with nasopharyngeal carcinoma and left

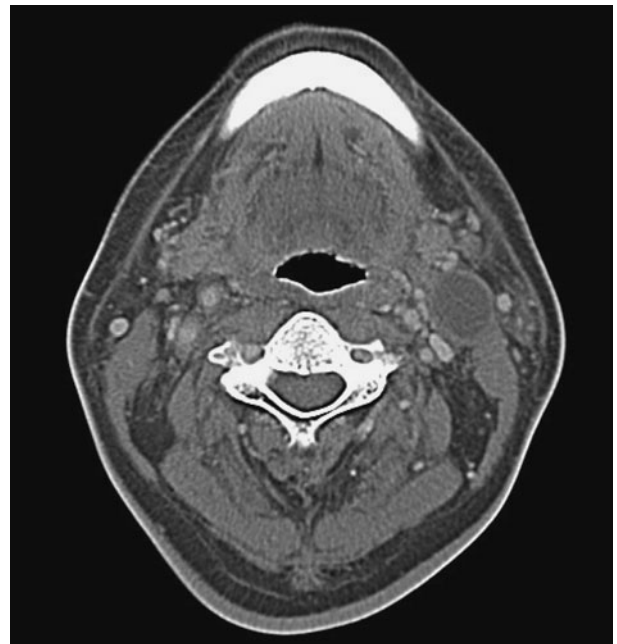


FIG. 5

Axial computed tomography scan with intravenous contrast for the same patient as in Figure 4, after definitive treatment; cervical lymphadenopathy is reduced in size but not completely resolved.

cervical lymph node enlargement. Figure 5 shows a CT scan of the same patient three months after treatment, which fulfils the criteria for pathological lymphadenopathy. Fine needle aspiration cytology was negative for malignancy. This patient underwent radical neck dissection for suspected persistent disease; final histopathological examination showed hyalinised necrosis but no viable tumour cells (Figure 6).

Fine needle aspiration cytology was performed for all 12 patients. One of these examinations (8.3 per cent) was positive for malignant cells, seven (58.4 per cent) were negative for malignancy, and four (33.4 per cent) contained atypical cells which were suspicious for malignancy but inconclusive.

These FNAC results were correlated with the results of histological examination of neck dissection specimens. Seven (58.3 per cent) of the 12 patients had a positive result for histological examination of the final neck specimen, while the other five (41.7 per cent) had a negative result. The sensitivity, specificity and diagnostic predictive values of FNAC were calculated for the eight patients with a definite (either positive or negative) FNAC report, and are shown in Table II. Three (75 per cent) of the four patients with a suspicious FNAC result had a positive neck dissection specimen result.

All 12 patients received a radical or modified radical neck dissection: nine underwent unilateral radical neck dissection and three bilateral synchronous neck dissection (i.e. a radical neck dissection on one side and a contralateral modified radical neck dissection sparing the internal jugular vein).

Five (41.7 per cent) of the 12 patients had no viable tumour cells in the resected lymph nodes; nodes showing tumour necrosis or hyalinisation (Figures 7 and 8).

The other seven (58.3 per cent) patients had positive neck dissections with lymph node involvement on more than one level, although their CT scans showed

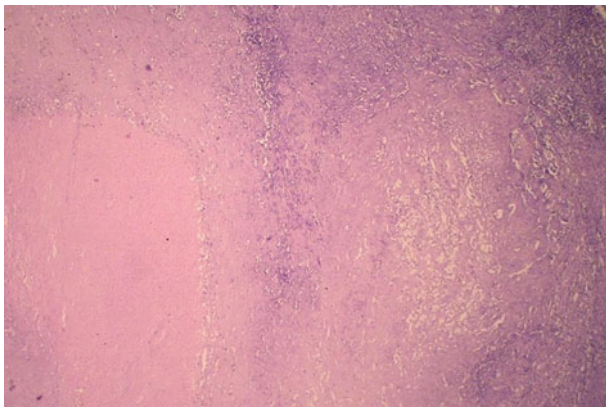


FIG. 6

Photomicrograph of a large, 3.6-cm, necrotic cervical lymph node taken from the same patient as in Figure 4 following definitive treatment, showing hyalinised necrosis with no viable tumour cells. A rim of benign lymphoid cells is seen on the right. (H&E; ×100)

TABLE II SENSITIVITY/ SPECIFICITY/ POSITIVE AND NEGATIVE PREDICTIVE VALUE OF FNAC IN ASSESSING RESIDUAL CERVICAL NODAL LYMPHADENOPATHY FOR DISEASE	
Sensitivity	25%
Specificity	100%
Positive predictive value	100%
Negative predictive value	42.9%

only single level involvement. Two patients had level one nodal involvement, all seven patients had level two nodal involvement and three patients had level three nodal involvement. Figure 9 shows a pre-treatment CT neck scan of a patient with bilateral cervical nodal disease. Three months after completion of treatment, this patient had residual left level two cervical lymphadenopathy with central necrosis (Figure 10). Fine needle aspiration cytology of the lymph node showed atypical cells. The patient underwent radical neck dissection. The final histopathological specimen was positive and had more nodal disease than was suggested by the CT scan.

## Discussion

Our study results indicate that residual cervical lymphadenopathy after definitive treatment for nasopharyngeal carcinoma does not necessarily represent persistent disease. In five (41.7 per cent) of our 12 patients, the final histopathological neck dissection specimen did not show viable tumour cells.

Residual cervical lymphadenopathy after curative radiotherapy or chemoradiotherapy for nasopharyngeal carcinoma is a challenging clinical problem. The need for treatment of residual lymphadenopathy, and the

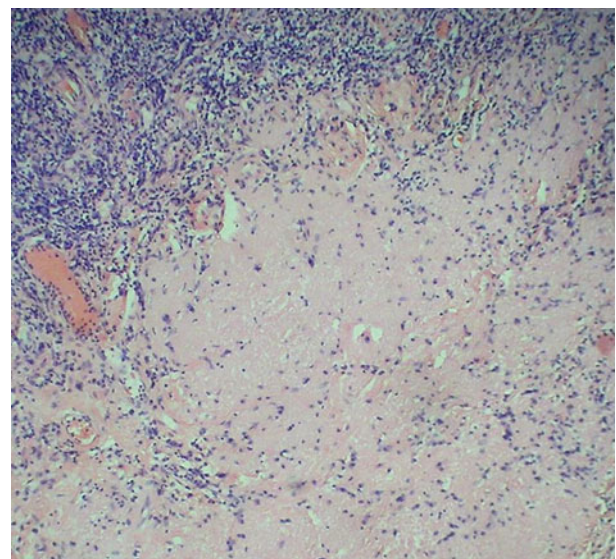


FIG. 7

Photomicrograph of a 2-cm residual cervical lymph node after definitive treatment for nasopharyngeal carcinoma, showing hyalinisation of lymph node with peripheral residual normal lymphocytes. (H&E; ×200)

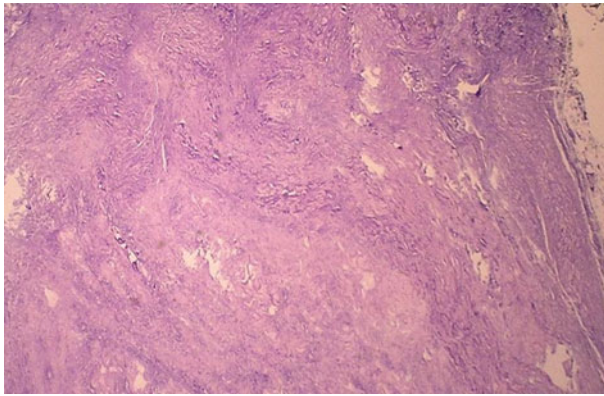


FIG. 8

Photomicrograph of another patient's hyalinised lymph node, with no malignant cells seen. (H&E;  $\times 100$ )

timing and best modality of such treatment, are still controversial issues. Most published studies have combined this patient group with patients with recurrent nodal disease.<sup>6–9</sup> In our clinical practice, however, we encountered a substantial number of negative neck dissections in this group of patients, and felt that such cases should be addressed separately; we therefore undertook the present study.

Ho *et al.* studied patients undergoing radical neck dissection for suspected persistent cervical nodal disease, and found tumour cells in all their patients' histological specimens (i.e. the negative neck dissection rate was 0 per cent).<sup>6</sup> However, Chen and Fletcher did not find any viable tumour cells in the radical neck dissection specimens of their six patients

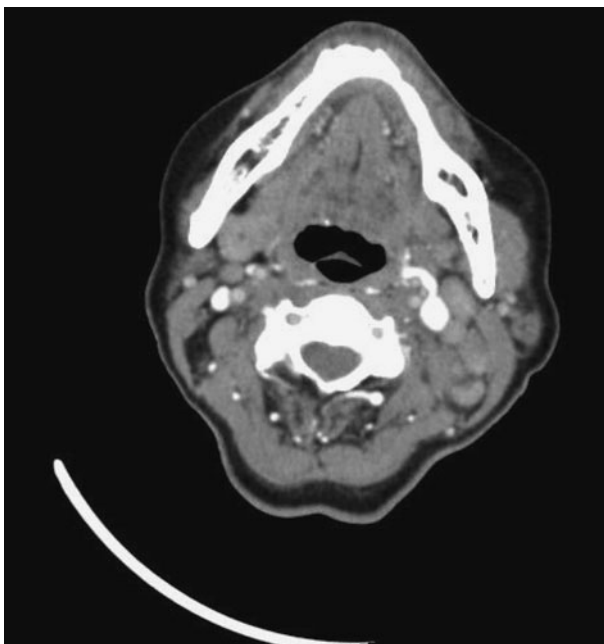


FIG. 9

Pre-treatment axial computed tomography scan with intravenous contrast, showing bilateral cervical nodal disease in a patient with nasopharyngeal carcinoma.

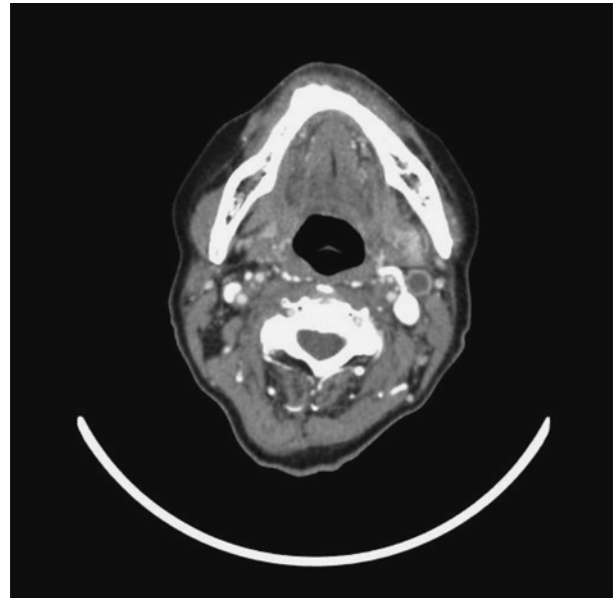


FIG. 10

Post-treatment axial computed tomography scan with intravenous contrast, for the same patient as in Figure 9, showing residual left cervical lymph node with central necrosis.

whose nodes did not resolve after radiotherapy (a negative neck dissection rate of 100 per cent). Perez *et al.* reported that only one out of seven patients undergoing neck dissections for suspected persistent nodal disease had histological specimens containing tumour cells (a negative neck dissection rate of 85.7 per cent).<sup>10,11</sup> Wei *et al.* reported that one out of five patients with suspected persistent nodal disease did not show any tumour cells in their neck dissection specimen (a 20 per cent negative neck dissection rate), of 109 lymph node specimens.<sup>9</sup> In the patient with negative neck dissection, the authors showed that the 2 cm persistent lymph node showed reactive hyaline fibrosis.

In our study of patients with suspected persistent cervical nodal disease after curative treatment for nasopharyngeal carcinoma, the incidence of negative neck dissection, from final histological specimens, was 41.7 per cent (five out of 12 patients). In such negative neck dissection cases, the final histological specimen showed either necrosis without viable tumour cells (Figure 6) or hyalinisation of the nodes (Figure 7). Our patients' negative neck dissection rate was higher than that of patients with recurrent nodal disease. The negative neck dissection rate for patients with recurrent nodal disease following nasopharyngeal carcinoma treatment is well established. In a separately published study, we reported a 10.8 per cent negative neck dissection rate for 42 patients presenting with recurrent nodal disease.<sup>12</sup> Other studies combining patients with residual and recurrent disease in their analysis have reported negative neck dissection rates of 4–12 per cent.<sup>8,9</sup>

There is no standardised time-frame for observing residual lymph nodes before instituting treatment.

Perez *et al.* reported waiting at least four weeks before performing radical neck dissection for seven patients with suspected persistent nodal disease.<sup>11</sup> Yen *et al.* studied four patients with suspected persistent nodal disease, and reported waiting for two consecutive months to allow a more objective assessment of the disease state of the neck, before performing salvage neck dissection at nine to 10 weeks.<sup>7</sup> Wei *et al.* reported waiting three months after completion of radiotherapy before undertaking salvage surgery in five patients with persistent nodal disease.<sup>8</sup> Other authors have not stated how long they would observe residual lymphadenopathy before instituting treatment.<sup>6,9</sup> In our department, we wait three months before investigating residual lymphadenopathy.

There is currently no well accepted method for pre-operative determination of the presence of persistent cervical lymph node malignancy. Furthermore, there is little in the literature documenting the efficacy of FNAC or CT in assessing this group of patients. We undertook this study to determine the sensitivity, specificity and diagnostic accuracy of FNAC and CT scanning in positively identifying true persistent nodal disease.

We currently believe that if the CT scan shows pathological lymphadenopathy, the nodal basin should be cleared. However, we routinely perform FNAC of cervical lymphadenopathy in patients with suspected persistent nodal disease. In this clinical setting, we are aware that pre-operative FNAC confirmation of residual nodal disease may not always be possible; firstly, it may not be possible to obtain an adequate cytological specimen, and secondly, the interpretation of the FNAC result may be difficult due to post-irradiation necrosis and neck fibrosis.<sup>8,9</sup> However, FNAC remains the best method of pre-operative cytological diagnosis of cervical lymphadenopathy under these circumstances, and enables better counselling of patients regarding treatment options. For clinically useful FNAC with a definitive result (either positive or negative), we calculated a sensitivity of 25 per cent, a specificity of 100 per cent, a positive predictive value of 100 per cent and a negative predictive value of 42.9 per cent. We also noted that if atypical cells were seen on the FNAC specimen and reported as suspicious but indeterminate or inconclusive, there was a high probability of finding viable tumour cells in the final neck dissection specimen. Three of our four patients whose FNAC was reported as suspicious were found to have positive nodal disease on histological examination of the neck dissection specimen. There are no data in the literature addressing the sensitivity and specificity of FNAC in this clinical setting. There are however some studies addressing the sensitivity and specificity of FNAC in patients with suspected recurrent nodal disease following nasopharyngeal carcinoma treatment, and also comparable data for patients with residual and recurrent disease analysed together. Yen *et al.* reported a sensitivity of 83 per cent for

FNAC performed for 12 patients with suspected recurrent nodal disease.<sup>7</sup> Wei *et al.* found that 20 of 33 FNAC samples from patients with residual and recurrent nodal disease showed malignant cells, while histopathological examination found tumour cells in 45 of 51 patients' neck dissection specimens.<sup>9</sup> In a separate study, we published data on 42 patients presenting with suspected recurrent cervical nodal disease; we found a sensitivity, specificity, positive predictive value and negative predictive value of 75, 75, 93.8 and 37.5 per cent, respectively, for the use of FNAC to identify disease.<sup>12</sup> Rates as low as 57 per cent have been reported for the sensitivity of FNAC to detect recurrent nodal disease.<sup>7</sup> Whether FNAC is needed in the first place, or should be repeated if negative, is controversial. In our department, if the CT scan shows pathological lymphadenopathy we will undertake treatment regardless of the FNAC result.

Computed tomography is an important follow-up tool in the management of patients with residual cervical lymphadenopathy after nasopharyngeal carcinoma treatment, but its utility in identifying true persistent disease may be limited. In our study, although all our 12 patients with residual cervical lymphadenopathy fulfilled the criteria for pathological nodal disease, only seven (58.3 per cent) had positive disease on final examination of neck dissection specimens. A similar result has been reported for patients with recurrent nodal disease. In our previously published study on recurrent nodal disease, CT scanning had a positive predictive value of 78.6 per cent and a negative predictive value of 20 per cent for multilevel lymph node involvement.<sup>12</sup> The final pathological neck dissection specimen showed more nodal involvement than was radiologically evident.<sup>12</sup> These findings mirror reports by other investigators.<sup>6,9,16,17</sup>

High resolution ultrasound (US) is reported to be more sensitive than clinical examination (92 per cent versus 70 per cent) in detecting and differentiating benign from malignant nodes.<sup>18</sup> Furthermore, the specificity of US combined with guided FNAC has been reported to be as high as 92.7 per cent.<sup>19</sup> However, Ahuja and colleagues' study of patients with nasopharyngeal carcinoma found that, for up to three months after radiotherapy, apart from a decrease in node size and the appearance of oedema, other features of previously abnormal nodes (i.e. reflectivity, nodal border, intranodal necrosis and absence of hilus) remained fixed.<sup>20</sup> It was therefore not possible to use any of the features studied to distinguish nodes that might contain residual disease. The same authors stated that US-guided FNAC is not useful after radiotherapy (although FNAC is well documented to significantly increase the specificity of US). Following radiotherapy, it is often more difficult to obtain positive FNAC samples from the neck nodes, and the cytological interpretation of the aspirate is also more difficult. This is particularly true in the early post-treatment period as tumour cells are not uniformly viable. In

our institution, we do not perform US-guided FNAC on such patients.

The reported treatment for residual cervical lymphadenopathy varies from additional boosts of radiotherapy, through excision biopsy with post-operative irradiation if specimens are positive for persistent disease, to radical neck dissection.<sup>6–9,16,17,21,22</sup> Those authors who selected radical neck dissection as the surgical treatment for residual cervical lymphadenopathy did so based on pathological studies which found that, in cases of persistent and recurrent nodal disease, more tumour-harboring lymph nodes were detected in the final neck dissection specimen than in prior clinical or radiological examinations.<sup>6–9,16,17,22</sup>

These same pathological studies also found extracapsular and isolated tumour cell clusters in the neck dissection specimens.<sup>6–9,16,17,22</sup> Our study found greater numbers and more levels of nodal involvement than were clinically or radiologically evident; we also detected the presence of extracapsular spread. Our seven (58.3 per cent) patients with a positive neck dissection had lymph node involvement in more than one level, although their CT scans only showed single level involvement. Two patients had level one nodal involvement, all seven patients had level two nodal involvement and three patients had level three nodal involvement. This finding is consistent with the results of other studies.<sup>6,9,16–17</sup>

- **Patients with nasopharyngeal carcinoma who undergo definitive treatment to the primary site and regional lymph nodes may still have residual cervical lymphadenopathy**
- **Such cervical lymphadenopathy may not represent persistent disease**
- **In the same patient group, nodal necrosis seen on computed tomography may also not represent persistent disease**
- **If such patients are scheduled to undergo radical neck dissection, they should be counselled pre-operatively regarding the possibility of a negative result**

The role of positron emission tomography (PET) in detecting persistent disease is controversial, and this imaging modality has yet to become the standard of care because of its prohibitive cost.<sup>23,24</sup>

While the efficacy and safety of radical neck dissection in treating this group of patients is well documented, such surgery may be unnecessary for those without proven disease. Our study found that five of our 12 patients with persistent cervical lymphadenopathy may not need a full radical neck dissection. Therefore, we propose that patients who present with residual cervical lymphadenopathy after curative radiotherapy or concurrent chemoradiation of nasopharyngeal carcinoma, and whose FNAC is negative or

suspicious, should undergo an excision biopsy with intra-operative frozen section, and should proceed to neck dissection if tumour cells are found.<sup>13</sup> In the irradiated neck, it is generally recommended to avoid pre-operative open biopsies as there is a direct correlation between wound edge necrosis and pre-operative open biopsy.<sup>6</sup> Alternatively, patients could undergo a PET scan. If the PET scan shows residual disease, the patient should undergo radical neck dissection. However, if the PET scan shows no residual disease, the surgeon may elect either to follow the patient closely, or to perform an excision biopsy with intra-operative frozen section and then proceed to radical neck dissection if the frozen section shows viable tumour cells. The role of PET scanning and excision biopsy in this clinical situation needs further study.

The present study was conducted on patients with nasopharyngeal carcinoma who had undergone curative radiotherapy or chemoradiotherapy but who had suspected persistent cervical nodal disease. Therefore, our reported CT, FNAC and final dissection specimen findings relate only to these 12 patients. The role of FNAC and CT in the evaluation of patients who have received neck radiotherapy for other head and neck cancers should be assessed separately.

## Conclusion

Residual cervical lymphadenopathy persisting after curative treatment of nasopharyngeal carcinoma is a challenging clinical problem for the head and neck surgeon. While the efficacy of radical neck dissection is well documented, it may not be necessary in all such patients. Our study found that 41.7 per cent of such patients did not harbour viable tumour cells. In the absence of a diagnostic investigation proven to identify persistent nodal disease, our patients were treated with radical neck dissection. Our study showed that FNAC has good specificity and a high positive predictive value but a poor negative predictive value for identification of disease. Computed tomography was highly sensitive but had a poor positive predictive value. We recommend that head and neck surgeons consider a PET scan or an excision biopsy with intra-operative frozen section to confirm the presence of disease, before proceeding with neck dissection. Patients should be counselled on the possibility of a negative neck dissection.

## References

- 1 Seow A, Koh WP, Chia KS, Shi LM, Lee HP, Shanmugaratnam K. *Trends in Cancer Incidence in Singapore 1998–2002. Report No. 6.* Singapore Cancer Registry, 2004
- 2 Heng DM, Wee J, Fong KW, Lian LG, Sethi VK, Chua ET *et al.* Prognostic factors in 677 patients in Singapore with nondisseminated nasopharyngeal carcinoma. *Cancer* 1999;**86**:1912–20
- 3 Lee AW, Law SC, Foo W, Poon YF, Cheung FK, Chan DK *et al.* Retrospective analysis of patients with nasopharyngeal carcinoma treated during 1976–1985: survival after local recurrence. *Int J Radiat Oncol Biol Phys* 1993;**26**:773–82
- 4 Al-Sarraf M, Leblanc M, Giri PG, Fu KK, Cooper J, Vuong T *et al.* Chemoradiotherapy versus radiotherapy in patients with

- advanced nasopharyngeal cancer: phase III randomised Intergroup study 0099. *J Clin Oncol* 1998;**16**:1310–17
- 5 Wee J, Tan EH, Tai BC, Wong HB, Leong SS, Tan T *et al*. Randomized trial of radiotherapy versus concurrent chemoradiotherapy followed by adjuvant chemotherapy in patients with American Joint Committee On Cancer/International Union Against Cancer stage III and IV nasopharyngeal cancer of the endemic variety. *J Clin Oncol* 2005;**23**:6730–8
  - 6 Ho CM, Wei W, Sham JS, Lau SK, Lam KH. Radical neck dissection in nasopharyngeal carcinoma. *Aust N Z J Surg* 1991;**61**: 898–902
  - 7 Yen KL, Hsu LP, Sheen TS, Chang YL, Hsu MH. Salvage neck dissection for cervical recurrence of nasopharyngeal carcinoma. *Arch Otolaryngol Head Neck Surg* 1997;**123**:725–9
  - 8 Wei WI, Wai KH, Cheng ACK, Wu X, Li GK, Nicholls J *et al*. Management of extensive cervical nodal metastasis in nasopharyngeal carcinoma after radiotherapy: a clinicopathological study. *Arch Otolaryngol Head Neck Surg* 2001;**127**:1457–62
  - 9 Wei WI, Lam KH, Ho CM, Sham JS, Lau SK. Efficacy of radical neck dissection for the control of cervical metastasis after radiotherapy for nasopharyngeal carcinoma. *Am J Surg* 1990;**160**:439–42
  - 10 Chen KY, Fletcher GH. Malignant tumors of the nasopharynx. *Radiology* 1971;**99**:165–71
  - 11 Perez CA, Ackerman LV, Mill WB, Ogura JH, Powers WE. Cancer of the nasopharynx: factors influencing prognosis. *Cancer* 1969;**24**:1–17
  - 12 Toh ST, Yuen HW, Goh YH, Goh CH. Evaluation of recurrent nodal disease after definitive radiation therapy for nasopharyngeal carcinoma: diagnostic value of fine-needle aspiration cytology and CT scan. *Head Neck* 2007;**29**:370–7
  - 13 Brown JJ, Fee WJ. Management of the neck in nasopharyngeal carcinoma. *Otolaryngol Clin North Am* 1998;**31**:785–802
  - 14 van den Brekel MW, Stel HV, Castelijns JA, Nauta JJ, van der Waal I, Valk J *et al*. Cervical lymph node metastasis: assessment of radiological criteria. *Radiology* 1990;**177**:379–84
  - 15 Zhang EP, Liang PG, Li ZQ, Cai GL, Chen YF, Cai MD *et al*. Radiation therapy of nasopharyngeal carcinoma: prognostic factors based on a 10-year follow-up of 1302 patients. *Int J Radiat Oncol Biol Phys* 1989;**16**:301–5
  - 16 Ho YH, Chan M, Tsao SY, Li AK. Treatment of residual and recurrent cervical metastasis from nasopharyngeal carcinoma. *Ann Acad Med Singapore* 1988;**17**:22–4
  - 17 Wei WI, Ho CM, Wong MP, Ng WF, Lau SK, Lam KH. Pathological basis of surgery in the management of post-radiotherapy cervical metastasis in nasopharyngeal carcinoma. *Arch Otolaryngol Head Neck Surg* 1992;**118**:923–9
  - 18 Bruneton JN, Roux P, Caramella E, Demard F, Vallicioni J, Chauvel P. Ear, nose, and throat cancer: ultrasound diagnosis of metastasis to cervical nodes. *Radiology* 1984;**152**:771–3
  - 19 Baatenberg de Jong RJ, Rongen RJ, De Jong PC, Lameris JS, Harthoorn M, Verwoerd CD *et al*. Metastatic neck disease: palpation vs ultrasound examination. *Arch Otolaryngol Head Neck Surg* 1989;**115**:689–90
  - 20 Ahuja A, Yim M, Leung SF, Metreweli C. The sonographic appearance and significance of cervical metastatic nodes following radiotherapy for nasopharyngeal carcinoma. *Clin Radiol* 1996;**51**:698–701
  - 21 Tu GY, Hu YH, Xu GZ, Ye M. Salvage surgery for nasopharyngeal carcinoma. *Arch Otolaryngol Head Neck Surg* 1988;**114**: 328–9
  - 22 Yan JH, Hu YH, Gu XZ. Radiotherapy for recurrent nasopharyngeal carcinoma: report on 219 patients. *Acta Radiol* 1983;**22**:23–8
  - 23 Yen RF, Hong RL, Tzen KY, Pan MH, Chen TH. Whole-body 18F-FDG PET in recurrent or metastatic nasopharyngeal carcinoma. *J Nucl Med* 2005;**46**:770–4
  - 24 Ng SH, Joseph CT, Chan SC, Ko SF, Wang HM, Liao CT *et al*. Clinical usefulness of 18F-FDG in nasopharyngeal carcinoma patients with questionable MRI findings for recurrence. *J Nucl Med* 2004;**45**:1669–76

## Address for correspondence:

Dr Song-Tar Toh,  
Department of Otolaryngology – Head and Neck Surgery,  
Singapore General Hospital,  
Outram Road, Singapore 169608,  
Republic of Singapore

Fax: (65) 62262079  
E-mail: songtar@gmail.com

---

Dr S-T Toh takes responsibility for the integrity of the content of the paper  
Competing interests: None declared

---