

Images

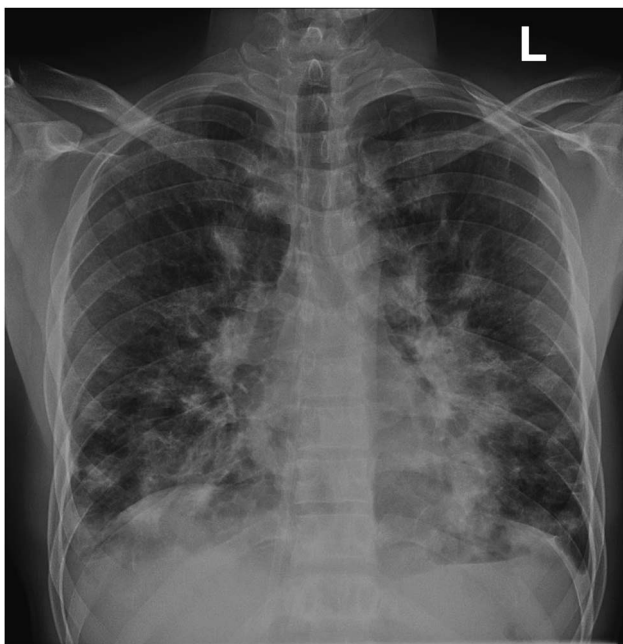
# Pulmonary Kaposi Sarcoma

Michael Gottlieb, MD\*

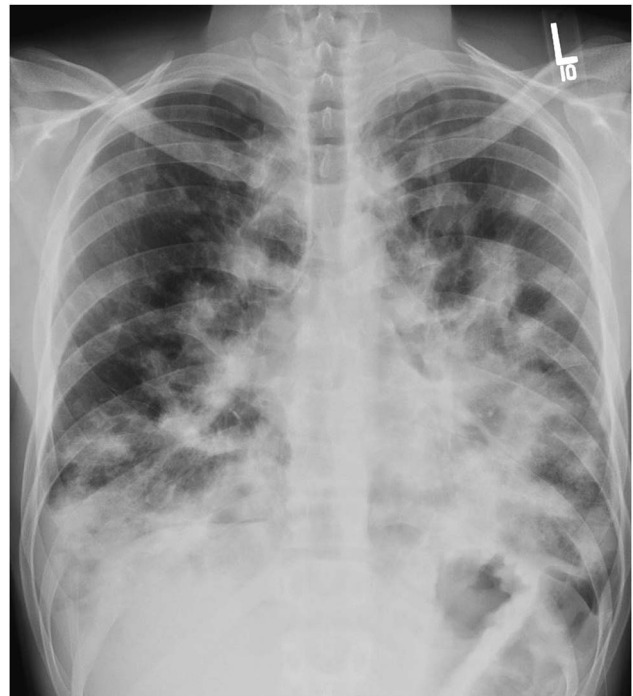A 30-year-old male with a past medical history of human immunodeficiency virus (HIV) infection presented with fever and worsening dyspnea on exertion for the past month. He had been admitted one month prior for suspected *Pneumocystis jiroveci* pneumonia (Figure 1), at which time his CD4 count was found to be 20 cells/cubic mm with a viral load of 28,583. He was admitted for four days and discharged on trimethoprim/sulfamethoxazole, as well as antiretroviral medications. Since discharge, his symptoms had continued to worsen, prompting his return visit. On presentation, his vital signs were notable for an oxygen saturation of 90% on room air, but were otherwise within normal limits. On examination, he appeared cachectic with oral

thrush, diffuse coarse rales on pulmonary examination, and multiple small, dark brown lesions on his right shoulder and left knee. A chest radiograph was repeated (Figure 2), demonstrating worsening opacities, and he was admitted for further evaluation. He underwent both skin and bronchoscopic biopsy and was ultimately diagnosed with pulmonary and dermatologic Kaposi sarcoma. He was treated with liposomal doxorubicin and discharged after one week. At his one-month follow-up visit, he endorsed significant improvement in his symptoms and had an improved chest radiograph.

Kaposi sarcoma (KS) is a spindle-cell tumor with a variable course ranging from small mucocutaneous



**Figure 1.** Initial chest radiograph.



**Figure 2.** Subsequent chest radiograph demonstrating worsening opacities.

From the \*Department of Emergency Medicine, Cook County (Stroger) Hospital, Chicago, IL.

**Correspondence to:** Michael Gottlieb, Cook County (Stroger) Hospital, Department of Emergency Medicine, 1900 W. Polk St., 10th Floor, Chicago, IL, 60612; Email: mgottlieb2@cookcountyhhs.org

lesions to extensive, multi-organ involvement.<sup>1,2</sup> HIV-related KS tends to have an aggressive clinical course and is the most common presentation of KS.<sup>1,2</sup> KS should be considered in HIV-infected patients with low CD4 counts with any prolonged history of dermatologic lesions. Additionally, pulmonary KS should be considered in patients with worsening opacities on chest radiographs despite proper anti-infectious treatment, especially in the context of concomitant skin lesions. Treatment consists of resumption of antiretroviral therapy and chemotherapy with intravenous liposomal doxorubicin.<sup>1,3</sup>

**Competing interests:** None to declare.

**Keywords:** Kaposi's Sarcoma, Pulmonary, HIV, AIDS, Human Immunodeficiency Virus, Acquired Immune Deficiency Syndrome

## REFERENCES

1. Giffin L, Damania B. KSHV: pathways to tumorigenesis and persistent infection. *Adv Virus Res* 2014;88:111-59.
2. Ruocco E, Ruocco V, Tornesello ML, et al. Kaposi's sarcoma: etiology and pathogenesis, inducing factors, causal associations, and treatments: facts and controversies. *Clin Dermatol* 2013;31(4):413-22.
3. Gbabe OF, Okwundu CI, Dedicoat M, et al. Treatment of severe or progressive Kaposi's sarcoma in HIV-infected adults. *Cochrane Database Syst Rev* 2014;9: CD003256.