

Images in Congenital Cardiac Disease

Cite this article: Bichali S, Maltezeanu A, and Houeijeh A (2024) Aberrant right subclavian artery stenting and embolisation for button battery-induced recurrent arterio-oesophageal fistula. *Cardiology in the Young* 34: 2231–2232. doi: 10.1017/S1047951124025691

Received: 22 February 2024
 Revised: 2 May 2024
 Accepted: 6 June 2024
 First published online: 26 September 2024

Keywords:
 CHD; vascular fistula; foreign body; paediatrics; arteria lusoria; survival

Corresponding author:
 Saïd Bichali; Email: said_b91@hotmail.fr

Aberrant right subclavian artery stenting and embolisation for button battery-induced recurrent arterio-oesophageal fistula

Saïd Bichali¹ , Alix Maltezeanu² and Ali Houeijeh¹

¹CHU de Lille, Paediatric Cardiology, Lille, Hauts-de-France, France and ²CHU de Lille, Paediatric Otolaryngology and Surgery, Lille, Hauts-de-France, France

Abstract

A young child, who had a previously unsuspected aberrant right subclavian retro-oesophageal artery, swallowed a button battery complicated with recurrent life-threatening bleeding, and survived after repeated percutaneous treatment as a bridge to surgery.

A 25-month-old girl ingested a button battery, discovered one week later upon haemorrhagic shock. Post-intubation chest X-ray revealed a button battery at the oesophageal upper third. CT scan unveiled an aberrant right subclavian retro-oesophageal artery (arteria lusoria), and angiography showed contrast extravasation. The right subclavian artery was successfully stented using three pre-mounted covered stents (BeGraft 5*28, 5*22, and 6*22 mm, Bentley InnoMed, Germany) (Figure 1a). The button battery was extracted endoscopically, and a

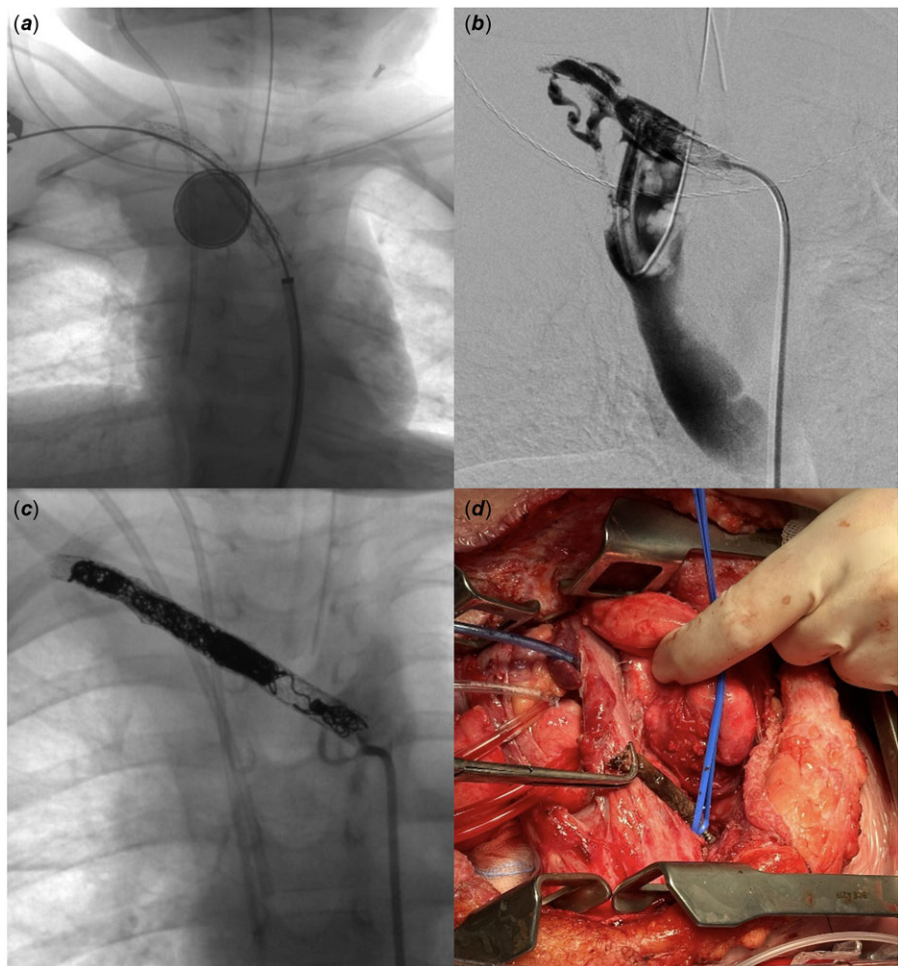


Figure 1. Anteroposterior projection right after the first stenting of the aberrant right subclavian artery showing the 20-mm button battery still inside the oesophagus (a), 20°-right-anterior-oblique digital subtraction angiography revealing extensive contrast medium extravasation into the oesophagus where air bubbles can be seen (b), anteroposterior projection after multiple coil embolisation of the right subclavian artery without residual fistula (c), and surgical view by clamshell thoracotomy depicting the extraction of the stented necrosed right subclavian artery (d).

© The Author(s), 2024. Published by Cambridge University Press.

pleuro-oesophageal fistula was drained and washed surgically. Three months later, haematemesis and shock reoccurred due to vascular and stent wall destruction in the setting of fungal mediastinitis. Two 6*58 and 6*15 mm BeGraft covered stents were deployed (Figure 1b) by axillary and femoral arteries complex approach, complicated with left lower limb ischaemia treated by surgical revascularisation and aponeurotomy. After three days, the oesophagus was surgically excluded. Three months later, bleeding reoccurred from the gastrostomy feeding tube. The right subclavian artery was completely occluded with 16 coils (AZUR, Terumo, New Jersey) to stop the bleeding for a few days (Figure 1c). After 10 days, the material was extracted and the aorta required repair with bovine pericardium (Figure 1d). At a six-month follow-up, the child was doing well at home with motor rehabilitation.

An aberrant right subclavian artery in the vicinity of the oesophagus may make foreign body obstruction more likely, and in the setting of button battery, ingestion could prove to be fatal. The aorta can be involved and successfully treated percutaneously before surgery.¹ Subclavian repeated rescue endovascular treatment can also be effective.

Data availability statement. The data underlying this article are available upon reasonable request to the corresponding author.

Acknowledgements. The authors thank Estelle Aubry, Pierre Fayoux, Michel Bonnevalle, Francis Juthier, Jerome Soquet, Francois Dubos, Fanny Vuotto, Anne Laffargue, Jean-Marie Renard, Julien Corouge, Martin Dubernet, Marie Canavese, Dina Bert, Serge Dalmas, Francois Lion, Perpetue De Souza, Gaëlle Delmotte, Caroline Petyt, Juliette Godart, Lois Henry, Rémi Besson, Stéphanie

Delangue, Morgan Recher, Camille Guillot, Sylvain Balandier, Jérémie Rousseaux, Marguerite Lockhart, Stéphane Leteurtre, Jean Roux, Pierre-Alexandre Fontanges, Dominique Guimber, Madeleine Aumar, Clémence Saingier, Léa Tran, Hélène Broucqsault, Damien Fron, Aline Bishop, René-Hilaire Priso, Rony Sfeir, Dyuti Sharma, Céline Rougraff, Arthur Lauriot Dit Prévost, Armande Subayi, Héloïse Lérison, Mohamed El Fayoumi, Benjamin Longère, Marianne Lejeune, Caroline Degrugillier-Chopinnet, Mathis Meyssonier, Maxime Lebaz-Dubosq, Richard Azzaoui, Clément Jeanneau, and the whole teams who took part in patient care.

Authors' contribution. The first draft of the manuscript was written by Saïd Bichali. All authors read and approved the final manuscript.

Financial support. This research received no specific grant from any funding agency, commercial or not-for-profit sectors.

Competing interests. None.

Ethical standards. All procedures performed in studies involving human participants were in accordance with the ethical standards of the institutional and/or national research committee and with the 1964 Helsinki Declaration and its later amendments or comparable ethical standards. Informed written consent to participate and publish was obtained from the patient legal guardians.

Reference

1. Alreheili KM, Almutairi M, Alsaadi A, Ahmed G, Alhejili A, AlKhatrawi T. A 2-year-old boy who developed an aorto-oesophageal fistula after swallowing a button battery, managed using a novel procedure with vascular plug device as a bridge to definitive surgical repair. *Am J Case Rep* 2021; 22: e931013.