

## Original Article

**Cite this article:** Esmel-Vilomara R, Dolader P, Melendo S, Rosés-Noguer F, and Gran F (2025) High specificity electrocardiogram patterns for parvovirus B19 myocarditis in children: bridging electrocardiogram findings to aetiological diagnosis. *Cardiology in the Young* 35: 1023–1027. doi: [10.1017/S1047951125001878](https://doi.org/10.1017/S1047951125001878)

Received: 18 January 2025  
Revised: 30 January 2025  
Accepted: 25 March 2025  
First published online: 8 May 2025






### Keywords:

Myocarditis; parvovirus B19; electrocardiogram; heart failure; cardiogenic shock

### Corresponding author:

Roger Esmel-Vilomara;  
Email: [roger.esmel@uab.cat](mailto:roger.esmel@uab.cat)

# High specificity electrocardiogram patterns for parvovirus B19 myocarditis in children: bridging electrocardiogram findings to aetiological diagnosis

Roger Esmel-Vilomara<sup>1,2,3</sup> , Paola Dolader<sup>1,2</sup> , Susana Melendo<sup>1,4</sup> , Ferran Rosés-Noguer<sup>1,2</sup>  and Ferran Gran<sup>1,2</sup> 

<sup>1</sup>Faculty of Medicine, Universitat Autònoma de Barcelona, Barcelona, Spain; <sup>2</sup>Paediatric Cardiology, Vall d'Hebron Hospital Campus, Barcelona, Spain; <sup>3</sup>Paediatric Cardiology, Hospital de la Santa Creu i Sant Pau, Institut de Recerca Sant Pau (IR-Sant Pau), Barcelona, Spain and <sup>4</sup>Paediatric Infectious Diseases and Immunodeficiencies, Vall d'Hebron Hospital Campus, Barcelona, Spain

## Abstract

**Introduction:** Parvovirus B19 (PVB19) myocarditis is a life-threatening condition with high morbidity and mortality in children. While electrocardiograms are commonly used in the early assessment of myocarditis, no specific electrocardiogram pattern has been consistently linked to PVB19. The objective of this study is to identify a distinctive electrocardiogram pattern associated with PVB19 myocarditis and evaluate its diagnostic accuracy. **Methods:** This retrospective case-control study included 77 paediatric patients diagnosed with acute myocarditis at a single centre in Barcelona over 16 years (August 2008–September 2024). Twenty patients had PVB19 myocarditis, confirmed by polymerase chain reaction in blood or endomyocardial biopsy, while 57 patients had myocarditis caused by other viruses. Electrocardiogram were assessed by three cardiologists blinded to the aetiological diagnosis. **Results:** A specific electrocardiogram pattern in the limb leads, characterised by peaked P waves, low QRS complex voltages, and altered repolarisation (manifesting as negative or flat T waves, with or without QTc prolongation), was observed in 14 of 20 patients (70%) with PVB19 myocarditis. Two additional patients exhibited low voltages and altered repolarisation without peaked P waves, and all demonstrated repolarisation abnormalities. In contrast, only 1 of 57 patients with myocarditis from other viruses exhibited the full electrocardiogram pattern. The pattern demonstrated a specificity of 98% and a sensitivity of 70% for PVB19 myocarditis. **Conclusion:** The identified electrocardiogram pattern shows strong diagnostic specificity for PVB19 myocarditis in paediatric patients and may serve as a useful early diagnostic tool. Further multicentre studies are needed to confirm these findings and explore their clinical implications.

## Introduction

Myocarditis is an inflammatory disease of the heart primarily caused by viral infections.<sup>1,2</sup> Its incidence is estimated at 10 to 20 cases per 100,000 individuals, and it represents a significant cause of morbidity and mortality in children.<sup>2–4</sup> Among the responsible viral agents, Parvovirus B19 (PVB19) has emerged as the leading cause in the paediatric population.<sup>4–6</sup> Nonetheless, a limited number of published series focuses specifically on PVB19 myocarditis in children.<sup>5,7,8</sup>

The clinical presentation of myocarditis varies widely, from asymptomatic forms to life-threatening conditions such as cardiogenic shock or sudden cardiac death.<sup>1–3</sup> This nonspecific clinical presentation increases the risk of misdiagnosis or delays in diagnosis, which can delay the initiation of treatment and negatively impact survival chances.<sup>4,9</sup>

The electrocardiogram is a readily available, low-cost diagnostic tool frequently utilised initial assessment of suspected myocarditis.<sup>1,3,9,10</sup> Although electrocardiogram abnormalities are found in nearly all children with myocarditis, no distinctive electrocardiographic changes can definitively diagnose the condition, and the test has limited sensitivity and specificity.<sup>9–11</sup>

This study aims to evaluate the electrocardiogram changes in paediatric patients with PVB19 myocarditis and determine whether a specific electrocardiogram pattern is associated with PVB19.

## Methods

We performed a retrospective case control study including 77 consecutive paediatric patients diagnosed with acute myocarditis in a single centre in Barcelona over 16 years (August 2008 to September 2024). Inclusion criteria required a diagnostic confirmation by endomyocardial

© The Author(s), 2025. Published by Cambridge University Press. This is an Open Access article, distributed under the terms of the Creative Commons Attribution licence (<https://creativecommons.org/licenses/by/4.0/>), which permits unrestricted re-use, distribution and reproduction, provided the original article is properly cited.



biopsy or cardiac MRI, with the myocarditis viral aetiology confirmed by polymerase chain reaction testing on endomyocardial biopsy or blood samples. Twenty patients were attributed to PVB19 (Group A), whereas the other 57 were caused by other viruses (Group B).

Demographics, initial presentation, severity of illness, aetiology, echocardiographic assessment, and electrocardiogram analysis were studied for both groups. Standard 12-lead electrocardiograms upon admission were evaluated by three cardiologists who were blinded to the aetiological diagnosis and Group A and B electrocardiogram were compared.

Statistical analysis was conducted using SPSS for Windows version 25.0 (Armonk, NY, USA: IBM Corp.). Categorical data were described using proportions, while quantitative continuous data were expressed as medians with interquartile ranges, given the non-normal distribution of the sample. Comparisons were made using Fisher's exact test for categorical data and the Mann-Whitney *U* test for continuous variables.

Ethical approval for this study was granted by the local ethics committee, ensuring compliance with ethical standards and the protection of participants' rights and safety. All activities conducted in this research adhered to the ethical principles outlined in the 1975 Declaration of Helsinki. Informed consent for publication was obtained from the parents of each patient.

## Results

A total of 20 episodes of myocarditis involving 19 patients were identified. The median age was 19 months, and 13 (65%) were male. All patients presented with complicated myocarditis, manifesting either as heart failure, fulminant myocarditis or ventricular tachycardia, and requiring mechanical circulatory support with extracorporeal membrane oxygenation in 7 patients (35%). Detailed epidemiological and clinical data are shown in Table 1.

All patients exhibited abnormal electrocardiogram findings at presentation. Electrocardiogram abnormalities are detailed in Table 1. A specific pattern in the limb leads, characterised by peaked P waves, low QRS voltages and altered repolarisation (manifesting as negative or flat T waves with or without QTc prolongation), was observed in 14 patients (14/20, 70%). Notably, all patients had altered repolarisation (100%). In addition to the 14 patients with the complete pattern, two additional patients showed low voltages and altered repolarisation without peaked P waves.

Figure 1 provides examples of the described electrocardiogram pattern. The presence of more severe myocardial dysfunction ( $p = 0.323$ ) or pericardial effusion ( $p = 0.521$ ) was not associated with the described electrocardiogram pattern or any specific electrocardiogram finding independently.

During the same period, 57 patients with myocarditis not attributable to PVB19 were included, of whom 35 (35/57, 61.4%) presented with complicated myocarditis, including cardiogenic shock or heart failure. Among these patients, only one exhibited the complete electrocardiogram pattern described in the limb leads (1/57, 1.8%). Twenty patients presented an abnormal repolarisation (20/57, 35.1%), ten exhibited low voltages (10/57, 17.5%), and five had peaked P waves (8.8%).

These findings suggest that the described electrocardiogram pattern is significantly associated with PVB19 myocarditis ( $p < 0.001$ ), showing a specificity of 98% and a sensitivity of 70% for identifying PVB19 in patients with myocarditis.

## Discussion

Electrocardiogram is universally recommended as a first-line investigation for patients with suspected myocarditis.<sup>1,2</sup> Numerous retrospective studies have demonstrated that electrocardiogram abnormalities are detected in nearly all patients,<sup>9,11</sup> although some studies report a subset of patients with normal electrocardiogram findings.<sup>10</sup> However, the potential association between specific electrocardiogram patterns and a particular causative agent has not yet been studied, particularly in paediatric populations where research is limited, and sample sizes are smaller. This study is the first to present an electrocardiogram pattern that could potentially help identify PVB19 as the underlying cause of myocarditis in paediatric patients.

Previous studies examining electrocardiogram alterations during acute myocarditis have identified sinus tachycardia and repolarisation abnormalities, particularly T-wave inversion, as the most common electrocardiogram findings.<sup>9,11</sup> In our study, repolarisation abnormalities were observed in all patients with PVB19 myocarditis, compared to 35.1% of patients with myocarditis caused by other virus. Repolarisation abnormalities have been reported in patients with myocarditis of varying severity, from non-complicated to fulminant myocarditis, with a prevalence ranging from 9 to 48%.<sup>9,11,12</sup>

The pathogenic link between myocardial oedema and repolarisation abnormalities remains to be fully elucidated. However, it has been proposed that regional or transmural myocyte repolarisation inhomogeneity secondary to the inflammatory process could be responsible.<sup>9,12</sup> In this context, T-wave inversion may result from inflammatory or fibrotic infiltration beginning in the subepicardium, where depolarisation and repolarisation become more delayed compared to the subendocardium, leading to a transmural repolarisation gradient.<sup>13</sup> In line with this hypothesis, T-wave inversion has been independently associated with the extent of myocardial necrosis and oedema detected by MRI, with transmural oedema distribution strongly correlated with the location of T-wave inversion.<sup>12</sup>

Low QRS voltages were observed in 16 of our patients (16/20, 80%), a finding traditionally associated with pericardial effusion or extracardiac conditions such as obesity or emphysema.<sup>13</sup> However, low QRS voltages have also been documented in myocarditis independent of pericardial effusion,<sup>11</sup> a finding confirmed by this study. The proposed mechanisms for low QRS voltages in this setting include expansion of extracellular spaces by oedema and fibrosis in the ventricular wall. Pulmonary or peripheral oedema can also contribute to reducing voltage amplitude by increasing impedance to electrical conduction.<sup>9</sup> In cardiomyopathies, low QRS voltages are observed in 3–6% of patients with dilated cardiomyopathy and in up to 41% of patients with certain forms of non-dilated left ventricular cardiomyopathy.<sup>13</sup> The markedly higher prevalence of low voltages in PVB19 myocarditis in our cohort (80%) highlights the relevance of this electrocardiogram finding in this specific aetiology.

Additionally, peaked p waves on electrocardiograms, which indicate increased atrial pressures, are often a consequence of heart failure. Concurrently, myocardial oedema can further diminish ventricular compliance, exacerbating atrial pressure by creating a restrictive filling pattern and diastolic dysfunction. The impaired ventricular contraction and relaxation can also lead to atrio-ventricular valve regurgitation, further exacerbating atrial volume overload and pressure elevation.<sup>13</sup>

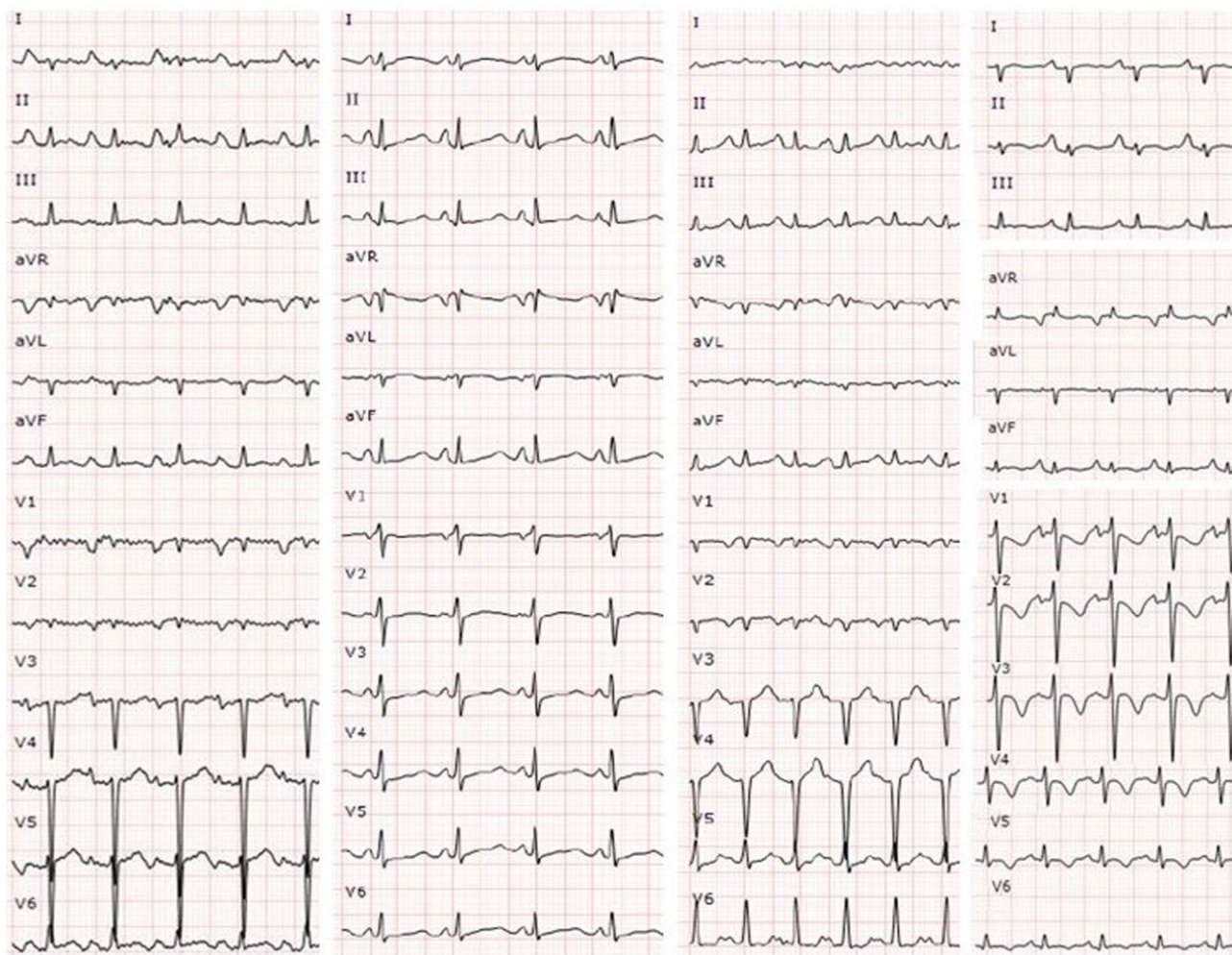
**Table 1.** Demographic information, clinical presentation, and electrocardiographic abnormalities upon presentation. Categorical data is presented as *n* (%) and continuous variables as median and interquartile ranges (IQR)

Clinical presentation	Group A (PVB19) <i>n</i> =20 episodes	Group B (other viruses) <i>n</i> =57 episodes
Demographics		
Male	13 (65%)	32 (56.1%)
Age in months at presentation (median, IQR)	19 (16.25)	99 (148)
Initial clinical presentation		
Cardiogenic shock	10 (50%)	23 (40.4%)
Heart failure	9 (45%)	10 (17.5%)
Chest pain	0 (0%)	22 (38.6%)
Arrhythmias	1 (5%)	2 (3.5%)
Severity of illness		
Intensive care unit admission	20 (100%)	40 (70.1%)
Mechanical ventilation	15 (75%)	28 (49%)
Inotropic agents	20 (100%)	35 (61.4%)
Mechanical circulatory assist devices	7 (35%)	11 (19.3%)
Echocardiographic assessment		
Left ventricular ejection fraction (median, IQR)	25 (7)	35 (35)
Left ventricular dilatation	20 (100%)	26 (45.6)
Left ventricle hypertrophy	10 (50%)	15 (26.3%)
Left atrium dilatation	20 (100%)	24 (42.1%)
Mitral regurgitation (moderate to severe)	14 (70%)	18 (31.6%)
Right ventricular dysfunction	6 (30%)	15 (26.3%)
Pericardial effusion	2 (10%)	5 (8.8%)
Microbiological diagnosis (PVB19 PCR)		
Endomyocardial biopsy	16 (80%)	2 (3.5%)
Blood	19 (95%)	14 (24.6%)
Electrocardiographic abnormalities		
Peaked P waves	14 (70%)	5 (8.8%)
Q waves	1 (5%)	10 (17.5%)
Low QRS voltages	16 (80%)	10 (17.5%)
Wide QRS complex	2 (10%)	8 (14.0%)
ST elevation	2 (10%)	25 (43.9%)
Altered repolarisation	20 (100%)	20 (35.1)

PVB19 PCR, parvovirus B19 polymerase chain reaction.

Although electrocardiogram is widely used for the early screening of myocarditis,<sup>1,3,10</sup> its sensitivity and specificity for diagnosing myocarditis remain low.<sup>2,9,10</sup> However, once myocarditis is suspected, the presence of this specific electrocardiogram pattern in the limb leads (characterised by peaked p waves, low QRS voltages and abnormal repolarisation) should prompt consideration of PVB19 as the likely cause, with a specificity of 98%. The sensitivity of this pattern, while lower at 70%, is still noteworthy. These findings could have significant clinical implications, not only guiding the selection of appropriate diagnostic tests but also influencing therapeutic decisions.

In particular, recent studies have proposed that immunosuppressive treatment, potentially combined with interferon-beta to suppress active PVB19 transcription in the myocardium, might offer an effective strategy for managing PVB19 myocarditis.<sup>4,5,14</sup> However, in the absence of definitive evidence, targeted immunosuppressive or antiviral therapy should not be initiated based solely on electrocardiogram findings without microbiological confirmation. While early empirical immunomodulatory treatment with corticosteroids may be considered in critically ill patients with cardiogenic shock or severe systolic dysfunction, particularly if this characteristic electrocardiogram pattern is present, this approach remains untested in clinical trials.<sup>2,14</sup>



**Figure 1.** Examples of the PVB19 ECG pattern presented in the limb leads: peaked p waves, low QRS voltages, and repolarisation abnormalities (manifested as negative or flat T waves).

Current guidelines do not provide specific recommendations for empiric immunosuppression in acute myocarditis beyond standard heart failure management.<sup>1,3</sup>

Beyond specialised centres where endomyocardial biopsy is routinely available, this electrocardiogram pattern could serve as a practical and widely accessible tool to aid in the early identification and risk stratification of paediatric myocarditis, particularly in resource-limited settings where advanced diagnostic tools as endomyocardial biopsy or cardiac MRI are not readily available. If validated in larger multicentre studies, its application could contribute to earlier clinical suspicion, optimised diagnostic workflows, and potentially improved patient outcomes.

The primary limitation of this study is its single-centre design, which may impact the generalisability of the findings. Additionally, the small sample size of 20 patients with PVB19 myocarditis, due to the rarity of the disease, restricts the robustness of the conclusions. To validate these results and enhance clinical applicability, future prospective multicentre studies with larger, well-characterised cohorts are needed. These studies should aim to confirm the specificity and sensitivity of this electrocardiogram pattern and assess its predictive value in clinical decision-making. Furthermore, expanding the number of centres and patients

would facilitate an evaluation of interobserver agreement, ensuring consistent electrocardiogram interpretation in routine practice.

## Conclusion

This study identifies a specific electrocardiogram pattern associated with PVB19 myocarditis in paediatric patients, characterised by peaked P waves, low QRS voltages, and abnormal repolarisation. This pattern demonstrates a high specificity (98%) for PVB19 myocarditis and a sensitivity of 70%. These findings can help in distinguishing PVB19 myocarditis from other aetiologies from the first medical evaluation, guiding clinicians towards appropriate diagnostic and therapeutic strategies. To validate these findings, further research involving larger, multicentric cohorts is essential to confirm the pattern's clinical utility and explore its underlying mechanisms.

**Acknowledgements.** None.

**Financial support.** This research received no specific grant from any funding agency, commercial, or not-for-profit sectors.

**Competing interests.** The authors have no conflicts of interest relevant to this article to disclose.

**Ethical standards.** The authors assert that all procedures contributing to this work comply with the ethical standards of the relevant national Spanish guidelines on human experimentation and with the Helsinki Declaration of 1975, as revised in 2008, and has been approved by the Vall d'Hebron Hospital Ethics Committee.

## References

1. Caforio AL, Pankuweit S, Arbustini E, et al. Current state of knowledge on aetiology, diagnosis, management, and therapy of myocarditis: a position statement of the European society of cardiology working group on myocardial and pericardial diseases. *Eur Heart J* 2013; 34: 2636–2648d. doi: [10.1093/eurheartj/ehz210](https://doi.org/10.1093/eurheartj/ehz210).
2. Pomato E, Perrone MA, Palmieri R, Gagliardi MG. Pediatric myocarditis: what have we learnt so far? *J Cardiovasc Dev Dis* 2022; 9: 143. doi: [10.3390/jcdd9050143](https://doi.org/10.3390/jcdd9050143). Published 2022 May 3.
3. Ammirati E, Frigerio M, Adler ED, et al. Management of acute myocarditis and chronic inflammatory cardiomyopathy: an expert consensus document. *Circ Heart Fail* 2020; 13: e007405. doi: [10.1161/CIRCHEARTFAILURE.120.007405](https://doi.org/10.1161/CIRCHEARTFAILURE.120.007405).
4. Krych S, Jęczyński A, Jurkiewicz M, et al. Viral myocarditis as a factor leading to the development of heart failure symptoms, including the role of parvovirus B19 infection-systematic review. *Int J Mol Sci* 2024; 25: 8127. doi: [10.3390/ijms25158127](https://doi.org/10.3390/ijms25158127). Published 2024 Jul 25.
5. Esmel-Vilomara R, Dolader P, Izquierdo-Blasco J, et al. Parvovirus B19 myocarditis in children: a diagnostic and therapeutic approach. *Eur J Pediatr* 2022; 181: 2045–2053. doi: [10.1007/s00431-022-04406-x](https://doi.org/10.1007/s00431-022-04406-x).
6. Verdonchot J, Hazebroek M, Merken J, et al. Relevance of cardiac parvovirus B19 in myocarditis and dilated cardiomyopathy: review of the literature. *Eur J Heart Fail* 2016; 18: 1430–1441. doi: [10.1002/ehf.665](https://doi.org/10.1002/ehf.665).
7. Molina KM, Garcia X, Denfield SW, et al. Parvovirus B19 myocarditis causes significant morbidity and mortality in children. *Pediatr Cardiol* 2013; 34: 390–397. doi: [10.1007/s00246-012-0468-4](https://doi.org/10.1007/s00246-012-0468-4).
8. Vigneswaran TV, Brown JR, Breuer J, Burch M. Parvovirus B19 myocarditis in children: an observational study. *Arch Dis Child* 2016; 101: 177–180. doi: [10.1136/archdischild-2014-308080](https://doi.org/10.1136/archdischild-2014-308080).
9. Buttà C, Zappia L, Laterra G, Roberto M. Diagnostic and prognostic role of electrocardiogram in acute myocarditis: a comprehensive review. *Ann Noninvasive Electrocardiol* 2020; 25: e12726. doi: [10.1111/anec.12726](https://doi.org/10.1111/anec.12726).
10. Pompa AG, Beerman LB, Feingold B, Arora G. Electrocardiogram changes in pediatric patients with myocarditis. *Am J Emerg Med* 2022; 59: 49–53. doi: [10.1016/j.ajem.2022.06.027](https://doi.org/10.1016/j.ajem.2022.06.027).
11. Punja M, Mark DG, McCoy JV, Javan R, Pines JM, Brady W. Electrocardiographic manifestations of cardiac infectious-inflammatory disorders. *Am J Emerg Med* 2010; 28: 364–377. doi: [10.1016/j.ajem.2008.12.017](https://doi.org/10.1016/j.ajem.2008.12.017).
12. De Lazzari M, Zorzi A, Baritussio A, et al. Relationship between T-wave inversion and transmural myocardial edema as evidenced by cardiac magnetic resonance in patients with clinically suspected acute myocarditis: clinical and prognostic implications. *J Electrocardiol* 2016; 49: 587–595. doi: [10.1016/j.jelectrocard.2016.04.002](https://doi.org/10.1016/j.jelectrocard.2016.04.002).
13. Aimò A, Milandri A, Barison A, et al. Electrocardiographic abnormalities in patients with cardiomyopathies. *Heart Fail Rev* 2024; 29: 151–164. doi: [10.1007/s10741-023-10358-7](https://doi.org/10.1007/s10741-023-10358-7).
14. He B, Li X, Li D. Immunosuppressive treatment for myocarditis in the pediatric population: a meta-analysis. *Front Pediatr* 2019; 7: 430. doi: [10.3389/fped.2019.00430](https://doi.org/10.3389/fped.2019.00430).