



# Device closure of residual aortopulmonary window using Konar-MF occluder device: an attractive new option

## Brief Report

**Cite this article:** Qureshi AU, Kazmi T, and Sadiq M (2024) Device closure of residual aortopulmonary window using Konar-MF occluder device: an attractive new option. *Cardiology in the Young* 34: 1597–1599. doi: [10.1017/S1047951124025010](https://doi.org/10.1017/S1047951124025010)



Received: 29 July 2023  
Revised: 7 January 2024  
Accepted: 1 April 2024  
First published online: 22 May 2024

### Keywords:

Device closure; Konar-MF occluder device; Aortopulmonary window

### Corresponding author:

M. Sadiq; Email: [drmasoodsadiq@hotmail.com](mailto:drmasoodsadiq@hotmail.com)

Ahmad Usaid Qureshi , Tehmina Kazmi and Masood Sadiq 

The Children's Hospital, University of Child Health Sciences, Lahore, Pakistan

### Abstract

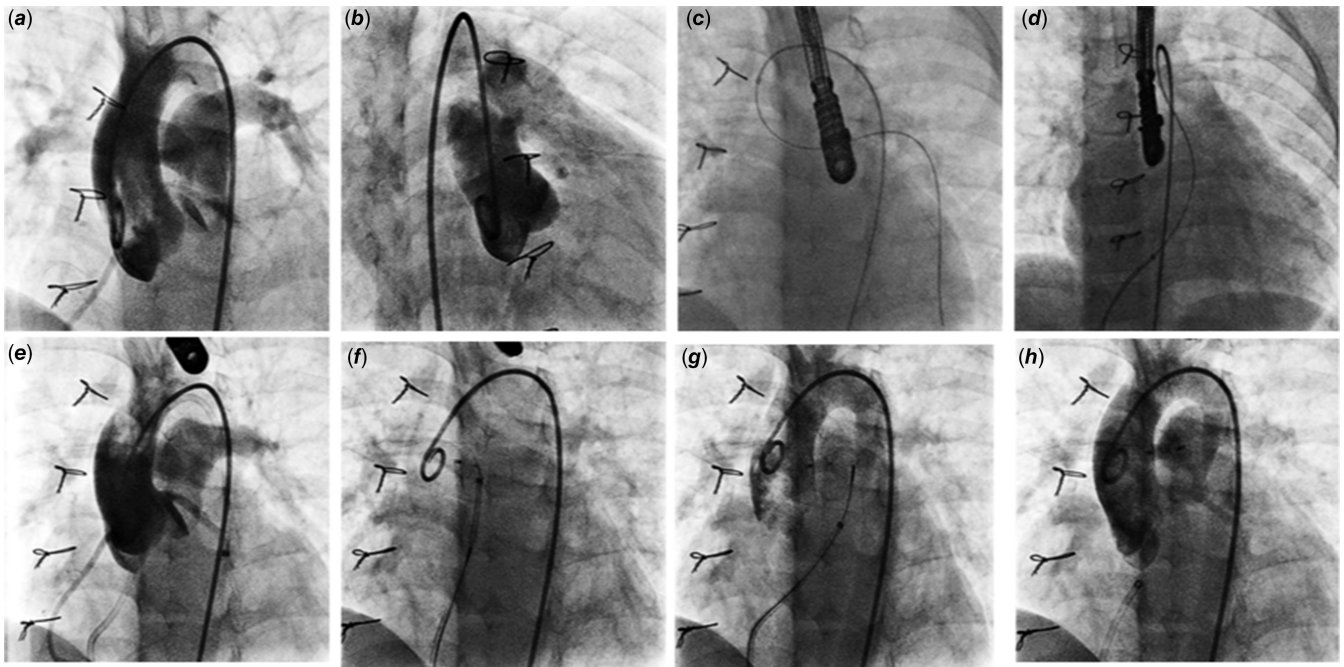
We report a case of a residual aortopulmonary window where a new Konar-MF occluder device was used to close the defect. This device has a low profile and conforms to the anatomy of aortopulmonary window very nicely without unnecessary protrusion on either side. This report highlights the advantage of Konar-MF occluder device for closure of such defects.

Aortopulmonary window is a rare congenital heart defect resulting from malformation of aortopulmonary septum during fetal life.<sup>1</sup> The incidence ranges from 0.05 to 5%.<sup>2</sup> Up till late 1990s, all aortopulmonary window was surgically closed using various techniques. The results have been excellent though there have been infrequent reports of immediate and late residual defect.<sup>2</sup> Re-operation in these patients is cumbersome due to excessive adhesions with additional risk of bleeding or vascular trauma. Since late 1990s, small to moderate native and residual aortopulmonary windows are being closed using various devices through percutaneous transcatheter technique with adequate results.<sup>3–8</sup> We present, here, the first case of a residual aortopulmonary window using a new Konar-MF occluder device with excellent outcome and conformability.

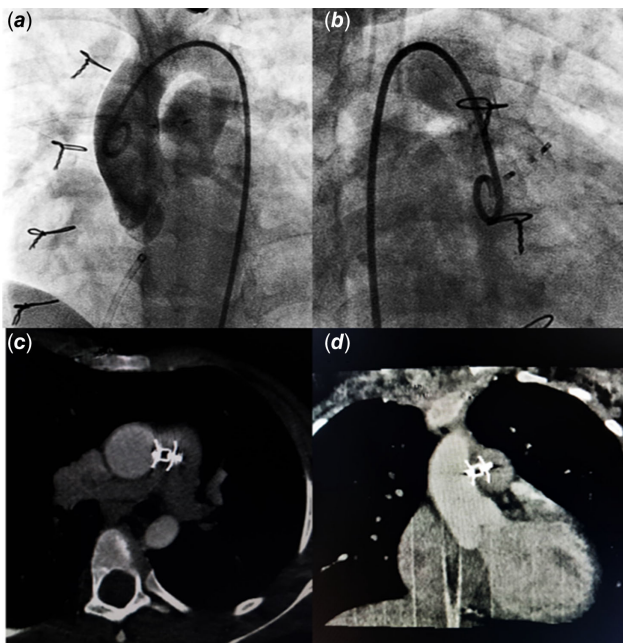
### Case report

A 3-month-old boy presented with heart failure and poor weight gain, and a diagnosis of a large type I aortopulmonary window with severe pulmonary hypertension was made. The defect was surgically corrected using direct ligation technique with smooth post-operative recovery and regression in pulmonary artery pressures. The patient remained well; on follow-up though, he was found to have a small central late residual defect through ligated aortopulmonary window after 9 months. In view of small defect, regressed pulmonary hypertension, and mild left ventricular volume overload, the patient was followed up conservatively.

At 3-year follow-up, the defect was noted to have caused significant left ventricular volume overload with preserved ventricular functions. The defect measured 3–4 mm on echocardiography. The patient was catheterized to delineate the defect, which measured 3.1 mm and 11 mm distal to aortic sinuses in Left Anterior Oblique (LAO)/cranial and Right Anterior Oblique (RAO)/cranial projections (Fig. 1). Haemodynamic assessment showed pulmonary blood flow (Qp):Systemic blood flow (Qs) ratio 2.4:1 with normal pulmonary artery pressures (mean pulmonary artery pressure 18 mmHg). Aortopulmonary window was crossed using a JR4 catheter and a 0.035 exchange length glide wire through aortic end and engaged in distal left pulmonary artery. A 10 mm snare catheter used to snare the wire and railroad was established through right femoral artery. A 7×5 Konar-MF occluder (Lifetech, China) was selected to close the defect. It has a soft woven mesh with a flexible waist primarily designed for perimembranous Ventricular Septal Defect (VSD) closure. It has a double-sided screw for retrograde and antegrade approach and can be delivered through a small delivery sheath. The delivery cable is also slim to avoid untoward damage. Keeping in view, the acute angulation on aortic end entry point, sheath was passed in antegrade fashion. High tensile end was released on aortic side and low tensile end on pulmonary end. The device was released successfully with no residual defect on aortogram (Fig. 2 a, b) or echocardiogram. The flow is seen through the device, which disappeared completely the next day. This relates to the fact that Konar-MF occluder devices up to 8×6 come without a membrane, hence a small delivery sheath (4F, 5F). Sizes 9×7 upwards have a membrane inside the device and would require a relatively large sheath (6F, 7F). The patient was discharged 24 hours after the procedure on aspirin 5 mg/kg daily to be continued for 6 months. Short-term follow-up with repeat transthoracic echocardiogram and cardiac CT at 9 months should demonstrate excellent device profile with no residual leak, no branch pulmonary artery turbulence, and no aortic obstruction (Fig. 2 c, d).



**Figure 1.** *a,b.* Ascending aortogram in LAO and RAO projections showing residual shunt across AP window. *c.* Guide wire snared in LPA. *d.* Arteriovenous railroad established. *e.* Delivery sheath passed across AP window and parked in descending aorta. *f.* Aortic end released. *g.* Pulmonary end deployed. *h.* Final position of device after release. AP = Aortopulmonary; LAO= Left Anterior Oblique; LPA = Left Pulmonary Artery; RAO= Right Anterior Oblique.



**Figure 2.** *a,b.* Post-procedure angiogram. *c,d.* Follow-up CT angiography.

## Discussion

Transcatheter percutaneous occlusion of small to moderate aortopulmonary windows has been done for the last decade with various devices.<sup>3–7</sup> A detailed evaluation of anatomy of the defect is key to decision making firstly whether suitable for device closure or not and then appropriate device selection if deemed suitable for transcatheter closure. Transcatheter closure is considered for isolated defects located away from both semilunar valves and

pulmonary artery bifurcation—the type IV or “intermediate” type in the classification scheme recommended by the Society of Thoracic Surgeons Congenital Heart Surgery Database Committee. Double umbrella-shaped devices are considered more suitable as they provide adequate retention skirts on both sides to prevent device dislodgement. None of the devices, however, conform well to the native anatomy resulting in protrusion of either end into aorta or pulmonary artery.<sup>3–7</sup> Furthermore, ventricular or atrial septal occluders carry the risk of protrusion/encroachment of aortic disc onto aortic sinus or cusps.

Konar-MF occluder is soft with a low profile, capable of deployment using small delivery sheath appropriate for small infants through either arterial or venous side and with liberty of choosing high tensile or low tensile disc release on high-pressure end according to anatomical defect configuration.<sup>8</sup> The follow-up CT has shown that it conforms to the anatomy of the defect with very good apposition on either side. A successful closure of a native large aortopulmonary window with pulmonary hypertension in a 12-month-old girl using a large Konar-MF occluder device (12×10) has recently been reported with a good outcome.<sup>9</sup>

The nitinol device implanted with a disc in ascending aorta might be the cause of thrombosis with the risk of embolization and ischaemic cerebral events. We used aspirin in anti-platelet dose (5 mg/kg) on the day of procedure to be continued for 6 months as recommended in Indian guidelines after the device closure of an aortopulmonary window.<sup>10</sup>

In conclusion, Konar-MF occluder is an excellent new addition to available devices for aortopulmonary window device closure with added adjustability, ease in deployment, and better final profile.

**Financial support.** None.

**Competing interests.** None.

**Ethical standard.** The authors assert that all procedures contributing to this work comply with the ethical standards of the relevant national guidelines on human experimentation and with the Helsinki Declaration of 1975, as revised in 2008, and have been approved by the institutional review board of the Children's Hospital Lahore.

## References

1. Bertolini A, Dalmonte P, Bava G L, Moretti R, Cervo G, Marasini M. Aortopulmonary septal defects. A review of the literature and report of ten cases. *J Cardiovasc Surg* 1994; 35: 207–213.
2. Gowda D, Gajjar T, Rao JN, et al. Surgical management of aortopulmonary window: 24 years of experience and lessons learned. *Interact Cardiovasc Thorac Surg* 2017; 25: 302–309. DOI: [10.1093/icvts/ivx099](https://doi.org/10.1093/icvts/ivx099).
3. Stamato T, Benson LN, Smallhorn JF, Freedom RM. Transcatheter closure of an aortopulmonary window with a modified double umbrella occluder system. *Cathet Cardiovasc Diagn* 1995; 35: 165–167.
4. Giordano M, Butera G. Percutaneous closure of an aortopulmonary window in a young adult patient: a case report of transcatheter closure with an occluder device. *Eur Heart J Case Rep* 2020; 4: 1–4.
5. Odemis E, Guvenc O, Saygi M, Demir IH. Closure of aortopulmonary window using Nit-Occlud® PDA-R device in a 3-month-old infant. *Pediatr Int* 2016; 58: 754–756. DOI: [10.1111/ped.12943](https://doi.org/10.1111/ped.12943).
6. Celebi A, Yucel IK, Balli S, Kucuk M. Two cases of transcatheter closure of central aortopulmonary shunts: one with an amplatzer duct occluder II and one with an amplatzer vascular plug I. *Tex Heart Inst J* 2016; 43: 241–245. DOI: [10.14503/THIJ-15-5080](https://doi.org/10.14503/THIJ-15-5080).
7. Richens T, Wilson N. Amplatzer device closure of a residual aortopulmonary window. *Catheter Cardiovasc Interv* 2000; 50: 431–433.
8. Sadiq M, Qureshi A, Younas M, Arshad S, Hyder SN. Percutaneous closure of ventricular septal defect using lifeTech™ Konar-MF VSD occluder: initial and short-term multi-institutional results. *Cardiol Young* 2022; 32: 755–761. DOI: [10.1017/S1047951121002985](https://doi.org/10.1017/S1047951121002985).
9. Abdelrazek Ali Y, Nour A, Rashad M, et al. Transcatheter closure of a large aortopulmonary window with the novel device multifunctional occluder (Konar) under TEE guidance (A case report). *J Cardiol Cases* 2022; 25: 370–372. DOI: [10.1016/j.jccase.2021.12.014](https://doi.org/10.1016/j.jccase.2021.12.014).
10. Saxena A, Jay R, Ravi A, et al. Indian guidelines for indications and timing of intervention for common congenital heart diseases: revised and updated consensus statement of the working group on management of congenital heart diseases. *Ann Pediatr Cardiol* 2019; 12: 254–286. DOI: [10.4103/apc.APC\\_32\\_19](https://doi.org/10.4103/apc.APC_32_19).