

## Schizophrenia and the frontal lobes

### Post-mortem stereological study of tissue volume

J. ROBIN HIGHLEY, MARY A. WALKER, MARGARET M. ESIRI,  
BRENDAN McDONALD, PAUL J. HARRISON and TIMOTHY J. CROW

**Background** It has been suggested that there is frontal lobe involvement in schizophrenia, and that it may be lateralised and gender-specific.

**Aims** To clarify the structure of the frontal lobes in schizophrenia in a post-mortem series.

**Method** The volume of white matter and cortical components of the frontal lobes was measured in brains of controls and patients with schizophrenia using planimetry and the Cavalieri principle. The components measured were: superior frontal gyrus, middle frontal gyrus, a composite of inferior frontal gyrus and orbito-frontal cortex, as well as total frontal lobe cortex and white matter. In addition, the anterior cingulate gyrus was measured.

**Results** No diagnosis, gender, diagnosis  $\times$  side, diagnosis  $\times$  gender or diagnosis  $\times$  gender  $\times$  side interactions were observed in the volume of any of the components, the grey matter as a whole or the white matter. No evidence for volumetric inter-group differences was found for the anterior cingulate gyrus.

**Conclusions** Such structural abnormalities as are present in the frontal lobes are more subtle than straightforward alterations in tissue volume; they may include changes in shape and the pattern of gyral folding.

**Declaration of interest** This work was supported by The Medical Research Council and The Wellcome Trust.

Evidence from both functional and neuropathological studies suggests that the frontal lobes are affected in schizophrenia (Goldman-Rakic & Selemon, 1997), raising the issue of the potential for differences in the volume of frontal lobe tissue between individuals with and without schizophrenia. There is some evidence in the existing literature for either a reduction in frontal lobe grey matter volume or a global cortical reduction that is more marked in the frontal lobes (Breier *et al*, 1992). There is additional evidence for lateralised alterations in the frontal lobe volume in schizophrenia (Bilder *et al*, 1994). Early studies defined the posterior limit of the frontal lobes with some arbitrary landmark (e.g. the genu of the corpus callosum), as opposed to the central sulcus, which is anatomically a more valid boundary. A previous study of the present brain collection (Highley *et al*, 1998a) suggests that taking proper account of the central sulcus may be important. In that study, the length from the frontal pole to the central sulcus was measured dorsally over the external surface of both frontal lobes on post-mortem brains and a striking gender  $\times$  diagnosis interaction was found (see Discussion). The present study was performed to elucidate the nature of volumetric differences (if present) in the brain in schizophrenia, when the frontal lobes are defined in a non-arbitrary manner. The following structures were measured: the pre-central gyrus, the superior frontal gyrus, the middle frontal gyrus, a composite of the inferior frontal gyrus and orbito-frontal cortex, the total frontal lobe cortex and white matter. In addition, the anterior cingulate volume was assessed.

## METHOD

### Tissue

Brains were fixed by suspension from the basilar artery in 10% formalin, collected

from three centres (Oxford, Belfast and Wickford (in Essex)) in the UK and then assigned a randomised code by a third party so that measurements could be made blind to gender, diagnosis and age. Brains were stored in formalin for an average of 3.25 years prior to use in the study. It has been observed that any volume alterations related to fixation stabilise after a maximum of 3 weeks (Quester & Schröder, 1997), and therefore, as all brains were fixed in excess of this duration, it can be assumed that they had reached their stable state.

The brains were screened to ensure that they were free of neuropathological disease. Brains from patients who had undergone leucotomy were excluded. Patients' clinical notes were assessed by a psychiatrist (T.J.C. or Steven J. Cooper (see Acknowledgements)) to ensure that diagnoses conformed to DSM-IV (American Psychiatric Association, 1994) criteria for schizophrenia or schizoaffective disorder. The control subjects' clinical notes were screened to ensure that they were free of psychopathology.

The mean age, cerebrum weight and post-mortem delay, as well as hospital of origin, cause of death and number of cases in the different groups, are given in Table 1. As can be seen from Table 1, the females were significantly older than the males. For this reason, age was entered into all ANOVAs as a covariate.

## Methods

The frontal lobes were defined as all cortex and white matter anterior to the central sulcus. The basal ganglia, insula, ventricles and internal capsule were not included.

All brains were stripped of the leptomeninges and bisected in the median sagittal plane. The temporal and occipital lobes were dissected away by sectioning the white matter running between the temporal and frontal lobes and insula, and a cut through the parietal lobes.

Either side of the central sulcus, the pre- and post-central gyri were painted with permanent ink of different colours. The frontal lobes were then sectioned into serial, parallel coronal slices using 5-mm guides. After slicing, the slices were reassembled into a stack (excluding the first and last slices), the length of which was measured and divided by the number of slices, to generate the mean slice thickness. For all further measures, *all* slices (including first and last) were included.

**Table 1** The mean (s.d.) age, cerebrum weight and post-mortem delay, as well as hospital of origin and cause of death of cases

	Control		Schizophrenia	
	Female	Male	Female	Male
Number of cases	13	15	9	15
Age <sup>1</sup> , years	74.6 (13.3)	67.2 (14.5)	73.3 (17.6)	60.9 (15.3)
Cerebrum weight <sup>2</sup> (brain less brain-stem, kg)	0.96 (0.14)	1.12 (0.09)	0.86 (0.15)	1.15 (0.13)
Death to post-mortem delay <sup>3</sup> , hours	43.3 (26.9)	42.6 (28.5)	43.44 (38.1)	48.2 (33.1)
Duration in fixative <sup>4</sup> , years	2.54 (1.33)	2.13 (1.30)	5.22 (1.86)	3.79 (2.12)
Hospital of origin <sup>5</sup> , Belfast/Oxford/Runwell	0/10/3	0/13/2	6/1/2	5/5/5
Cause of death <sup>6</sup> , cardiac/respiratory/other	8/1/3	12/3/0	2/3/2	5/4/5

1. Females significantly older than males: by ANOVA,  $F(1,48)=5.43$ ,  $P=0.024$ .

2. Females significantly lighter than males: by ANCOVA with age as covariate,  $F(1,46)=30.24$ ,  $P<0.0005$ .

3. No inter-group differences: all  $F(1,46)\leq 0.10$ ,  $P>0.7$ .

4. Controls significantly shorter than patients ( $F(1,47)=20.70$ ,  $P<0.0005$ ); trend to females longer than males ( $F(1,47)=3.73$ ,  $P=0.059$ ).

5. No control brains were collected at Belfast, so there were significant group differences in hospital of origin:  $\chi^2=25.27$ , d.f.=6,  $P<0.0005$ . Runwell Hospital located at Wickford in Essex.

6. No inter-group differences:  $\chi^2=11.23$ , d.f.=6,  $P=0.081$ .

The posterior aspect of each slice was patted dry of excess moisture and photographed using colour slide film, with a ruler in the field of view, ensuring that the planes of the camera lens and the brain slice were parallel. These photographs were then projected, in a random position, at an approximate magnification of  $\times 1.7$  onto a counting grid. The counting grid consisted of a series of crosses in a regular, uniform square array. The density of crosses was such that one cross represented an area of  $2\text{ cm}^2$  on the counting grid. A subset of these crosses was circled such that one circled cross represented  $4\text{ cm}^2$  on the counting grid. The total number of crosses (circled or otherwise) falling on each cortical structure of interest was counted for each slice and then summated. The number of circled crosses falling on white matter were counted and again summated. From these counts, the spacing of the grid, the magnification of the frontal lobe images and the mean slice thickness were calculated estimates of the volumes of the regions of interest, by application of the Cavalieri principle (Gundersen *et al*, 1988).

On slices on which the central sulcus was visible, a line from the central sulcus to the most supero-lateral point of the lateral ventricles defined the inferior boundary of the frontal lobe white matter.

Between the most anterior extent of the central sulcus and the level at which the frontal and temporal lobes are no longer connected, the inferior boundary of the white matter was defined by a straight line from the superior insular circular sulcus to the most supero-lateral point of the lateral ventricles. Anterior to the join between frontal and temporal lobes, all white matter on the slice was counted, including white matter interposed between the basal ganglia and the orbito-frontal cortex. The internal capsule was not included.

The frontal lobe cortex was subdivided into the following regions: primary motor cortex/pre-central gyrus; infero-orbital cortex; middle frontal gyrus; superior frontal gyrus; and frontal pole. In addition, the cortex of the anterior cingulate gyrus was counted. In six cases the anterior cingulate gyrus had been damaged during bisection of the hemispheres, and in these cases the measure was excluded. The anterior cingulate was excluded from the total frontal cortical volume. The basal ganglia, thalamus and other subcortical grey matter structures were not counted. The subdivisions are depicted in Fig. 1.

The *motor cortex* was defined as the pre-central gyrus.

The *superior frontal gyrus* abuts the pre-central gyrus, separated from it by the pre-central sulcus. On the medial surface

of the hemisphere, it lies superior to the cingulate. Anteriorly it wraps around the front of the cingulate to meet up with the orbito-frontal cortex. The superior frontal gyrus lies superior to the middle frontal gyrus, separated from it by the superior frontal sulcus.

The *middle frontal gyrus* lies between the superior and inferior frontal gyri and is bounded by the superior and inferior frontal sulci. Posteriorly it abuts the pre-central gyrus, and is separated from it by the pre-central sulcus.

The *infero-orbital cortex* is a composite of the inferior frontal gyrus and the orbito-frontal cortex. These two were compounded because it proved to be impossible to reliably separate one from the other. The inferior frontal gyrus is inferior to the middle frontal gyrus, separated from it by the inferior frontal sulcus. Medially, the orbito-frontal cortex is bounded by that portion of the anterior cingulate that lies underneath the rostrum of the corpus callosum and anterior to the genu. All grey matter on the inferior surface of the frontal lobes was included in this measure.

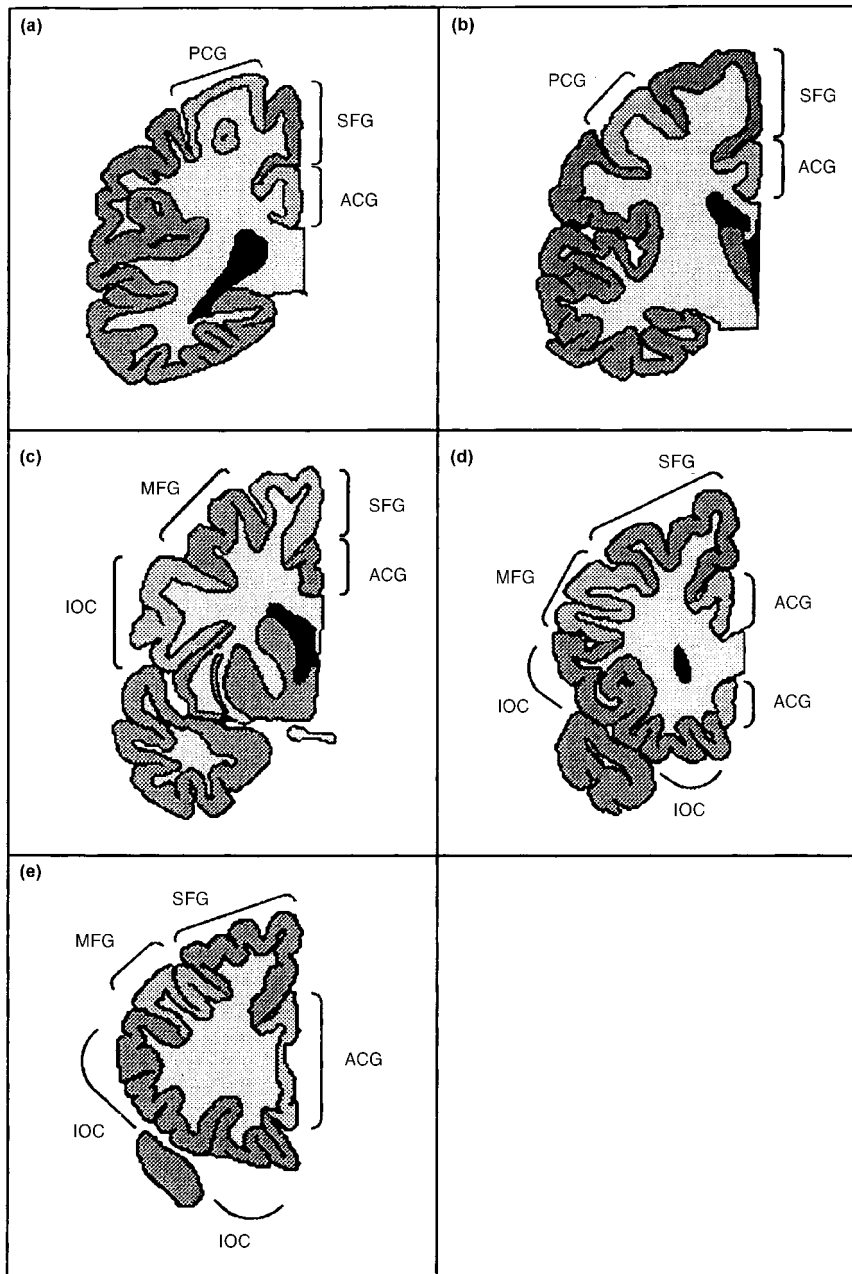
The *frontal pole* was defined as all the grey matter on the most anterior one or two slices in the situation where the different gyri were indistinguishable. The sole use of this measure was to be summated with the other grey matter measures to give the total frontal lobe cortical volume.

The *anterior cingulate gyrus* lies superior to the corpus callosum and curves anteriorly and inferiorly around the genu. The posterior boundary of the anterior cingulate was at the level one-fifth along the maximal anterior-posterior length of the corpus callosum. The cingulate was identified superior, anterior and inferior to the corpus callosum.

## RESULTS

### Analysis of measurement protocol

The observed coefficients of error (OCE) for estimates of volume were calculated as described by Gundersen & Jensen (1987). The mean value of OCE was calculated for each measure for each group (female control, male control, female schizophrenia and male schizophrenia). The highest mean value of OCE for any grey matter component measure for any group was 0.087. For the total grey and white matter volumes, the maximum mean OCE values observed were 0.033 and 0.055,



**Fig. 1** The frontal lobe structures as defined in this study: PCG, pre-central gyrus; ACG, anterior cingulate gyrus; SFG, superior frontal gyrus; MFG, middle frontal gyrus; IOC, infero-orbital cortex (a most posterior to e most anterior).

respectively. These values are all acceptable, being less than the target average value of 0.1 that was chosen when planning the investigation.

From the mean values of OCE, one can estimate the percentage of observed relative variance of each measure for each subject group accounted for by true inter-individual variance, as opposed to inaccuracy in the stereological volume estimate. For each comparison group, true inter-individual variation accounted for a

minimum of 91.0% of the observed relative variance for the grey matter component measures. For the total grey matter and white matter volumes, true inter-individual variation accounted for a minimum of 97.6% of the observed relative variance for the different comparison groups.

For the cingulate gyrus, the largest mean OCE was 0.079. True inter-individual variation accounted for a minimum of 90.1% of the observed relative variance for any group.

### Comparison with previous studies

The volume of total frontal lobes has been measured in a number of other studies, the most comparable being those of Pakkenberg (1993) and Pakkenberg & Gundersen (1997). In the former, the total volume (left+right) of cortex in the frontal lobe was measured in males both with and without schizophrenia. Although not explicitly stated, it appears that this measure included the cingulate. For the control males, the mean volume ( $211.6 \text{ cm}^3$ ) was significantly larger ( $t=3.400$ ,  $d.f.=29$ ,  $P=0.002$ ) than the equivalent volume in the present study ( $174.4 \text{ cm}^3$ ). For the males with schizophrenia there was no significant difference ( $t=0.928$ ,  $d.f.=18$ ,  $P=0.366$ ) between the measures of Pakkenberg ( $182.2 \text{ cm}^3$ ) and the present study ( $195.8 \text{ cm}^3$ ). Pakkenberg & Gundersen also measured the same volume in males unaffected by schizophrenia, and again recorded a significantly higher volume ( $213 \text{ cm}^3$ ) than the present study ( $t=3.585$ ,  $d.f.=75$ ,  $P=0.0006$ ). These workers also measured the volumes of females without schizophrenia, finding the mean volume to be  $184 \text{ cm}^3$ , which did not differ significantly ( $t=1.195$ ,  $d.f.=41$ ,  $P=0.239$ ) from the equivalent volume in the present study ( $169.4 \text{ cm}^3$ ). The reason for the smaller values in the present study for control males is unclear, but there may possibly be slight differences in the working definition of the frontal lobes. However, given that two out of three of the groups for which a meaningful comparison can be made show no such difference, it can be concluded that the measures achieved in the present study reasonably estimate the volumes of frontal lobe structures.

### Effects of diagnosis and gender

The mean values of each measure are shown in Table 2. For each frontal lobe grey matter component (pre-central gyrus, superior frontal gyrus, middle frontal gyrus, infero-orbital cortex), an ANCOVA was performed with diagnosis and gender as between-subject factors, side as a within-subject factor and age as a covariate. The main effects of gender and diagnosis were tested for, as were diagnosis  $\times$  gender, diagnosis  $\times$  side and diagnosis  $\times$  gender  $\times$  side interactions. The results of these analyses are given in Table 3. For analysis of the frontal cortical components,  $\alpha$  was set to 0.0125 prior to the analyses because four such regions were studied.

**Table 2** The mean (s.d.) volume measures (in cm<sup>3</sup>) for each group

		Female		Male	
		Control	Patient	Control	Patient
Pre-central gyrus	Left	17.6 (2.82)	18.2 (2.71)	20.6 (4.97)	20.1 (5.13)
	Right	17.5 (4.87)	18.1 (4.14)	18.1 (4.02)	19.5 (5.09)
Superior frontal gyrus	Left	18.8 (3.78)	17.6 (3.93)	19.0 (3.99)	19.9 (3.83)
	Right	20.4 (4.62)	17.8 (4.95)	19.4 (5.19)	21.6 (4.44)
Middle frontal gyrus	Left	12.2 (2.16)	11.9 (3.30)	12.1 (3.71)	13.8 (3.51)
	Right	11.7 (3.46)	12.1 (2.89)	12.3 (3.38)	13.2 (3.64)
Infero-orbital cortex	Left	20.9 (4.31)	18.7 (6.99)	22.6 (5.28)	26.3 (6.68)
	Right	21.9 (5.52)	20.3 (4.97)	21.7 (6.78)	25.7 (5.42)
Total grey matter	Left	74.5 (11.2)	69.9 (11.9)	79.9 (15.7)	86.0 (11.2)
	Right	76.0 (14.1)	72.1 (11.1)	76.6 (15.3)	84.7 (13.5)
White matter	Left	67.7 (24.9)	68.0 (18.2)	72.7 (31.4)	88.4 (19.1)
	Right	66.1 (22.4)	63.1 (17.6)	71.3 (32.1)	86.3 (18.7)
Cingulate gyrus	Left	9.55 (2.27)	8.80 (3.58)	9.32 (2.39)	10.4 (1.86)
	Right	8.97 (2.44)	8.51 (2.08)	8.60 (2.06)	9.92 (1.45)

**Table 3** Results of the ANCOVAs of frontal lobe volume data

	Diagnosis	Gender	Diagnosis × gender	Diagnosis × side	Gender × side × diagnosis
Pre-central gyrus	$F(1,47)=0.09$ $P=0.766$	$F(1,47)=1.13$ $P=0.293$	$F(1,47)=0.05$ $P=0.828$	$F(1,48)=0.48$ $P=0.491$	$F(1,48)=0.50$ $P=0.485$
Superior frontal gyrus	$F(1,47)=0.11$ $P=0.746$	$F(1,47)=0.44$ $P=0.512$	$F(1,47)=2.12$ $P=0.152$	$F(1,48)<0.005$ $P=0.989$	$F(1,48)=1.62$ $P=0.210$
Middle frontal gyrus	$F(1,47)=0.42$ $P=0.519$	$F(1,47)=0.32$ $P=0.572$	$F(1,47)=0.39$ $P=0.534$	$F(1,48)<0.005$ $P=0.985$	$F(1,48)=0.77$ $P=0.384$
Infero-orbital cortex	$F(1,47)=0.25$ $P=0.618$	$F(1,47)=4.03$ $P=0.050$	$F(1,47)=3.41$ $P=0.071$	$F(1,48)=0.08$ $P=0.777$	$F(1,48)<0.005$ $P=0.956$
Total grey matter	$F(1,47)=0.04$ $P=0.840$	$F(1,47)=3.37$ $P=0.073$	$F(1,47)=2.23$ $P=0.142$	$F(1,48)=0.26$ $P=0.610$	$F(1,48)=0.06$ $P=0.815$
White matter	$F(1,47)=0.62$ $P=0.436$	$F(1,47)=1.55$ $P=0.219$	$F(1,47)=1.21$ $P=0.278$	$F(1,48)=0.39$ $P=0.536$	$F(1,48)=0.15$ $P=0.697$
Cingulate cortex	$F(1,41)=0.06$ $P=0.812$	$F(1,41)=0.13$ $P=0.721$	$F(1,41)=1.85$ $P=0.181$	$F(1,42)=0.15$ $P=0.700$	$F(1,42)<0.005$ $P=0.983$

**Table 4** Correlation between the superior frontal length and the volume of the ipsilateral superior and middle frontal gyri

	Superior frontal gyrus volume	Middle frontal gyrus volume
Left length	$r=0.3297$ , d.f.=47, $P=0.021$	$r=0.4743$ , d.f.=47, $P=0.001$
Right length	$r=0.3130$ , d.f.=47, $P=0.029$	$r=0.3026$ , d.f.=47, $P=0.035$

The frontal lobe total grey and white matter and cingulate cortex were analysed in a similar manner but with  $\alpha$  set to 0.05.

These analyses yielded no significant effects. There were non-significant trends towards a gender effect and a diagnosis × gender interaction effect on the volume of

the infero-orbital cortex. The gender effect reflected smaller volumes in the female brains compared with the male brains. The interaction corresponded to a smaller volume in female patients and an elevated volume in male patients compared with controls. However, given the large number of effects examined for, this is likely to be a chance occurrence.

### Relationship between measures obtained from this and other studies

This study was designed in part to investigate whether a gender × diagnosis interaction in the asymmetry of the length of the frontal lobes over their superior surface as found in a prior report (Highley *et al*, 1998a) was due to alterations in the volume of the superior frontal gyrus. To investigate the relationship between the two measures, the correlations between the superior frontal length and the volume of the superior frontal gyrus as measures were assessed. As it was also feasible that the middle frontal gyrus may be related to this length measure, the correlation with this volume was also assessed. The results of these tests are given in Table 4.

All of these correlations were significant but modest: the greatest correlation coefficient is  $r=0.4743$  (for the left middle frontal gyrus), suggesting that variations in the left middle frontal gyrus volume can account for only 22.5% of the variance of the length measure. All other correlation coefficients were smaller than this.

### Potential artefacts

It may be argued that some aspects of brain extraction and fixation in different hospitals may have differentially affected the tissue studied in this paper. This was analysed for both grey and white matter using the data from the males with schizophrenia (five cases came from each of the three centres). Two repeated-measures ANOVAs were performed to investigate the effect of hospital of origin on the total grey and white matter volumes. There was no effect of origin on either the total grey volume ( $F(2,12)=0.88$ ,  $P=0.440$ ) or the white matter volume ( $F(2,12)=0.16$ ,  $P=0.853$ ).

Goldstein *et al* (1999) assessed the volumes of grey matter components while controlling for overall cerebrum volume. The inclusion of cerebrum weight as well as age as a covariate in the ANCOVA

**Table 5** Summary of results of this and previous studies

	Pakkenberg (1993)	Baaré <i>et al</i> (1999)	Buchanan <i>et al</i> (1998)	Goldstein <i>et al</i> (1999)	Crespo-Facorro <i>et al</i> (2000)	Present study
Superior frontal gyrus		0	0	0	0	0
Middle frontal gyrus		0	0	Left↓	0	0
Inferior frontal gyrus <sup>1</sup>		} 0	Bilateral↓	0	0	} 0
Orbito-frontal cortex <sup>1</sup>			0	Right↓	0	
Total grey matter	0		0	0	0	0
Frontal white matter			↓			0

1. Orbito-frontal and inferior frontal cortices are merged in the current study and in the study of Baaré *et al*.  
0, no significant difference in volume between patients and comparison subjects.

analysis of data in this study did not alter the outcome of the analyses.

The possible effect of death to fixation delay and duration in fixative was investigated by repeating all the ANCOVAs for cortical components, total grey and white matter and anterior cingulate, with fixation delay and duration as covariates. These analyses revealed no effect of either fixation delay (all  $-0.227 < z < 1.869$ , all  $P \geq 0.069$ ) or duration in fixative (all  $-1.683 < z < 0.511$ , all  $P \geq 0.100$ ). The outcomes of the analyses of the effects of diagnosis and gender were not altered.

## DISCUSSION

This study finds no evidence for any alteration, lateralised or otherwise, in the volume of the cortex or white matter of the frontal lobe or of the anterior cingulate gyrus.

### Previous studies of the frontal lobes

When this study was commenced, only one study assessing any aspect of frontal lobe size had used the anatomically correct central or pre-central sulcus as the boundary (Pakkenberg, 1993). With this exception, prior studies used arbitrary landmarks to select coronal slices to define the posterior boundary, a procedure that is unsatisfactory on two counts: first, if the position of the central sulcus (the true boundary of the frontal lobes) should alter in schizophrenia, such that more or less cortex lies within the frontal lobes, this will not be detected; and second, if the position of a landmark used to delineate the frontal lobe boundary is altered in schizophrenia, this may adversely affect the volumes estimates. Thus, for example, both Bilder *et al* (1994) and Breier *et al* (1992) used the genu of the

corpus callosum as the boundary between the pre-frontal and pre-motor cortices. However, there is evidence for alterations in callosal anatomy in schizophrenia (Woodruff *et al*, 1995; Highley *et al*, 1999a).

Since the current study was commenced, four magnetic resonance imaging (MRI) studies have examined frontal lobe cortical volumes in schizophrenia using either the pre-central or central sulci as the boundary of frontal lobe components (Buchanan *et al*, 1998; Baaré *et al*, 1999; Goldstein *et al*, 1999; Crespo-Facorro *et al*, 2000). The findings of these studies, and the post-mortem study mentioned above (Pakkenberg, 1993), are summarised in Table 5. In addition, Szeszko *et al* (1999) have performed an MRI analysis of frontal lobe components with measures including white as well as grey matter.

As can be seen from Table 5, the majority of measures made in these studies find no effect of schizophrenia. Those effects that are found are inconsistent between studies. For example, Szeszko *et al*'s measure of orbito-frontal tissue (which included underlying white matter) found a right-sided increase in male but not female patients with schizophrenia. This was not replicated in any other study.

The reduction in prefrontal white matter volume (excluding white matter underlying the pre-central sulcus) reported by Buchanan *et al* (1998) was not confirmed in the present study (which included all white matter). No other study has measured white matter using appropriate landmarks, leaving this disagreement unresolved.

### Is the primary focus in the temporal lobes?

Taking these studies (Pakkenberg, 1993; Buchanan *et al*, 1998; Baaré *et al*, 1999;

Goldstein *et al*, 1999; Crespo-Facorro *et al*, 2000) together with the present study, it would appear that the frontal lobe grey matter volumes are unaltered in schizophrenia. The view that the structural changes in schizophrenia are selective to the frontal lobes as suggested by Shelton *et al* (1988) is unsupported. By contrast, as noted by Wible *et al* (1995), the literature contains many reports of reductions in the volume of temporal lobe structures that are either selective to or greater on the left (Highley *et al*, 1999b; McDonald *et al*, 2000). In addition, many studies observe a non-lateralised reduction in the volumes of temporal lobe structures (Zipursky *et al*, 1994). Other temporal lobe pathology includes a relatively greater enlargement of the temporal horn than the rest of the lateral ventricle (Crow *et al*, 1989), and shortening of the temporal lobes (Highley *et al*, 1998b). Such findings raise the possibility of a qualitative difference between frontal and temporal lobes as the site of a pathophysiology of schizophrenia.

For the anterior cingulate gyrus, consistent with the current report, three MRI studies have found no alteration in the volume of this structure (Noga *et al*, 1995; Woodruff *et al*, 1997; Szeszko *et al*, 1999). Three studies that report differences lack a consensus as to what the differences are. Albanese *et al* (1995) measured the weight and surface area of the anterior cingulate from dissected post-mortem brain. They found controls to show a right-greater-than-left asymmetry, whereas patients showed the opposite or absence of asymmetry. Examination of their data reveals this to be largely due to right-sided reductions in anterior cingulate volume and surface area. In contrast, Goldstein *et al* (1999) claim a reduction in total (presumably left+right) anterior cingulate

volume. Finally, Hirayasu *et al* (1999) describe a non-significant left-sided volume reduction in that portion of the cingulate that lies inferior to the corpus callosum, a measure in which Goldstein *et al* (1999) found no change.

### Surface asymmetries and sulco-gyral structure

A previous study on this set of brains (Highley *et al*, 1998a) reported a striking and unexpected gender  $\times$  diagnosis interaction in the length from the frontal pole to the central sulcus when measured over the superior surface of the brain. Female controls had a left-greater-than-right asymmetry and male controls had a right-greater-than-left asymmetry; the pattern was reversed in schizophrenia. No significant effect was apparent when the tape measure was passed around the lateral aspect of the brain, suggesting a regional specificity. We predicted that this asymmetry would reflect a gender  $\times$  diagnosis  $\times$  side interaction in the volume of the superior temporal lobe. No such volume changes were observed.

The minimal relationship between the frontal lobe length measures of our prior study and the volume measures of the present study may explain the failure to demonstrate the hypothesised gender  $\times$  diagnosis  $\times$  side interaction in superior frontal gyrus volume: some aspect of frontal lobe anatomy other than volume must be responsible for the interaction effect on the length measure. An obvious alternative is the shape and sulco-gyral structure of the lobe. Gyral folding can be viewed as an index of cortico-cortical connectivity (Griffin, 1994; Van Essen, 1997). There is evidence for alterations in gyral folding in both the frontal (Vogeley *et al*, 1998) and temporal (Highley *et al*, 1998b) lobes in schizophrenia.

In a recent MRI study (further details available from the author upon request) with volume assessments similar to those used in the present investigation, we find effects of diagnosis that interact with gender and hemisphere when age of onset is taken into account. No such effects are seen when age of onset is omitted from analysis. Age of onset may therefore be a variable that is critical to understanding the morphological changes in psychosis.

### CLINICAL IMPLICATIONS

- The volumes of the frontal lobes are unchanged in schizophrenia, in contrast with decreased volumes and altered asymmetries in the temporal lobes.
- This combination of findings constrains theories of the origin of the structural brain changes in schizophrenia.
- Schizophrenia cannot be considered as a simple disorder of the frontal lobes.

### LIMITATIONS

- Although large for a post-mortem study, the sample size does not exclude small differences in frontal lobe volume in schizophrenia.
- There may be alterations in other morphological aspects of the frontal lobes (e.g. sulco-gyral structure and cellular composition).
- The study was limited to frontal lobe structure.

J. ROBIN HIGHLEY, DPhil, MARY A. WALKER, MARGARET M. ESIRI, FRCPath, BRENDAN McDONALD, MRCPsych, Schizophrenia Research Group, Department of Clinical Neurology (Neuropathology), Radcliffe Infirmary, Oxford; PAUL J. HARRISON, DM, University Department of Psychiatry, Neurosciences Building, Warneford Hospital, Oxford; TIMOTHY J. CROW, FRCPsych, POWIC, University Department of Psychiatry, Warneford Hospital, Oxford, UK

Correspondence: Timothy J. Crow, POWIC, University Department of Psychiatry, Warneford Hospital, Oxford OX3 7JX, UK. Tel: +44 1865 223909; Fax: +44 1865 244990; e-mail: tim.crow@psychiatry.oxford.ac.uk

(First received 17 January 2000, final revision 19 September 2000, accepted 19 September 2000)

### ACKNOWLEDGEMENTS

The authors would like to thank Dr Steven J. Cooper and Dr Brian M. Herron for their assistance with acquiring tissue and analysing clinical notes. This project was funded by an MRC project grant to M.M.E. and T.J.C. and a Wellcome Trust project grant to M.M.E. and P.J.H.

### REFERENCES

- Albanese, A. M., Merlo, A. B., Mascitti, T. A., et al (1995)** Inversion of the hemispheric laterality of the anterior cingulate gyrus in schizophrenics. *Biological Psychiatry*, **38**, 13–21.
- American Psychiatric Association (1994)** *Diagnostic and Statistical Manual of Mental Disorders* (4th edn) (DSM-IV). Washington, DC: APA.
- Baaré, W. F. C., Hulshoff Pol, H. E., Hijman, R., et al (1999)** Volumetric analysis of frontal lobe regions in schizophrenia: relation to cognitive function and symptomatology. *Biological Psychiatry*, **45**, 1597–1605.
- Bilder, R. M., Houwei, W., Bogerts, B., et al (1994)** Absence of regional hemispheric asymmetries in first-episode schizophrenia. *American Journal of Psychiatry*, **151**, 1437–1447.
- Breier, A., Buchanan, R. W., Elkashef, A., et al (1992)** Brain morphology and schizophrenia: a magnetic resonance imaging study of limbic, prefrontal cortex, and caudate structures. *Archives of General Psychiatry*, **49**, 921–926.
- Buchanan, R. W., Vladar, K., Barta, P. E., et al (1998)** Structural evaluation of the prefrontal cortex in schizophrenia. *American Journal of Psychiatry*, **155**, 1049–1055.
- Crespo-Facorro, B., Kim, J.-J., Andreasen, N. C., et al (2000)** Regional frontal abnormalities in schizophrenia: a quantitative gray matter volume and cortical surface size study. *Biological Psychiatry*, **48**, 110–119.
- Crow, T. J., Ball, J., Bloom, S. J., et al (1989)** Schizophrenia as an anomaly of development of cerebral asymmetry. *Archives of General Psychiatry*, **46**, 1145–1150.
- Goldman-Rakic, P. S. & Selemon, L. D. (1997)** Functional and anatomical aspects of prefrontal pathology in schizophrenia. *Schizophrenia Bulletin*, **23**, 437–458.
- Goldstein, J. M., Goodman, J. M., Seidman, L. J., et al (1999)** Cortical abnormalities in schizophrenia identified by structural magnetic resonance imaging. *Archives of General Psychiatry*, **56**, 537–547.
- Griffin, L. D. (1994)** The intrinsic geometry of the cerebral cortex. *Journal of Theoretical Biology*, **166**, 261–273.
- Gundersen, H. J. G. & Jensen, E. B. (1987)** The efficacy of systematic sampling in stereology and its prediction. *Journal of Microscopy*, **147**, 229–263.

- , **Bendtsen, T. F., Korbo, L., et al (1988)** Some new, simple and efficient stereological methods and their use in pathological research and diagnosis. *Acta Pathologica et Microbiologica Scandinavica*, **96**, 379–394.
- Highley, J. R., Esiri, M. M., McDonald, B., et al (1998a)** Anomalies of cerebral asymmetry in schizophrenia interact with gender and age of onset: a post-mortem study. *Schizophrenia Research*, **34**, 13–25.
- , —, —, **et al (1998b)** Temporal lobe length is reduced, and gyral folding is increased in schizophrenia: a post-mortem study. *Schizophrenia Research*, **34**, 1–12.
- , —, —, **et al (1999a)** The size and fibre composition of the corpus callosum with respect to gender and schizophrenia: a post-mortem study. *Brain*, **122**, 99–110.
- , **McDonald, B., Walker, M. A., et al (1999b)** Schizophrenia and temporal lobe asymmetry. A post-mortem stereological study of tissue volume. *British Journal of Psychiatry*, **175**, 127–134.
- Hirayasu, Y., Shenton, M. E., Salisbury, D. F., et al (1999)** Subgenual cingulate cortex volume in first-episode psychosis. *American Journal of Psychiatry*, **156**, 1091–1093.
- McDonald, B., Highley, J. R., Walker, M. A., et al (2000)** Anomalous asymmetry of fusiform and parahippocampal gyrus grey matter in schizophrenia: a post-mortem study. *American Journal of Psychiatry*, **157**, 40–47.
- Noga, J. T., Aylward, E., Barta, P. E., et al (1995)** Cingulate gyrus in schizophrenic patients and normal volunteers. *Psychiatry Research: Neuroimaging*, **61**, 201–208.
- Pakkenberg, B. (1993)** Total nerve cell number of neocortex in chronic schizophrenics and controls estimated using optical disectors. *Biological Psychiatry*, **34**, 768–772.
- & **Gundersen, H. J. G. (1997)** Neocortical neuron number in humans: effect of sex and age. *Journal of Comparative Neurology*, **384**, 312–320.
- Qeuster, R. & Schröder, R. (1997)** The shrinkage of the human brain stem during formalin fixation and embedding in paraffin. *Journal of Neuroscience Methods*, **75**, 81–89.
- Shelton, R. C., Karson, C. N., Doran, A. R., et al (1988)** Cerebral structural pathology in schizophrenia: evidence for a selective prefrontal cortical defect. *American Journal of Psychiatry*, **145**, 154–163.
- Szeszko, P. R., Bilder, R. M., Lencz, T., et al (1999)** Investigation of frontal lobe subregions in first-episode schizophrenia. *Psychiatry Research: Neuroimaging*, **90**, 1–15.
- Van Essen, D. C. (1997)** A tension-based theory of morphogenesis and compact wiring in the central nervous system. *Nature (London)*, **385**, 313–318.
- Vogele, K., Schneider-Axman, T., Tepest, U., et al (1998)** Disturbed gyrification and reduced volume of the prefrontal lobe in male schizophrenia – a morphometric post-mortem study. *Schizophrenia Research*, **29**, 87.
- Wible, C. G., Shenton, M. E., Hokama, H., et al (1995)** Prefrontal cortex and schizophrenia: a quantitative magnetic resonance imaging study. *Archives of General Psychiatry*, **52**, 279–288.
- Woodruff, P. W. R., McManus, I. C. & David, A. S. (1995)** A meta-analysis of corpus callosum size in schizophrenia. *Journal of Neurology, Neurosurgery and Psychiatry*, **58**, 457–461.
- , **Wright, I. C., Shuriquie, N., et al (1997)** Structural brain abnormalities in male schizophrenics reflect fronto-temporal dissociation. *Psychological Medicine*, **27**, 1257–1266.
- Zipursky, R. B., Marsh, L., Lim, K. O., et al (1994)** Volumetric MRI assessment of temporal lobe structures in schizophrenia. *Biological Psychiatry*, **35**, 501–516.