

Insular volume abnormalities associated with different transition probabilities to psychosis

R. Smieskova^{1,2}, P. Fusar-Poli³, J. Aston¹, A. Simon^{4,5}, K. Bendfeldt², C. Lenz⁶, R.-D. Stieglitz¹, P. McGuire³, A. Riecher-Rössler¹ and S. J. Borgwardt^{1,2,3*}

¹ Department of Psychiatry, University of Basel, Switzerland

² Medical Image Analysis Centre, University of Basel, Switzerland

³ Department of Psychosis Studies, King's College London, Institute of Psychiatry, London, UK

⁴ Specialized Out-patient Service for Early Psychosis, Department of Psychiatry, Bruderholz, Switzerland

⁵ University Hospital of Psychiatry, University of Bern, Switzerland

⁶ Radiological Physics, University Hospital Basel, Switzerland

Background. Although individuals vulnerable to psychosis show brain volumetric abnormalities, structural alterations underlying different probabilities for later transition are unknown. The present study addresses this issue by means of voxel-based morphometry (VBM).

Method. We investigated grey matter volume (GMV) abnormalities by comparing four neuroleptic-free groups: individuals with first episode of psychosis (FEP) and with at-risk mental state (ARMS), with either long-term (ARMS-LT) or short-term ARMS (ARMS-ST), compared to the healthy control (HC) group. Using three-dimensional (3D) magnetic resonance imaging (MRI), we examined 16 FEP, 31 ARMS, clinically followed up for on average 3 months (ARMS-ST, $n = 18$) and 4.5 years (ARMS-LT, $n = 13$), and 19 HC.

Results. The ARMS-ST group showed less GMV in the right and left insula compared to the ARMS-LT (Cohen's d 1.67) and FEP groups (Cohen's d 1.81) respectively. These GMV differences were correlated positively with global functioning in the whole ARMS group. Insular alterations were associated with negative symptomatology in the whole ARMS group, and also with hallucinations in the ARMS-ST and ARMS-LT subgroups. We found a significant effect of previous antipsychotic medication use on GMV abnormalities in the FEP group.

Conclusions. GMV abnormalities in subjects at high clinical risk for psychosis are associated with negative and positive psychotic symptoms, and global functioning. Alterations in the right insula are associated with a higher risk for transition to psychosis, and thus may be related to different transition probabilities.

Received 2 August 2011; Revised 25 October 2011; Accepted 26 October 2011; First published online 30 November 2011

Key words: At-risk mental state (ARMS), insula, magnetic resonance imaging (MRI), psychosis, transition.

Introduction

A growing body of magnetic resonance imaging (MRI) evidence suggests that subjects at high clinical risk for psychosis show structural abnormalities in the frontal, insular and temporal regions (Pantelis *et al.* 2003; Borgwardt *et al.* 2007*a, b*, 2008; Meisenzahl *et al.* 2008; Koutsouleris *et al.* 2009; Witthaus *et al.* 2009). Several MRI studies have examined whether there are specific neuroanatomical differences between high-risk subjects who subsequently develop psychosis and those who do not (Pantelis *et al.* 2003; Borgwardt *et al.* 2007*a, b*, 2008; Koutsouleris *et al.* 2009). Structural deficits associated with transition to psychosis can be

seen as vulnerability markers of very early stages of psychosis (Smieskova *et al.* 2010) and are of crucial relevance to the field of preventive interventions in psychosis.

Early clinical intervention in psychosis has recently become a major objective of mental health services. Research at this stage is a potential way of investigating the mechanisms of underlying psychosis, as the same individuals can be studied before and after the onset of psychosis, often with minimal confounding effects of previous antipsychotic treatment. The identification of a clinical risk syndrome, an at-risk mental state (ARMS), that reflects an ultra-high clinical risk predisposition to psychosis is fundamental to both clinical and research work in this area. Most transitions to psychosis in ARMS individuals have been found in the first 2 years after baseline assessment and are much less probable afterwards (Yung *et al.* 2007; Riecher-Rössler *et al.* 2009), suggesting

* Address for correspondence: Dr S. J. Borgwardt, Professor of Neuropsychiatry, Department of Psychiatry, University of Basel, c/o University Hospital Basel, Petersgraben 4, 4031 Basel, Switzerland.

(Email: sborgwardt@uhbs.ch)

rapid dynamic anatomical and neurophysiological changes in the same patients during the pre-psychotic phases. Independent studies have confirmed complex neurophysiological changes underlying the prodromal psychotic phases involving not only brain structure but also disrupted dopaminergic and glutamatergic neurotransmission (Jessen *et al.* 2006; Hurlmann *et al.* 2008). However, to the best of our knowledge no study has explicitly addressed potential neurobiological markers of different levels of risk across the prodromal phase. We therefore investigated separately ARMS individuals with a short or long duration of the ARMS. All these individuals fulfilled the ARMS criteria [similar to the Personal Assessment and Crisis Evaluation Clinic (PACE) criteria] at the time of scanning. In the first group [short-term duration ARMS (ARMS-ST)] the scan was obtained directly after referral to our specialized early detection clinic, that is at the time of ascertainment of the ARMS (within 3 months on average). According to published data, the probability of developing psychosis in this group is 20–40% over 2 years (Yung *et al.* 1998; Riecher-Rössler *et al.* 2007, 2009). In the second group [long-term duration ARMS (ARMS-LT)] the scan was obtained on average after 4.5 years of follow-up. Although at the time of the scan this group was still on the risk continuum to develop psychosis, according to the published data (Yung *et al.* 2007; Cannon *et al.* 2008; Riecher-Rössler *et al.* 2009), they had a lower probability of developing subsequent psychosis when compared to ARMS-ST. Importantly, most of the ARMS individuals who encountered transition (90.5%) did so in the first 2 years after their ARMS was ascertained (Riecher-Rössler *et al.* 2009). After these 2 years, only 3% of included ARMS individuals developed psychosis (Riecher-Rössler *et al.* 2009). Some studies have reported that the transition rate of newly referred individuals is declining in recent years (Haroun *et al.* 2006; Yung *et al.* 2007; Frommann *et al.* 2010). Thus, the transition rate in high-risk populations declined from 31% during the first 2 years as published in 2003 (Pantelis *et al.* 2003) to 16% as published 5 years later (Yung *et al.* 2008). There may be some protective mechanism in the high-risk individuals who compensate for risk factors and remain without subsequent transition to psychosis.

Our aim was to examine the neuroanatomical brain abnormalities associated with higher or lower transition probability and the reduced risk of developing psychosis. In a previous multimodal analysis we found an association between functional and structural abnormalities in groups with different transition probabilities to psychosis (Smieskova *et al.* 2011). Psychopathological symptoms are often associated with negative symptoms (Lencz *et al.* 2004; Riecher-Rössler

et al. 2009) and cognitive deficits (Brewer *et al.* 2006; Simon *et al.* 2007; Riecher-Rössler *et al.* 2009). Consequently, we aimed to clarify the correlation between structural alterations and clinical outcomes during the prodromal phases of psychosis.

Expanding on previous voxel-based morphometry (VBM) studies in ARMS (Pantelis *et al.* 2003; Borgwardt *et al.* 2007a, 2008; Koutsouleris *et al.* 2009; Witthaus *et al.* 2009), in the current study we investigated an ARMS-LT group with a lower probability of developing psychosis compared to an ARMS-ST group (Yung *et al.* 2007) with a higher probability of developing psychosis.

We tested the following hypotheses:

- (1) The magnitude of volumetric abnormalities would be in parallel with the clinical status (ARMS-LT < ARMS-ST < FEP) compared to the healthy control (HC) group.
- (2) Significant correlations between GMV and psychotic symptoms or global functioning were expected in the regions showing volumetric differences in ARMS.

Method

Study population

Since 1999, the FEPSY (Früherkennung von Psychosen; early detection of psychosis) Clinic at the Psychiatric Outpatient Department, Psychiatric University Clinics in Basel recruited and followed up ARMS individuals and patients experiencing a first episode of psychosis (FEP) over up to 7 years (Riecher-Rössler *et al.* 2009). The entire group of individuals with an ARMS (ARMS-ST and ARMS-LT; $n=31$) corresponds to the criteria by Yung *et al.* (1998) used in previous MRI studies (Pantelis *et al.* 2003; Borgwardt *et al.* 2007a, b, 2008; Sun *et al.* 2009). The FEP patients ($n=16$) met operational criteria for FEP according to Breitborde *et al.* (2009). All included individuals were assessed at baseline and at the time of the MRI scan.

Inclusion to the ARMS group required one or more of the following: (a) 'attenuated' psychotic symptoms, (b) brief limited intermittent psychotic symptoms (BLIPS) or (c) a first-degree relative with a psychotic disorder plus a marked decline in social or occupational functioning (Yung *et al.* 2004; Riecher-Rössler *et al.* 2007, 2009).

We divided the ARMS group into two subgroups depending on the duration of the ARMS status since the baseline assessment. Individuals with short-term ARMS (ARMS-ST) fulfilled ARMS criteria for a time period shorter than 2 years and individuals with long-term ARMS (ARMS-LT) were in an ARMS over a follow-up period longer than 2 years. ARMS-ST

individuals had an MRI scan as soon as practicable, on average within 2.64 (s.d.=4.8) months [i.e. 0.22 (s.d.=0.4) years]. ARMS-LT individuals were scanned on average 4.62 (s.d.=2.06) years after first ascertainment and made no transition until the point of data analysis (March 2011). At the time of scanning, all the ARMS-ST and ARMS-LT individuals fulfilled the criteria of Yung *et al.* for the ARMS (Yung *et al.* 1998; Riecher-Rössler *et al.* 2008) but had different probabilities of developing psychosis (Cannon *et al.* 2008; Yung *et al.* 2008; Riecher-Rössler *et al.* 2009).

From the baseline assessment, the ARMS-ST and ARMS-LT subjects were followed up by the clinical service and received standard psychiatric case management. At the time of scanning, all of the ARMS individuals (from both groups) were antipsychotic naive, except for one antipsychotic-free ARMS-ST subject (olanzapine 2.5 mg/day during the period of 9 months, stopped 4 months ago). Furthermore, four of the FEP, six of the ARMS-LT and six of the ARMS-ST were receiving antidepressants at the time of the MRI scan.

The FEP patients ($n=16$) were defined as subjects who met the operational criteria for 'first-episode psychosis' (Breitborde *et al.* 2009). Inclusion required scores of ≥ 4 on the hallucination item or ≥ 5 on the unusual thought content, suspiciousness or conceptual disorganization items of the Brief Psychiatric Rating Scale (BPRS; Yung *et al.* 1998). The symptoms must have occurred at least several times a week and persisted for more than 1 week. None of the FEP group were receiving antipsychotic medication at time of scanning. Ten of our FEP patients were antipsychotic naive and six were antipsychotic free; antipsychotic medication (one risperidone, five aripiprazole, two olanzapine) was stopped 1, 2, 4, 19 and 24 months ago, one subject with unknown withdrawal period.

We recruited healthy volunteers (HC, $n=19$) from the same geographical area as the other groups. All subjects were representative of the local population of individuals presenting with an ARMS in terms of age, gender, handedness, and alcohol and cannabis consumption. These individuals had no current psychiatric disorder, no history of psychiatric illness, head trauma, neurological illness, serious medical or surgical illness, or substance abuse, and no family history of any psychiatric disorder as assessed by an experienced psychiatrist in a detailed clinical assessment.

We applied the following exclusion criteria to our groups: history of previous psychotic disorder; psychotic symptomatology secondary to an 'organic' disorder; substance abuse according to ICD-10 research criteria; psychotic symptomatology associated with an affective psychosis or a borderline personality disorder; age <18 years; inadequate knowledge of the German language; and IQ <70.

Instruments

We assessed subjects using the Basel Screening Instrument for Psychosis (BSIP; Riecher-Rössler *et al.* 2007, 2008), the BPRS, the Scale for the Assessment of Negative Symptoms (SANS) and the Global Assessment of Functioning (GAF) at the time of scanning. The BSIP evaluates 'prodromal' symptoms (according to DSM-III-R) occurring in the past 5 years; non-specific 'prodromal' signs (Riecher-Rössler *et al.* 2007) in the past 2 years; previous or current psychotic symptoms, psychosocial functioning over the past 5 years, substance dependency; and psychotic disorders among first- and second-degree relatives (Riecher-Rössler *et al.* 2008). We obtained current and previous psychotropic medication, alcohol, nicotine, cannabis and other illegal drug consumption using a semi-structured interview adapted from the Early Psychosis Prevention and Intervention Centre (EPPIC) Drug and Alcohol Assessment Schedule (www.eppic.org.au).

Magnetic resonance image acquisition

Structural MRI

A three-dimensional (3D) T1-weighted magnetization prepared rapid gradient echo (MPRAGE) sequence was acquired on a 3-T MRI system (Magnetom Verio, Siemens Healthcare, Germany) with sagittal orientation based on a $256 \times 256 \times 176$ matrix, with 1 mm isotropic spatial resolution, inversion time (TI) of 1000 ms, repetition time (TR) of 2 s and echo time (TE) of 3.4 ms. All of the scans were screened for gross radiological abnormalities by an experienced neuro-radiologist.

Image analysis

We examined group-related differences in grey matter volume (GMV) using SPM8 software (www.fil.ion.ucl.ac.uk/spm; Wellcome Department of Cognitive Neurology, UK) running under Matlab 7.1 (MathWorks, USA). T1-weighted MPRAGE images were preprocessed using the VBM8 toolbox (<http://dbm.neuro.uni-jena.de/vbm8/>). This approach involves the creation of a study-specific template and the segmentation of each individual image using the template, with the aim of maximizing accuracy and sensitivity (Yassa & Stark, 2009). We provided the following steps: (1) checking for scanner artefacts and gross anatomical abnormalities for each subject; (2) using the New Segmentation approach with different treatment of the mixing proportions; (3) using the DARTEL toolbox to produce a high-dimensional normalization protocol (Ashburner, 2007); (4) checking

Table 1. Demographic and clinical characteristics

Characteristic	FEP (<i>n</i> = 16)	ARMS-ST (<i>n</i> = 18)	ARMS-LT (<i>n</i> = 13)	HC (<i>n</i> = 19)	Statistics		
					<i>F</i> / χ^2	df	<i>p</i>
Gender male, <i>n</i> (%)	12 (75)	14 (77.8)	8 (72.7)	10 (52.6)	$\chi^2 = 4.790$	3	0.091
Mean age (years), mean (s.d.)	25.13 (4.6)	25.11 (6.2)	24.62 (2.2)	26.58 (4.2)	<i>F</i> = 0.579	65	0.637
Handedness (left), <i>n</i> (%)	1 (6.3)	0	0	1 (5.3)	$\chi^2 = 1.856$	3	0.603
MWT-B IQ, mean (s.d.)	103 (10.7)	112 (14.2)	107 (13.3)	114 (9.7)	<i>F</i> = 2.710	56	0.054
Years since presentation, mean (s.d.)	1.56 (2.7)	0.22 (0.4)	4.23 (2.0)	0	<i>F</i> = 16.914	46	<0.0001
Alcohol currently, <i>n</i> (%)					$\chi^2 = 15.303$	6	0.018
None	4 (25)	2 (11.1)	0	0			
Moderate	11 (68.8)	7 (38.9)	8 (61.5)	14 (73.7)			
Drunkenness	11 (6.3)	9 (50.0)	5 (38.5)	5 (26.3)			
Cannabis, <i>n</i> (%)	6 (37.5)	7 (38.89)	4 (30.8)	4 (21.1)	$\chi^2 = 2.107$	3	0.550
BPRS total, mean (s.d.)	54.0 (13.4)	40.1 (8.1)	32.8 (6.8)	24.6 (1.2)	<i>F</i> = 37.200	61	<0.0001
<i>Post-hoc</i>	58.56 (15.0) ^a	39.8 (8.3) ^a					
<i>Post-hoc</i>	> HC: <i>p</i> < 0.0001	> HC: <i>p</i> = 0.0001	> HC: <i>p</i> = 0.050				
<i>Post-hoc</i>		< FEP: <i>p</i> = 0.001	< FEP: <i>p</i> = 0.001				
BPRS 9, mean (s.d.)	3.6 (1.4)	2.5 (1.2)	1.6 (0.8)	1 (0)	<i>F</i> = 20.105	60	<0.0001
<i>Post-hoc</i>	3.9 (1.6) ^a	2.5 (1.3) ^a					
<i>Post-hoc</i>	> HC: <i>p</i> = 0.0001	> HC: <i>p</i> = 0.0001					
<i>Post-hoc</i>	> ARMS-ST: <i>p</i> = 0.0001						
<i>Post-hoc</i>	> ARMS-LT: <i>p</i> = 0.019						
BPRS 10, mean (s.d.)	3.5 (2.0)	1.94 (1.2)	1.4 (1.0)	1.0 (0)	<i>F</i> = 12.245	60	<0.0001
<i>Post-hoc</i>	4.0 (2.1) ^a	1.87 (1.2) ^a					
<i>Post-hoc</i>	> HC: <i>p</i> = 0.0001	> HC: <i>p</i> = 0.018					
<i>Post-hoc</i>	> ARMS-ST: <i>p</i> = 0.004						
<i>Post-hoc</i>	> ARMS-LT: <i>p</i> = 0.0001						
BPRS 11, mean (s.d.)	4.0 (1.7)	2.3 (1.4)	1.4 (0.8)	1.0 (0)	<i>F</i> = 20.172	60	<0.0001
<i>Post-hoc</i>	4.4 (1.9) ^a	2.2 (1.4) ^a					
<i>Post-hoc</i>	> HC: <i>p</i> = 0.0001	> HC: <i>p</i> = 0.008					
<i>Post-hoc</i>	> ARMS-ST: <i>p</i> = 0.001						
<i>Post-hoc</i>	> ARMS-LT: <i>p</i> = 0.019						
BPRS 15, mean (s.d.)	2.2 (1.3)	1.7 (0.9)	1.3 (0.9)	1.0 (0)	<i>F</i> = 4.777	60	<0.005
<i>Post-hoc</i>	2.2 (1.6) ^a	1.6 (0.9) ^a					
<i>Post-hoc</i>	> HC: <i>p</i> = 0.003						
APS, mean (s.d.)	13.2 (4.1)	8.4 (3.3)	5.8 (2.5)	4.0 (0)	<i>F</i> = 32.304	60	<0.0001
<i>Post-hoc</i>	> HC: <i>p</i> = 0.0001	> HC: <i>p</i> = 0.0001	< FEP: <i>p</i> = 0.0001				
<i>Post-hoc</i>		< FEP: <i>p</i> = 0.0001					

SANS total, mean (s.d.)	28.4 (15.8)	21.0 (13.1)	11.3 (16.6)	0	F = 16.130	61	<0.0001
<i>Post-hoc</i>	> HC: $p < 0.0001$	> HC: $p < 0.0001$	< FEP: $p = 0.006$ > HC: $p = 0.100$				
GAF, mean (s.d.)	49.6 (17.8)	59.9 (12.9)	76.0 (13.5)	88.6 (4.5)	F = 30.990	62	<0.0001
<i>Post-hoc</i>	< HC: $p = 0.0001$ < ARMS-LT: $p = 0.0001$	< HC: $p < 0.0001$ < ARMS-LT: $p = 0.006$	< HC: $p = 0.051$				

FEP, First episode of psychosis; ARMS, at-risk mental state; ARMS-LT, long-term ARMS; ARMS-ST, short-term ARMS; MWT-B, multiple choice vocabulary IQ test (Mehrfachwahl-Wortschatz-Intelligenztest, Form B); BPRS, Brief Psychiatric Rating Scale (item 9 suspiciousness, 10 hallucinations, 11 unusual thought content, 15 conceptual disorganization); APS, attenuated psychotic symptoms; SANS, Scale for the Assessment of Negative Symptoms; GAF, Global Assessment of Functioning; HC, healthy controls; df, degrees of freedom.

For *post-hoc* analyses, the Bonferroni correction (at $p = 0.05$) in SPSS 19.0 was calculated.
^a Values obtained on repeating the demographic analysis after exclusion of all individuals with a history of antipsychotic medication. Antipsychotic-naive FEP showed slightly higher BPRS and better GAF scores than FEP with antipsychotic history.

for homogeneity across the sample; and (5) using 8-mm standard smoothing. We identified two subjects with a mean covariance below two standard deviations and screened their volumes carefully, but found no artefacts and the quality of images was reasonable. We repeated the analyses without these two subjects, with the same results, and therefore decided not to exclude them from the analysis. After this pre-processing, we obtained segmented, normalized and smoothed data that were used for the statistical analysis.

We performed an analysis of covariance (ANCOVA) to compare grey matter images from all four groups (FEP, ARMS-ST, ARMS-LT, HC). We modelled age, gender and total GMV as covariates of no interest to reduce the potential impact of these variables on the findings. Statistical significance was assessed at cluster level using the non-stationary random field theory (Hayasaka *et al.* 2004). The first step of this cluster-level inference strategy consisted of identifying spatially contiguous voxels at a threshold of $p < 0.001$, uncorrected (cluster-forming threshold) (Pettersson *et al.* 1999). Statistical inferences were then made at $p < 0.05$ after family-wise error (FWE) correction. Additionally, we calculated effect size (Cohen's *d*) for volumetric differences in bilateral insular volumes.

To label the regions of brain activation, Montreal Neurological Institute (MNI) coordinates were transformed into Talairach space (www.ebire.org/hcnlab/cortical-mapping; Talairach Daemon software).

Correlation of GMV and clinical data

In addition to the whole-brain VBM analysis, correlation analyses were used to examine associations between GMV and scales measuring clinical symptoms (positive, negative and global functioning). We chose two areas with between-group volumetric differences that stayed stable even after exclusion of seven antipsychotic-free individuals.

To examine the association between positive and negative symptoms and global functioning, we extracted grey matter values from the peak voxels [(39, -19, 7) and (-33, -21, 10)] with sphere 2 mm and performed a series of two-tailed Pearson's correlation analyses using SPSS version 19.0 (SPSS Inc., USA); see online Supplementary Table S2. The statistical threshold was set at $p < 0.05$.

Statistical analysis of demographic data

We examined clinical and sociodemographic differences between groups using one-way analysis of variance (ANOVA), the *F* test or the χ^2 test (Table 1). For *post-hoc* analyses we used multiple two-sided

t tests with Bonferroni's correction. Statistical analyses were performed with SPSS version 19.0 and the level of significance was set at $p < 0.05$.

Results

Clinical and demographic characteristics

There were no significant differences between the FEP, ARMS-ST, ARMS-LT and HC groups in age ($p = 0.637$), gender ($p = 0.091$), handedness ($p = 0.603$), IQ ($p = 0.054$) and current cannabis use ($p = 0.550$; Table 1). The groups of patients did not differ in terms of antidepressant medication: 25% in the FEP group, 33.3% in the ARMS-ST group and 46.2% in ARMS-LT group were receiving antidepressants ($p = 0.488$). We found a significant difference in cigarette smoking ($F = 3.187$, $p = 0.030$). *Post-hoc* analysis showed that the FEP patients smoked more cigarettes compared to the HC ($p = 0.012$). We repeated demographic analysis after exclusion of all individuals with a history of antipsychotic medication (seven patients: six FEP and one ARMS-ST). The difference in cigarette smoking disappeared when we excluded these seven patients ($F = 1.614$, $p = 0.197$).

There were significant between-group differences in positive and negative symptoms and in global functioning. These differences corresponded to the clinical status (FEP > ARMS-ST > ARMS-LT) compared to the HC group. The ARMS-ST group showed lower GAF scores compared to the ARMS-LT group ($p = 0.004$). Both ARMS groups differed significantly in BPRS, SANS and GAF scores compared to the HC group (Table 1). Antipsychotic-naïve FEP (FEP after exclusion of individuals with a history of antipsychotic medication) showed slightly higher BPRS and lower SANS and GAF compared to the FEP with antipsychotic history.

GMV differences (VBM results)

GMV differences between groups are presented in Table 2 and group-specific deviations from the overall mean in online Supplementary Table S1.

Psychosis-associated volumetric abnormalities

The FEP individuals compared to the whole group of ARMS showed less GMV in the left uncus, parahippocampal gyrus and right middle temporal gyrus (Table 2, $p < 0.05$, FWE corrected). Both ARMS-ST and ARMS-LT had more GMV in the left parahippocampal gyrus when tested separately as compared to the FEP group.

In the FEP group we found more GMV in the right thalamus and superior frontal gyrus, and in the left

caudate, insula, superior frontal and cingulate gyrus compared to the entire ARMS group. Compared to the ARMS-ST group, the FEP had more GMV in the bilateral insula and superior frontal gyrus. Compared to the ARMS-LT, the FEP showed more GMV in the left caudate and superior frontal gyrus.

Volumetric abnormalities associated with antipsychotic medication

At the time of the study, none of the included individuals were receiving any antipsychotic medication. However, there were seven antipsychotic-free patients (six in the FEP and one in the ARMS-ST group), who had a history of antipsychotic medication, receiving low doses of atypical antipsychotics (five of them aripiprazole, two olanzapine and one risperidone; the duration of atypical antipsychotic medication use was 1–60 months; withdrawal 1–24 months ago). We repeated our analysis after exclusion of these seven individuals and found that the majority of volumetric differences had lost their significance. The 10 antipsychotic-naïve FEP patients did not show any volumetric abnormalities compared to either the entire ARMS group or the ARMS-LT group or the HC group. Only one cluster in the left insula ($-33 -21 10$) remained significant and showed more GMV on comparing the FEP to the ARMS-ST group (Table 2, $p < 0.05$, FWE corrected) with large effect size (Cohen's d 1.81).

Consequently, we compared antipsychotic-naïve FEP ($n = 10$) and FEP subjects with a previous history of antipsychotic use ($n = 15$: $n = 6$ antipsychotic-free and $n = 9$ currently receiving atypical antipsychotics; these are not included in this study). We found less GMV in medicated FEP compared to the antipsychotic-naïve FEP group in the right thalamus [$(3, -21, -2)$, $p = 0.032$, FWE corrected] and right parahippocampal gyrus [$(33, -1, -15)$, $p = 0.041$, FWE corrected].

Volumetric abnormalities in the ARMS-LT v. ARMS-ST

Compared to the ARMS-LT group, the ARMS-ST group had less GMV in the right insula (Table 2, $p < 0.05$, FWE corrected), with a Cohen's d of 1.67 (large effect). Conversely, the ARMS-LT had more GMV in the right insula compared to the HC (Table 2, $p < 0.05$, FWE corrected), with an effect size (Cohen's d) of 1.54 (large effect).

Correlation analyses of GMV and clinical outcomes

Within the whole ARMS group (ARMS-LT + ARMS-ST) there was a negative correlation ($p < 0.05$) between negative symptoms (SANS total score) and GMV in

Table 2. Group differences in brain structure

Contrast	$p_{\text{FWE corr.}}$	Cluster	T	MNI (x, y, z)	Region
FEP < ARMS ^a	0.002		6.16	-18, -9, -39	L Uncus
	0.007		5.86	-15, -16, -33	L Parahippocampal G (BA 28)
	0.047		5.25	36, -1, -35	R MTG (BA 21)
FEP > ARMS	0.014	631	5.42	14, -27, -6	R Thalamus
	0.005	790	4.68	-18, -19, 21	L Caudate
	0.042	483	4.74	18, 21, 58	R SFG
	0.049	463	4.92	-44, -15, 16	L Insula (BA 13)
	0.005	784	4.49	-6, 20, 61	L SFG
	0.027	541	4.11	-9, -12, 42	L CG
FEP < ARMS-ST ^a	0.014		5.64	-18, -9, -31	L Parahippocampal G (BA 35)
FEP > ARMS-ST	0.005	793	5.12	-33, -21, 10	L Insula (BA 13) ^b
	0.015	626	4.84	-34, 44, 27	L SFG
	0.020	584	4.81	18, 20, 58	R SFG
	0.012	650	4.80	36, -9, 10	R Insula (BA 13)
	0.013	640	4.39	8, 15, -23	R medial FG
FEP < ARMS-LT ^a	0.023	5.48		-15, -16, -33	L Parahippocampal G
FEP > ARMS-LT	0.003	871	4.81	-6, 23, 60	L SFG
	0.013	647	4.39	-20, -21, 21	L Caudate
ARMS-ST < ARMS-LT	0.002	921	4.44	39, -19, 7	R Insula (BA 13) ^b
ARMS-LT > HC	0.005	790	4.15	34, -27, 22	R Insula (BA 13) ^b
FEP < HC ^a	0.019	5.55		14, 15, 43	R CG (BA 32)
FEP > HC	0.040	489	4.58	-42, -15, 16	L Insula (BA 13)

FEP, First episode of psychosis; ARMS, at-risk mental state; ARMS-LT, long-term ARMS; ARMS-ST, short-term ARMS; FWE, family-wise error; MNI, Montreal Neurological Institute; L, left; R, right; G, gyrus; HC, healthy controls; BA, Brodmann area; MTG, middle temporal gyrus; SFG, superior frontal gyrus; CG, cingulate gyrus.

Group differences in grey matter volume (GMV) calculated from full factorial ANCOVA using SPM8 with the VBM8 toolbox with covariates age, gender, and VBM-GMV with cluster forming p value uncorrected $p < 0.001$.

There were no significant differences in contrasts: ARMS-ST > ARMS-LT, ARMS-LT < HC, (ARMS-ST + ARMS-LT) < HC, (ARMS-ST + ARMS-LT) > HC, ARMS-ST < HC, ARMS-ST > HC.

^a Differences were not significant at cluster level only at voxel level.

We repeated the analysis after exclusion of patients with a history of previous antipsychotic medication (currently antipsychotic-free subjects: six FEP and one ARMS-ST) to exclude the confounding effect of previous antipsychotic medication. The differences lost their significance in contrasts: FEP < ARMS, FEP > ARMS, FEP < ARMS-ST, FEP < ARMS-LT, FEP > ARMS-LT, and FEP < HC, FEP > HC. The only volumetric difference in the left insula (-33 -21 10) stayed significantly different after exclusion of seven antipsychotic-free subjects in contrast FEP > ARMS-ST ($p = 0.028$).

^b The difference was significant even after exclusion of antipsychotic-free individuals (six FEP and one ARMS-ST).

the right insula [(39, -19, 7), Pearson's correlation coefficient -0.411, Fig. 1] and in the left insula [(-33, -21, 10), Pearson's correlation coefficient -0.460, Fig. 2, online Supplementary Table S2]. Global functioning (GAF total score) correlated positively ($p < 0.01$) with GMV in the right insula [(39, -19, 7), Pearson's correlation coefficient 0.473, Fig. 1] and in the left insula [(-33, -21, 10), Pearson's correlation coefficient 0.502, Fig. 2] within the whole ARMS group. We found a positive correlation ($p < 0.05$) with global functional decline in the ARMS-LT group in the right insula [(39, -19, 7), Pearson's correlation coefficient 0.633; $p < 0.05$]. There were no significant correlations between positive symptoms (BPRS total score) and GMV in the whole ARMS group. When the above correlations were repeated within the

ARMS-ST, we found a significant relationship between GMV and hallucinations ($p < 0.05$) in the left insula [(-33, -21, 10), Pearson's correlation coefficient 0.502 and 0.564 respectively, Fig. 2, Supplementary Table S2] and conceptual disorganization in the right insula [(39, -19, 7), Pearson's correlation coefficient -0.533, Fig. 1, Supplementary Table S2]. The ARMS-LT group showed a positive correlation between GMV and hallucinations in the right insula [(39, -19, 7), Pearson's correlation coefficient 0.720; $p < 0.01$, Fig. 1, Supplementary Table S2].

Discussion

We used structural MRI to examine individuals with FEP, individuals at high clinical risk of psychosis

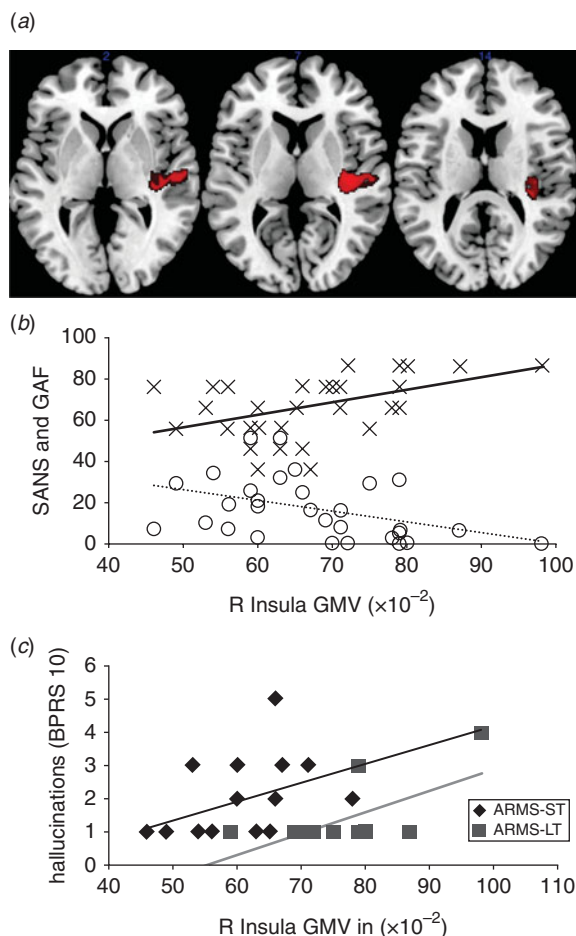


Fig. 1. Correlation of psychopathology and grey matter volume (GMV) in the right (R) insula. (a) The cluster in the right insula (39, -19, 7) reflects reduced GMV in the short-term at-risk mental state (ARMS-ST) compared to the long-term ARMS (ARMS-LT) group (39, -19, 7) [$p < 0.05$ family-wise error (FEW) corrected]. (b) Correlation of psychopathology and GMV in this cluster across the whole ARMS sample (ARMS-LT + ARMS-ST) [Pearson's correlation coefficient is -0.411 ($p = 0.05$ two-tailed)] for Scale for the Assessment of Negative Symptoms (SANS) and 0.473 ($p = 0.01$ two-tailed) for Global Assessment of Functioning (GAF)]. (c) Positive correlation with hallucinations [Pearson's correlation coefficient for Brief Psychiatric Rating Scale (BPRS) item 10 (hallucinations) is 0.564 ($p = 0.05$ two-tailed) for ARMS-ST and 0.632 ($p = 0.05$ two-tailed) for ARMS-LT]. The left side of the brain is shown on the left side of the image.

(ARMS) and healthy controls. The ARMS subjects were subcategorized according to different duration of ARMS and probability for transition to psychosis and then scanned with MRI. We compared short- and long-term ARMS individuals who differed in the duration of the ARMS status and consecutively in the probability to transit. The ARMS-ST group showed less right insular GMV than the ARMS-LT group.

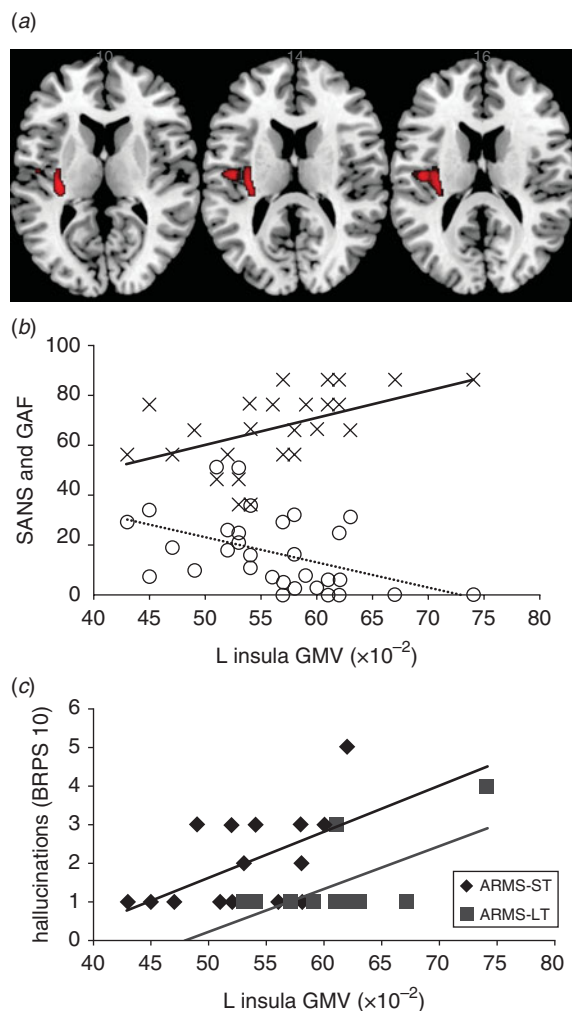


Fig. 2. Correlation of psychopathology and grey matter volume (GMV) in the left (L) insula. (a) The cluster in the left insula (-31 -21 10) reflects more GMV in the first episode of psychosis (FEP) compared to the short-term at-risk mental state (ARMS-ST) group [$p < 0.05$ family-wise error (FEW) corrected]. (b) Correlation of psychopathology and GMV in this cluster across the whole ARMS sample [long-term ARMS (ARMS-LT) + ARMS-ST; Pearson's correlation coefficient is -0.460 ($p = 0.05$ two-tailed) for Scale for the Assessment of Negative Symptoms (SANS) and 0.502 ($p = 0.01$ two-tailed) for Global Assessment of Functioning (GAF)]. (c) Positive correlation of hallucinations with GMV in the ARMS-ST group [Pearson's correlation coefficient for Brief Psychiatric Rating Scale (BPRS) item 10 (hallucinations) is 0.564 ($p = 0.05$ two-tailed) for ARMS-ST and 0.632 ($p = 0.05$ two-tailed) for ARMS-LT]. The left side of the brain is shown on the left side of the image.

Alterations in the right insula related to negative symptomatology and global functioning in the whole ARMS group, and to hallucinations and conceptual disorganization in the ARMS-LT and ARMS-ST subgroups respectively. Moreover, we found a significant

effect of previous antipsychotic medication use on brain volumetric changes.

Volumetric differences associated with psychosis

In line with previous MRI studies we found that FEP patients showed volumetric reductions in the cingulate gyrus relative to controls and in the parahippocampal gyrus compared to the ARMS groups and HC (for meta analyses, see: Glahn *et al.* 2008; Ellison-Wright & Bullmore, 2010). These alterations can be interpreted as state-marker risk factors for the disease and are qualitatively similar to those seen in patients with chronic schizophrenia (Ellison-Wright *et al.* 2008). However, we also found more GMV in subcortical regions (thalamus and caudate) in the FEP group compared to the whole ARMS group and to the ARMS-LT subgroup. These differences lost statistical significance after exclusion of individuals with any history of antipsychotic medication. However, not only subcortical regions showed more GMV in the FEP group compared to the ARMS group. The FEP group showed more GMV in bilateral superior frontal and insular regions compared to the ARMS and ARMS-ST groups. The changes in these regions are probably associated with long-lasting effects of previous treatment with antipsychotics (Ho *et al.* 2011). After exclusion of all patients who were ever receiving antipsychotics, only one cluster in the left insula remained significant. Contrary to our findings, insular atrophy associated with auditory hallucinations, with delusions and with the duration of schizophrenia (Kurth *et al.* 2010; Cascella *et al.* 2011; Nickl-Jockschat *et al.* 2011) was reported recently. Thus, intriguingly, more GMV in the left insula may be associated with the onset of psychosis, which is in contrast to evidence of reduced GMV in the prodromal phase and the chronic phase of psychosis (Smieskova *et al.* 2010). However, the increased insula volume in FEP compared to ARMS is associated specifically with the transition phase, which may account for this discrepancy. This result corresponds to brain swelling described in fronto-temporal brain regions during exacerbation of psychosis (Garver *et al.* 2000) and to blood-brain barrier dysfunction in schizophrenia (Uranova *et al.* 2010). A higher water diffusion coefficient in the fronto-temporal regions has been reported in schizophrenia (Shin *et al.* 2006). Astrocytes, altered in psychosis, are involved in the permeability of the blood-brain barrier and regulation of water homeostasis (del Zoppo & Hallenbeck, 2000). Thus, altered function in cerebral microvasculature at the ultrastructural level may play an important role in psychosis (Uranova *et al.* 2010). Additionally, it may be speculated that increases in regional brain volume in

high-risk populations may reflect timely delayed and spatially expanded synaptic pruning as a compensatory mechanism for earlier pre/postnatal disruptions (Ettinger *et al.* 2011).

Volumetric differences associated with previous antipsychotic medication

The effect of antipsychotic medication on brain structure and function has been underestimated for a long period of time. The influence of antipsychotics on brain structure is not entirely clear; however, antipsychotics may affect GMV (Dazzan *et al.* 2005; Navari & Dazzan, 2009; Ho *et al.* 2011), as reported specifically for the basal ganglia (Smieskova *et al.* 2009). Antipsychotics may contribute to volumetric brain reductions involving multiple subregions, and to specific volumetric increase in subcortical regions, as described in a longitudinal study with 211 patients (Ho *et al.* 2011). The patients included in that study were medicated and followed up for an average of 7 years. Our FEP patients received lower doses of antipsychotics for a shorter time and were not medicated at least 1 month ago. The differences we detected might reflect long-lasting changes in brain volume caused by previous antipsychotic medication but also reparatory/compensatory changes started after the withdrawal of the treatment. The changes associated with antipsychotic medication may be reversible, as shown in a study with healthy volunteers who received haloperidol injection (Tost *et al.* 2010). The temporarily diminished GMVs in the striatum returned to almost their original size within a day (Tost *et al.* 2010). However, we are aware that the influence of medication and the process of the disease itself are changing over time. Such complex processes cannot be entirely explained using a cross-sectional design and need to be studied longitudinally.

Volumetric differences associated with vulnerability to transition probability to psychosis

We found no significant differences between HC and the whole ARMS group or ARMS-ST subgroup. Comparing ARMS-LT and HC revealed more GMV in the right insular region. This finding is in line with previous published volumetric abnormalities found in ARMS (Borgwardt *et al.* 2007b, 2008; Meisenzahl *et al.* 2008; Koutsouleris *et al.* 2009; for a review of VBM studies in high-risk subjects see Fusar-Poli *et al.* 2011a).

Moreover, there was a difference in the right insular volume between ARMS-ST and ARMS-LT associated with different transition probabilities. Compared to ARMS-LT individuals, ARMS-ST showed reduced GMV, corresponding to the reductions seen in ARMS

subjects who later transit to psychosis (Borgwardt *et al.* 2007b; Takahashi *et al.* 2009b). Such alterations may represent the neurobiological substrate of different transition probabilities within the ARMS. Furthermore, GVM alteration in the insula may be associated directly with the consistent neurofunctional alterations observed in the ARMS during cognitive tasks (Fusar-Poli *et al.* 2011b).

By comparing the ARMS-LT and HC groups, we revealed more right insular volume than volume reductions. This might reflect associations with protecting factors in the transition process to psychosis in addition to a different dynamics of underlying protective and/or psychosis-associated changes in the brains of ARMS and FEP individuals. At a symptoms level, we showed that negative symptoms correlated negatively and global functioning positively with volumetric differences within the ARMS subjects. Positive symptoms correlated positively with GMV in ARMS-ST and hallucinations in both ARMS-ST and ARMS-LT groups.

Comparing the ARMS-LT to the HC and to the ARMS-ST subjects revealed more volume in the right insula. Thus the insular GMV increase may represent activity-related hypertrophy (Draganski *et al.* 2006) secondary to neurofunctional activation of insular areas when experiencing auditory hallucinations (O'Daly *et al.* 2007).

Repeating the analysis with antipsychotic-naive FEP only, we found more GMV in the left insula compared to the ARMS-ST. However, we cannot distinguish those antipsychotic-naive FEP who had better internal resources from those FEP who were diagnosed recently (with a higher hallucination score) and had not yet received their antipsychotic medication.

Clinical implications and correlation with clinical outcomes

The mean duration of the ARMS was 4.5 years in the ARMS-LT group; the probability that any of these subjects will develop psychosis in the future is low (Cannon *et al.* 2008; Riecher-Rössler *et al.* 2009). In the ARMS-ST subjects, we expect a transition rate of approximately 30% (Riecher-Rössler *et al.* 2009) in the next 1 to 2 years. The ARMS-ST group with 30% probability of subsequently developing psychosis allows the investigation of vulnerability and higher transition probability-associated changes in brain activation compared to the HC. Of note, our ARMS-LT did not differ from the ARMS-ST with respect to age; this might be because of the small sample sizes and needs further investigation (Whitwell, 2009). However, the differences between ARMS-ST and ARMS-LT did not refer with regard to the effect of

ageing in one of those groups. The structural abnormalities we observed were not attributable to anti-psychotic treatment, as all of the ARMS individuals were antipsychotic naive except for one ARMS-ST subject who was antipsychotic free at the time of scanning. Consequently, we suggest that the volumetric difference between these two groups reflects both disrupted brain structure and protective processes. It remains to be determined whether the structural abnormalities we found are reversible or compensatory in nature. Some recent studies suggest reversibility of prodromal symptoms, especially in an adolescent high-risk group (Simon & Umbricht, 2010).

As hypothesized, we found a correlation between volumetric differences and positive and negative psychotic symptoms. Negative symptoms correlated negatively with the GMV in the insula within our whole ARMS population. There was a positive correlation of GMV changes with positive symptoms in the ARMS-ST group and with hallucinations in both ARMS-ST and ARMS-LT groups. Of note, there was a negative correlation with conceptual disorganization in the ARMS-LT group. Previously studies have reported negative correlations (Crespo-Facorro *et al.* 2000; Pressler *et al.* 2005), no correlation (Takahashi *et al.* 2005; Crespo-Facorro *et al.* 2010) and a positive correlation (Takahashi *et al.* 2009a) between positive symptoms and GMV in schizophrenia patients.

GMV in the bilateral insula correlated positively with global functioning within the whole ARMS group. This is in line with previous behavioural reports indicating that the duration of prodromal symptoms predicts the longitudinal GAF scores in subjects with an ARMS (Fusar-Poli *et al.* 2009).

Limitations

Some limitations of this study should be considered. First, although the ARMS-ST group had a 20–40% probability of transition to psychosis, there was a high false-positive probability of approximately 60–80%. Our two groups had a different inherent risk for the development of illness: 20–40% in the ARMS-ST group and 2–4% in the ARMS-LT group. A comparison of those who had converted (that is had 100% risk of transition) could give us a much more concrete differentiation in risk. However, our ARMS-ST group showed similar volumetric deficits to ARMS individuals who subsequently transitioned. Thus, the ARMS-ST with volumetric deficits in the right insula at the very beginning of their risk state may be associated with a higher transition probability subsequently. If this finding is confirmed in longitudinal studies, insular abnormalities may be an important neuroimaging marker of higher probability to

psychosis. Second, most of the ARMS-ST individuals could become ARMS-LT in several months, and with the aim of revealing the longitudinal differences in the same individuals, we should scan them again in 4.5 years. Third, our healthy volunteers had no family history of any psychiatric disorder among first- and second-degree relatives, as assessed in a detailed questionnaire. Thus, given the very high prevalence rates of mental illness in almost every family, our group could be seen as an exceptional group of healthy controls. Fourth, the exact meaning of brain tissue loss or increase in the period of life when the young adult brain is maturing and eliminating superfluous synapses is very complex. In addition, confounding factors including antidepressant medication, smoking, consumption of alcohol and cannabis, and socioeconomic status may have influenced the results (Cardenas *et al.* 2007). However, although alcohol use differed significantly between groups, there was no difference with respect to antidepressant or cannabis use. Fifth, the use of VBM methodology implicates problems of brain registration and the size of the smoothing kernel, especially when relatively small differences are expected. The exact meaning of the volumetric abnormalities (exaggerated dendritic pruning, impaired myelination, apoptosis of neuropil) is not entirely clear. Nevertheless, this technique allows comparisons of the entire brain volume at the single voxel level and we used the improved segmentation and normalization SPM8 protocols in our analyses.

Conclusions

Structural alterations in subjects at high clinical risk for psychosis are associated with negative and positive psychotic symptoms, and impairment in global functioning. Specific GMV abnormalities within the ARMS may distinguish different transition probabilities. In particular, volume loss in the right insula is associated with a higher risk for transition to psychosis.

Note

Supplementary material accompanies this paper on the Journal's website (<http://journals.cambridge.org/psm>).

Acknowledgements

We thank the subjects who took part in this study and also the FEPSY study group for recruitment and management of participants. R.S. and S.J.B. were supported by the Swiss National Science Foundation (No. 3232BO_119382).

Declaration of Interest

None.

References

- Ashburner J (2007). A fast diffeomorphic image registration algorithm. *NeuroImage* **38**, 95–113.
- Borgwardt SJ, McGuire PK, Aston J, Berger G, Dazzan P, Gschwandtner U, Pflüger M, D'Souza M, Radue EW, Riecher-Rössler A (2007a). Structural brain abnormalities in individuals with an at-risk mental state who later develop psychosis. *British Journal of Psychiatry. Supplement* **51**, s69–s75.
- Borgwardt SJ, McGuire PK, Aston J, Gschwandtner U, Pflüger MO, Stieglitz RD, Radue EW, Riecher-Rössler A (2008). Reductions in frontal, temporal and parietal volume associated with the onset of psychosis. *Schizophrenia Research* **106**, 108–114.
- Borgwardt SJ, Riecher-Rössler A, Dazzan P, Chitnis X, Aston J, Drewe M, Gschwandtner U, Haller S, Pflüger M, Rechsteiner E, D'Souza M, Stieglitz RD, Radue EW, McGuire PK (2007b). Regional gray matter volume abnormalities in the at risk mental state. *Biological Psychiatry* **61**, 1148–1156.
- Breitborde NJ, Srihari VH, Woods SW (2009). Review of the operational definition for first-episode psychosis. *Early Intervention in Psychiatry* **2009**, 259–265.
- Brewer WJ, Wood SJ, Phillips LJ, Francey SM, Pantelis C, Yung AR, Cornblatt B, McGorry PD (2006). Generalized and specific cognitive performance in clinical high-risk cohorts: a review highlighting potential vulnerability markers for psychosis. *Schizophrenia Bulletin* **32**, 538–555.
- Cannon TD, Cadenhead K, Cornblatt B, Woods SW, Addington J, Walker E, Seidman LJ, Perkins D, Tsuang M, McGlashan T, Heinssen R (2008). Prediction of psychosis in youth at high clinical risk: a multisite longitudinal study in North America. *Archives of General Psychiatry* **65**, 28–37.
- Cardenas VA, Studholme C, Gazdzinski S, Durazzo TC, Meyerhoff DJ (2007). Deformation-based morphometry of brain changes in alcohol dependence and abstinence. *NeuroImage* **34**, 879–887.
- Cascella NG, Gerner GJ, Fieldstone SC, Sawa A, Schretlen DJ (2011). The insula-claustrum region and delusions in schizophrenia. *Schizophrenia Research*. Published online: 27 August 2011. doi:10.1016/j.schres.2011.08.004.
- Crespo-Facorro B, Kim J, Andreasen NC, O'Leary DS, Bockholt HJ, Magnotta V (2000). Insular cortex abnormalities in schizophrenia: a structural magnetic resonance imaging study of first-episode patients. *Schizophrenia Research* **46**, 35–43.
- Crespo-Facorro B, Roiz-Santianez R, Quintero C, Perez-Iglesias R, Tordesillas-Gutierrez D, Mata I, Rodriguez-Sanchez JM, Gutierrez A, Vazquez-Barquero JL (2010). Insular cortex morphometry in first-episode schizophrenia-spectrum patients: diagnostic specificity and clinical correlations. *Journal of Psychiatric Research* **44**, 314–320.

- Dazzan P, Morgan KD, Orr K, Hutchinson G, Chitnis X, Suckling J, Fearon P, McGuire PK, Mallett RM, Jones PB, Leff J, Murray RM (2005). Different effects of typical and atypical antipsychotics on grey matter in first episode psychosis: the AESOP study. *Neuropsychopharmacology* **30**, 765–774.
- del Zoppo GJ, Hallenbeck JM (2000). Advances in the vascular pathophysiology of ischemic stroke. *Thrombosis Research* **98**, 73–81.
- Draganski B, Gaser C, Kempermann G, Kuhn HG, Winkler J, Buchel C, May A (2006). Temporal and spatial dynamics of brain structure changes during extensive learning. *Journal of Neuroscience* **26**, 6314–6317.
- Ellison-Wright I, Bullmore E (2010). Anatomy of bipolar disorder and schizophrenia: a meta-analysis. *Schizophrenia Research* **117**, 1–12.
- Ellison-Wright I, Glahn DC, Laird AR, Thelen SM, Bullmore E (2008). The anatomy of first-episode and chronic schizophrenia: an anatomical likelihood estimation meta-analysis. *American Journal of Psychiatry* **165**, 1015–1023.
- Ettinger U, Williams SC, Fannon D, Premkumar P, Kuipers E, Moller HJ, Kumari V (2011). Functional magnetic resonance imaging of a parametric working memory task in schizophrenia: relationship with performance and effects of antipsychotic treatment. *Psychopharmacology* **216**, 17–27.
- Frommann I, Pukrop R, Brinkmeyer J, Bechdorf A, Ruhrmann S, Berning J, Decker P, Riedel M, Moller HJ, Wolwer W, Gaebel W, Klosterkötter J, Maier W, Wagner M (2010). Neuropsychological profiles in different at-risk states of psychosis: executive control impairment in the early – and additional memory dysfunction in the late – prodromal state. *Schizophrenia Bulletin* **37**, 861–873.
- Fusar-Poli P, Borgwardt S, Crescini A, Deste G, Kempton MJ, Lawrie S, McGuire P, Sacchetti E (2011a). Neuroanatomy of vulnerability to psychosis: a voxel-based meta-analysis. *Neuroscience and Biobehavioral Reviews* **35**, 1175–1185.
- Fusar-Poli P, Broome MR, Woolley JB, Johns LC, Tabraham P, Bramon E, Valmaggia L, Williams SC, McGuire P (2011b). Altered brain function directly related to structural abnormalities in people at ultra high risk of psychosis: longitudinal VBM-fMRI study. *Journal of Psychiatric Research* **45**, 190–198.
- Fusar-Poli P, Meneghelli A, Valmaggia L, Allen P, Galvan F, McGuire P, Cocchi A (2009). Duration of untreated prodromal symptoms and 12-month functional outcome of individuals at risk of psychosis. *British Journal of Psychiatry* **194**, 181–182.
- Garver DL, Nair TR, Christensen JD, Holcomb JA, Kingsbury SJ (2000). Brain and ventricle instability during psychotic episodes of the schizophrenias. *Schizophrenia Research* **44**, 11–23.
- Glahn DC, Laird AR, Ellison-Wright I, Thelen SM, Robinson JL, Lancaster JL, Bullmore E, Fox PT (2008). Meta-analysis of gray matter anomalies in schizophrenia: application of anatomic likelihood estimation and network analysis. *Biological Psychiatry* **64**, 774–781.
- Haroun N, Dunn L, Haroun A, Cadenhead KS (2006). Risk and protection in prodromal schizophrenia: ethical implications for clinical practice and future research. *Schizophrenia Bulletin* **32**, 166–178.
- Hayasaka S, Phan KL, Liberzon I, Worsley KJ, Nichols TE (2004). Nonstationary cluster-size inference with random field and permutation methods. *NeuroImage* **22**, 676–687.
- Ho BC, Andreasen NC, Ziebell S, Pierson R, Magnotta V (2011). Long-term antipsychotic treatment and brain volumes: a longitudinal study of first-episode schizophrenia. *Archives of General Psychiatry* **68**, 128–137.
- Hurlemann R, Matusch A, Kuhn KU, Berning J, Elmenhorst D, Winz O, Kolsch H, Zilles K, Wagner M, Maier W, Bauer A (2008). 5-HT_{2A} receptor density is decreased in the at-risk mental state. *Psychopharmacology* **195**, 579–590.
- Jessen F, Scherk H, Traber F, Theyson S, Berning J, Tepest R, Falkai P, Schild HH, Maier W, Wagner M, Block W (2006). Proton magnetic resonance spectroscopy in subjects at risk for schizophrenia. *Schizophrenia Research* **87**, 81–88.
- Koutsouleris N, Schmitt GJ, Gaser C, Bottlender R, Scheuerecker J, McGuire P, Burgermeister B, Born C, Reiser M, Möller HJ, Meisenzahl EM (2009). Neuroanatomical correlates of different vulnerability states for psychosis and their clinical outcomes. *British Journal of Psychiatry* **195**, 218–226.
- Kurth F, Zilles K, Fox PT, Laird AR, Eickhoff SB (2010). A link between the systems: functional differentiation and integration within the human insula revealed by meta-analysis. *Brain Structure and Function* **214**, 519–534.
- Lencz T, Smith CW, Auther A, Correll CU, Cornblatt B (2004). Nonspecific and attenuated negative symptoms in patients at clinical high-risk for schizophrenia. *Schizophrenia Research* **68**, 37–48.
- Meisenzahl EM, Koutsouleris N, Gaser C, Bottlender R, Schmitt GJ, McGuire P, Decker P, Burgermeister B, Born C, Reiser M, Möller HJ (2008). Structural brain alterations in subjects at high-risk of psychosis: a voxel-based morphometric study. *Schizophrenia Research* **102**, 150–162.
- Navari S, Dazzan P (2009). Do antipsychotic drugs affect brain structure? A systematic and critical review of MRI findings. *Psychological Medicine* **39**, 1763–1777.
- Nickl-Jockschat T, Schneider F, Pagel AD, Laird AR, Fox PT, Eickhoff SB (2011). Progressive pathology is functionally linked to the domains of language and emotion: meta-analysis of brain structure changes in schizophrenia patients. *European Archives of Psychiatry and Clinical Neuroscience*. Published online: 10 September 2011. doi:10.1007/s00406-011-0249-8.
- O'Daly OG, Frangou S, Chitnis X, Shergill SS (2007). Brain structural changes in schizophrenia patients with persistent hallucinations. *Psychiatry Research* **156**, 15–21.
- Pantelis C, Velakoulis D, McGorry PD, Wood SJ, Suckling J, Phillips LJ, Yung AR, Bullmore ET, Brewer W, Soulsby B, Desmond P, McGuire PK (2003). Neuroanatomical abnormalities before and after onset of psychosis: a cross-sectional and longitudinal MRI comparison. *Lancet* **361**, 281–288.

- Petersson KM, Nichols TE, Poline JB, Holmes AP (1999). Statistical limitations in functional neuroimaging. II. Signal detection and statistical inference. *Philosophical Transactions of the Royal Society of London. Series B, Biological Sciences* **354**, 1261–1281.
- Pressler M, Nopoulos P, Ho BC, Andreasen NC (2005). Insular cortex abnormalities in schizophrenia: relationship to symptoms and typical neuroleptic exposure. *Biological Psychiatry* **57**, 394–398.
- Riecher-Rössler A, Aston J, Ventura J, Merlo M, Borgwardt S, Gschwandtner U, Stieglitz RD (2008). The Basel Screening Instrument for Psychosis (BSIP): development, structure, reliability and validity [in German]. *Fortschritte der Neurologie-Psychiatrie* **76**, 207–216.
- Riecher-Rössler A, Gschwandtner U, Aston J, Borgwardt S, Drewe M, Fuhr P, Pflüger M, Radü W, Schindler C, Stieglitz RD (2007). The Basel early-detection-of-psychosis (FEPSY)-study – design and preliminary results. *Acta Psychiatrica Scandinavica* **115**, 114–125.
- Riecher-Rössler A, Pflueger MO, Aston J, Borgwardt SJ, Brewer WJ, Gschwandtner U, Stieglitz RD (2009). Efficacy of using cognitive status in predicting psychosis: a 7-year follow-up. *Biological Psychiatry* **66**, 1023–1030.
- Shin YW, Kwon JS, Ha TH, Park HJ, Kim DJ, Hong SB, Moon WJ, Lee JM, Kim IY, Kim SI, Chung EC (2006). Increased water diffusivity in the frontal and temporal cortices of schizophrenic patients. *NeuroImage* **30**, 1285–1291.
- Simon AE, Cattapan-Ludewig K, Zmilacher S, Arbach D, Gruber K, Dvorsky DN, Roth B, Isler E, Zimmer A, Umbricht D (2007). Cognitive functioning in the schizophrenia prodrome. *Schizophrenia Bulletin* **33**, 761–771.
- Simon AE, Umbricht D (2010). High remission rates from an initial ultra-high risk state for psychosis. *Schizophrenia Research* **116**, 168–172.
- Smieskova R, Allen P, Simon A, Aston J, Bendfeldt K, Drewe J, Gruber K, Gschwandtner U, Klarhoefer M, Lenz C, Scheffler K, Stieglitz RD, Radue EW, McGuire P, Riecher-Rössler A, Borgwardt SJ (2011). Different duration of at-risk mental state associated with neurofunctional abnormalities. A multimodal imaging study. *Human Brain Mapping*. Published online: 16 September 2011. doi:10.1002/hbm.21360.
- Smieskova R, Fusar-Poli P, Allen P, Bendfeldt K, Stieglitz RD, Drewe J, Radue EW, McGuire PK, Riecher-Rössler A, Borgwardt SJ (2009). The effects of antipsychotics on the brain: what have we learnt from structural imaging of schizophrenia? A systematic review. *Current Pharmaceutical Design* **15**, 2535–2549.
- Smieskova R, Fusar-Poli P, Allen P, Bendfeldt K, Stieglitz RD, Drewe J, Radue EW, McGuire PK, Riecher-Rössler A, Borgwardt SJ (2010). Neuroimaging predictors of transition to psychosis – a systematic review and meta-analysis. *Neuroscience and Biobehavioral Reviews* **34**, 1207–1222.
- Sun D, Phillips L, Velakoulis D, Yung A, McGorry PD, Wood SJ, van Erp TG, Thompson PM, Toga AW, Cannon TD, Pantelis C (2009). Progressive brain structural changes mapped as psychosis develops in ‘at risk’ individuals. *Schizophrenia Research* **108**, 85–92.
- Takahashi T, Suzuki M, Zhou SY, Hagino H, Tanino R, Kawasaki Y, Nohara S, Yamashita I, Seto H, Kurachi M (2005). Volumetric MRI study of the short and long insular cortices in schizophrenia spectrum disorders. *Psychiatry Research* **138**, 209–220.
- Takahashi T, Wood SJ, Soulsby B, McGorry PD, Tanino R, Suzuki M, Velakoulis D, Pantelis C (2009a). Follow-up MRI study of the insular cortex in first-episode psychosis and chronic schizophrenia. *Schizophrenia Research* **108**, 49–56.
- Takahashi T, Wood SJ, Yung AR, Phillips LJ, Soulsby B, McGorry PD, Tanino R, Zhou SY, Suzuki M, Velakoulis D, Pantelis C (2009b). Insular cortex gray matter changes in individuals at ultra-high-risk of developing psychosis. *Schizophrenia Research* **111**, 94–102.
- Tost H, Braus DF, Hakimi S, Ruf M, Vollmert C, Hohn F, Meyer-Lindenberg A (2010). Acute D2 receptor blockade induces rapid, reversible remodeling in human cortical-striatal circuits. *Nature Neuroscience* **13**, 920–922.
- Uranova NA, Zimina IS, Vikhрева OV, Krukov NO, Rachmanova VI, Orlovskaya DD (2010). Ultrastructural damage of capillaries in the neocortex in schizophrenia. *World Journal of Biological Psychiatry* **11**, 567–578.
- Whitwell JL (2009). Voxel-based morphometry: an automated technique for assessing structural changes in the brain. *Journal of Neuroscience* **29**, 9661–9664.
- Witthaus H, Kaufmann C, Bohner G, Ozgur dal S, Gudlowski Y, Gallinat J, Ruhrmann S, Brune M, Heinz A, Klingebiel R, Juckel G (2009). Gray matter abnormalities in subjects at ultra-high risk for schizophrenia and first-episode schizophrenic patients compared to healthy controls. *Psychiatry Research* **173**, 163–169.
- Yassa MA, Stark CE (2009). A quantitative evaluation of cross-participant registration techniques for MRI studies of the medial temporal lobe. *NeuroImage* **44**, 319–327.
- Yung AR, Nelson B, Stanford C, Simmons MB, Cosgrave EM, Killackey E, Phillips LJ, Bechdolf A, Buckby J, McGorry PD (2008). Validation of ‘prodromal’ criteria to detect individuals at ultra high risk of psychosis: 2 year follow-up. *Schizophrenia Research* **105**, 10–17.
- Yung AR, Phillips LJ, McGorry PD, McFarlane CA, Francey S, Harrigan S, Patton GC, Jackson HJ (1998). Prediction of psychosis. A step towards indicated prevention of schizophrenia. *British Journal of Psychiatry. Supplement* **172**, 14–20.
- Yung AR, Phillips LJ, Yuen HP, McGorry PD (2004). Risk factors for psychosis in an ultra high-risk group: psychopathology and clinical features. *Schizophrenia Research* **67**, 131–142.
- Yung AR, Yuen HP, Berger G, Francey S, Hung TC, Nelson B, Phillips L, McGorry P (2007). Declining transition rate in ultra high risk (prodromal) services: dilution or reduction of risk? *Schizophrenia Bulletin* **33**, 673–681.