A Child With an FGFR3 Mutation, a Laterality Disorder and an Hepatoblastoma: Novel Associations and Possible Gene–Environment Interactions

Gareth S. Baynam and Jack Goldblatt

Genetic Services of Western Australia, Princess Margaret Hospital for Children and King Edward Memorial Hospital for Women, School of Paediatrics and Child Health, University of Western Australia, Australia

We report on a 3-year-old girl, from a 3-generation family with an FGFR3 Pro250Arg mutation, who in addition to craniosynostosis, had a laterality disorder and hepatoblastoma, following a pregnancy complicated by maternal insulin-dependent diabetes. The clinical features possibly result from the combined effects of the maternal diabetes and the familial FGFR3 mutation, thus representing a unique gene–environment interaction that may have implications for the understanding of the phenotypes described in this child.

Keywords: laterality, FGFR3, hepatoblastoma

Clinical Report

The proband was referred for genetic consultation at five months of age with bicoronal craniosynostosis. She was the result of the second pregnancy to a non-consanguineous Australian Caucasian couple. Their first pregnancy resulted in a first-trimester miscarriage. Maternal age was 32 and the paternal age 33 years. There was a 3-generation paternal family history consistent with an autosomal dominant syndromic craniosynostosis predominantly affecting the coronal sutures. The proband's mother had insulin-dependent diabetes mellitus, with a glycosylated hemoglobin of 6.8% ascertained during the pregnancy, suggesting reasonable diabetic control; and her father had bicoronal craniosynostosis, bilateral syndactyly of the first, second and third toes and mild unilateral hearing loss. The proband was delivered vaginally after a spontaneous labour at 30 weeks gestation. Her birthweight was 1610 g (90th percentile), her birth length was 44 cm (above the 90th percentile) and her birth head circumference was 28.5 cm (75th percentile). Her newborn period was complicated by post-hemorrhagic hydrocephalus, requiring ventriculo-peritoneal shunt and a small bowel perforation. Echocardiogram revealed an interrupted inferior vena cava with drainage via the hemiazygous vein and otherwise normal cardiac anatomy. Chest radiograph (Figure 1) and abdominal ultrasound demonstrated a right-sided stomach, midline liver and polysplenia. She developed oxygen dependency that resolved spontaneously by 21 months of age without a cause being ascertained. A chest CT was unremarkable and a pulmonary wedge biopsy showed minor architectural distortion of the alveolar lining, focal intramural thickening, lymphatic dilatation and no interstitial inflammation or fibrosis. Persistent feeding difficulties necessitated nasogastric feeding and there was emerging mild global developmental delay. Immunological investigations revealed a low total IgG.

On examination she had a large anterior fontanelle, proptosis, shallow orbits, hypertelorism, down-slanting palpebral fissures, low-set posteriorly rotated ears, a right convergent strabismus, a high palate, mild retrognathia and hyperconvex finger nails. At 17 months of age her length was 83cm (75th percentile), her weight was 10.65 kg (50th percentile) and her head circumference was 44.4 cm (2nd percentile).

A cranial MRI, performed at five weeks of age, displayed grossly dilated lateral, third and fourth ventricles with an evolving hematoma within the ventricular system and the left ventricle, focal hemorrhage in the frontal lobe with porencephaly on the left, as well as further porencephaly extending into the left parasagittal cerebral hemisphere.

As part of respiratory follow-up, a CT of the chest and abdomen was performed at two and a half years of age and demonstrated lesions consistent with a multifocal hepatoblastoma (Figure 2); a serum beta HCG was 19,000 kU/L and a liver biopsy was consistent with an hepatoblastoma. She was managed for

Received: March 20, 2010. Accepted: May 7, 2010.

Address for correspondence: Gareth Baynam, Genetic Services of Western Australia, Level 3 Agnes Walsh House, King Edward Memorial Hospital, 6008, Western Australia, Australia. E-mail: Gareth.Baynam@health.wa.gov.au

https://doi.org/10.1375/twin.13.4.297 Published online by Cambridge University Press

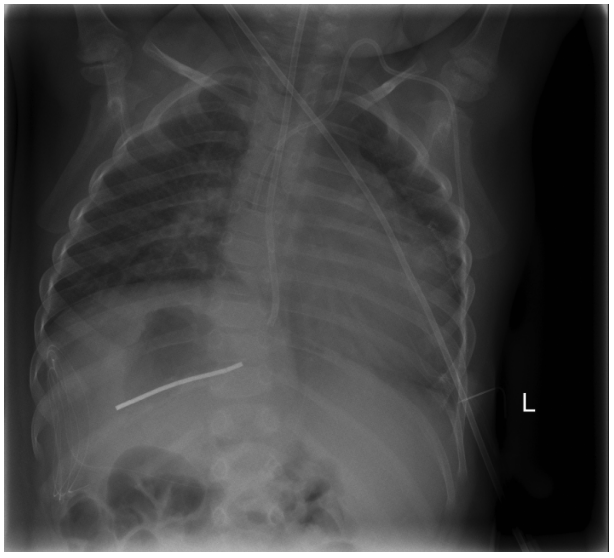

Figure 1

A chest x-ray demonstrating a left-sided liver and a right-sided stomach.

Figure 2

Abdominal computed tomography demonstrating an hepatoblastoma (white arrow) in the malpositioned liver.

the hepatoblastoma, with adjuvant chemotherapy prior to potential surgical resection.

Analysis of FGFR3 in the proband and her father, by genomic DNA sequencing, revealed c.749 C>G mutation consistent with the Pro250Arg mutation (methods available on request). Normal genetic investigations of the proband included a G-banded karyotype at the 550 band level, subtelomere MLPA (P036 MRC Holland©), PITX2 analysis ((MLPA (P054 MRC Holland©) and genomic DNA sequencing of the coding region (methods available on request)). PITX2 analysis was performed, concurrent with FGFR analysis, as this gene is important for determination of laterality in animal models (Ryan et al., 1998), and we have previously ascertained a PITX2 mutation in a child with craniosynostosis (unpublished observation).

Discussion

While the proband's laterality disorder and hepatoblastoma may be chance findings or be independently related to the FGFR3 mutation and the maternal diabetes, we describe the first report of these phenotypes occurring in a child with the FGFR3 Pro250Arg mutation to postulate that these may be rare associations occurring in a multifactorial manner in the context of maternal diabetes.

FGFR3 (fibroblast growth factor receptor 3) is one of a family of tyrosine kinase receptors (FGFR1–4) with roles in many aspects of embryogenesis and tissue homeostasis. The FGF signaling pathway regulates a multitude of biological processes, including proliferation, differentiation, migration and apoptosis (Friesel & Maciag, 1995; Johnson & Williams, 1993). It is also involved or implicated in developmental genetic diseases and cancer (Grose & Dickson, 2005; Ornitz & Marie, 2002).

Germline FGFR3 mutations are associated with a variety of autosomal dominant skeletal disorders including craniosynostoses and chondrodysplasias (Muenke et al., 1997; Passos-Bueno et al., 1999; Rousseau et al., 1994; Webster & Donoghue, 1997.). The mutations causing these disorders create auto-activated receptors (Ornitz & Marie, 2002; Passos-Bueno, et al., 1999). Murine in-vitro chondrocyte studies and loss- and gain-of-function experiments suggest that activated FGFR3c inhibits bone growth by impairing chondrocyte proliferation and modulating differentiation by triggering premature epiphyseal apoptosis (Ornitz & Marie, 2002). Contrary to this inhibitory role in bone growth, is a proposed pro-oncogenic role of mutated FGFR3. The same activating mutations causing FGFR3-associated chondrodysplasias have been identified in a variety of tumors, including hematological cancers, multiple myeloma, and carcinomas of the bladder and cervix (Cappellen et al., 1999; Chesi et al., 1997; Richelda et al., 1997). Additionally, studies of activating mutations in FGFR3 support a shared genetic origin of congenital disorders and testicular tumors (Goriely et al., 2009).

Furthermore, a role for FGFR3 in hepatic carcinogenesis has been suggested by the finding of its over-expression in hepatocellular carcinoma (Qiu et al., 2005) In this context, in our patient it is tempting to speculate that, as diabetes is a risk factor for hepatocellular carcinoma (Schutte et al., 2009), the maternal diabetes may have contributed to the pathogenesis of the hepatoblastoma. We acknowledge that FGFR3-related craniosynostosis syndromes in general have not previously been associated with malignancies, and the hepatoblastoma could be a coincidental finding. There

https://doi.org/10.1375/twin.13.4.297 Published online by Cambridge University Press

are many other genes in which germline mutations are associated with genetic disorders and in which mutations have been identified in tumors. For most of these there is no evidence of a tumor predisposition in people with the relevant syndrome, however, exceptions have been reported (Gripp et al., 2006).

Laterality disorders are etiologically heterogeneous with monogenic, polygenic or multifactorial causes (Peeters & Devriendt, 2006). Maternal diabetes is one established cause of laterality disorders (Aylsworth, 2001) and in murine models the induction of laterality phenotypes by maternal diabetes is influenced by fetal genotype (Morishima et al., 1996). The possibility that the FGFR3 mutation may be causally associated with this patient's laterality disorder, potentially via an interaction with the effects of maternal diabetes, is supported by the following: First, animal experiments have demonstrated that FGF signaling is important to body patterning and establishment of left-right asymmetry (Carl & Wittbrodt, 1999; Hong & Dawid, 2009; Tanaka et al., 2005); Second, molecules in the FGF signaling pathway have been implicated in ciliogenesis (Hong & Dawid, 2009; Neugebauer et al., 2009) and ciliary dysfunction is a known cause of human laterality disorders (Sutherland & Ware, 2009); Third, facial asymmetry can be seen in Saethre-Chotzen syndrome, and in one study approximately 20% of patients had the FGFR3 Pro250Arg mutation, (Paznekas et al., 1998) and it can also be seen in the ciliopathy oralfacialdigital syndrome type 1 (Prattichizzo et al., 2008). Further support for this postulated gene–environment interaction is that the Sonic Hedgehog (SHH) gene is important for laterality regulation (Cohen, 2001), SHH interacts with FGF signaling pathways (Fogarty et al., 2007) and SHH signaling in human macrophages was negatively affected by diabetes. Therefore, it is possible that the interaction effects of the FGFR mutation and the maternal diabetes on the laterality phenotype may converge at SHH-related signaling pathways.

As the phenotypic expression of the FGFR3 Pro250Arg mutation (Doherty & Muenke, 2009) and laterality disorders can be highly variable or subclinical, it is possible that investigation for mutations in this gene have not been considered in the setting of laterality phenotypes.

In conclusion, we describe the first reported associations of a laterality disorder and hepatoblastoma in a child with the FGFR3 Pro250Arg mutation, and postulate that the associated features are related to an interaction of the inherited mutation with exposure to maternal diabetes.

Acknowledgments

We would like to acknowledge the parents for allowing us to submit this case report. We are also grateful to the molecular genetics and cytogenetics laboratories at PathWest for performing the genetic analyses.

References

Aylsworth, A. S. (2001). Clinical aspects of defects in the determination of laterality. *American Journal of Medical Genetics, 101*, 345–355.

Cappellen, D., De Oliveira, C., Ricol, D., de Medina, S., Bourdin, J., Sastre-Garau, X., Chopin, D., Thiery, J. P., & Radvanyi, F. (1999). Frequent activating mutations of FGFR3 in human bladder and cervix carcinomas. *Nature Genetics, 23*, 18–20.

Chesi, M., Nardini, E., Brents, L. A., Schrock, E., Ried, T., Kuehl, W. M., & Bergsagel, P. L. (1997). Frequent translocation t(4;14)(p16.3;q32.3) in multiple myeloma is associated with increased expression and activating mutations of fibroblast growth factor receptor 3. *Nature Genetics, 16*, 260–264.

Cohen, M. M., Jr. (2001). Asymmetry: Molecular, biologic, embryopathic, and clinical perspectives. *American Journal of Medical Genetics, 101*, 292–314.

Doherty, E., & Muenke, M. (2009). Muenke Syndrome. Available at www.genetests.org

Friesel, R. E., & Maciag, T. (1995). Molecular mechanisms of angiogenesis: Fibroblast growth factor signal transduction. *FASEB Journal, 9*, 919–925.

Goriely, A., Hansen, R. M., Taylor, I. B., Olesen, I. A., Jacobsen, G. K., McGowan, S. J., Pfeifer, S. P., McVean, G. A., Meyts, E. R., & Wilkie, A. O. (2009). Activating mutations in FGFR3 and HRAS reveal a shared genetic origin for congenital disorders and testicular tumors. *Nature Genetics, 41*, 1247–1252.

Gripp, K. W., Lin, A. E., Stabley, D. L., Nicholson, L., Scott, C. I., Jr., Doyle, D., Aoki, Y., Matsubara, Y., Zackai, E. H., Lapunzina, P., Gonzalez-Meneses, A., Holbrook, J., Agresta, C. A., Gonzalez, I. L., & Sol-Church, K. (2006). HRAS mutation analysis in Costello syndrome: Genotype and phenotype correlation. *American Journal of Medical Genetics A, 140*, 1–7.

Hong, S. K., & Dawid, I. B. (2009). FGF-dependent left-right asymmetry patterning in zebrafish is mediated by Ier2 and Fibp1. *Proceedings of the National Academy of Sciences USA, 106*, 2230–2235.

Johnson, D. E., & Williams, L. T. (1993). Structural and functional diversity in the FGF receptor multigene family. *Advances in Cancer Research, 60*, 1–41.

Muenke, M., Gripp, K. W., McDonald-McGinn, D. M., Gaudenz, K., Whitaker, L. A., Bartlett, S. P., Markowitz, R. I., Robin, N. H., Nwokoro, N., Mulvihill, J. J., Losken, H. W., Mulliken, J. B., Guttmacher, A. E., Wilroy, R. S., Clarke, L. A., Hollway, G., Ades, L. C., Haan, E. A., Mulley, J. C., Cohen, M. M., Jr., Bellus, G. A., Francomano, C. A., Moloney, D. M., Wall, S. A., Wilkie, A. O., & et al. (1997). A unique point mutation in the fibroblast growth factor receptor 3 gene (FGFR3) defines a new craniosynostosis syndrome. *American Journal of Human Genetics, 60*, 555–564.

Neugebauer, J. M., Amack, J. D., Peterson, A. G., Bisgrove, B. W., & Yost, H. J. (2009). FGF signalling

https://doi.org/10.1375/twin.13.4.297 Published online by Cambridge University Press

during embryo development regulates cilia length in diverse epithelia. *Nature, 458,* 651–654.

Ornitz, D. M., & Marie, P. J. (2002). FGF signaling pathways in endochondral and intramembranous bone development and human genetic disease. *Genes and Development, 16*, 1446–1465.

Passos-Bueno, M. R., Wilcox, W. R., Jabs, E. W., Sertie, A. L., Alonso, L. G., & Kitoh, H. (1999). Clinical spectrum of fibroblast growth factor receptor mutations. *Human Mutation, 14*, 115–125.

Paznekas, W. A., Cunningham, M. L., Howard, T. D., Korf, B. R., Lipson, M. H., Grix, A. W., Feingold, M., Goldberg, R., Borochowitz, Z., Aleck, K., Mulliken, J., Yin, M., & Jabs, E. W. (1998). Genetic heterogeneity of Saethre-Chotzen syndrome, due to TWIST and FGFR mutations. *American Journal of Human Genetics, 62*, 1370–1380.

Peeters, H., & Devriendt, K. (2006). Human laterality disorders. *European Journal of Medical Genetics, 49*, 349–362.

Prattichizzo, C., Macca, M., Novelli, V., Giorgio, G., Barra, A., & Franco, B. (2008). Mutational spectrum of the oral-facial-digital type I syndrome: A study on a large collection of patients. *Human Mutation, 29*, 1237–1246.

Qiu, W. H., Zhou, B. S., Chu, P. G., Chen, W. G., Chung, C., Shih, J., Hwu, P., Yeh, C., Lopez, R., & Yen, Y. (2005). Over-expression of fibroblast growth factor receptor 3 in human hepatocellular carcinoma. *World Journal of Gastroenterology, 11*, 5266–5272.

Richelda, R., Ronchetti, D., Baldini, L., Cro, L., Viggiano, L., Marzella, R., Rocchi, M., Otsuki, T., Lombardi, L., Maiolo, A. T., & Neri, A. (1997). A novel chromosomal translocation t(4; 14)(p16.3; q32) in multiple myeloma involves the fibroblast growth-factor receptor 3 gene. *Blood, 90*, 4062–4070.

Rousseau, F., Bonaventure, J., Legeai-Mallet, L., Pelet, A., Rozet, J. M., Maroteaux, P., Le Merrer, M., & Munnich, A. (1994). Mutations in the gene encoding fibroblast growth factor receptor-3 in achondroplasia. *Nature, 371*, 252–254.

Ryan, A. K., Blumberg, B., Rodriguez-Esteban, C., Yonei-Tamura, S., Tamura, K., Tsukui, T., de la Pena, J., Sabbagh, W., Greenwald, J., Choe, S., Norris, D. P., Robertson, E. J., Evans, R. M., Rosenfeld, M. G., & Izpisua Belmonte, J. C. (1998). Pitx2 determines left-right asymmetry of internal organs in vertebrates. *Nature, 394*, 545–551.

Schutte, K., Bornschein, J., & Malfertheiner, P. (2009). Hepatocellular carcinoma: Epidemiological trends and risk factors. *Digestive Diseases, 27*, 80–92.

Sutherland, M. J., & Ware, S. M. (2009). Disorders of left-right asymmetry: Heterotaxy and situs inversus. *American Journal of Medical Genetics, 151C*, 307–317.

Webster, M. K., & Donoghue, D. J. (1997). FGFR activation in skeletal disorders: Too much of a good thing. *Trends in Genetics, 13*, 178–182.

https://doi.org/10.1375/twin.13.4.297 Published online by Cambridge University Press