

Myocarditis After Vaccination

Mustafa Emin Canakci;¹  Kadir Ugur Mert;² Nevin Aydin³

1. Emergency Department, Eskisehir Osmangazi University, Eskisehir, Turkey
2. Cardiology Department, Eskisehir Osmangazi University, Eskisehir, Turkey
3. Radiology Department, Eskisehir Osmangazi University, Eskisehir, Turkey

Correspondence:

Mustafa Emin Canakci, MD
Emergency Department
Eskisehir Osmangazi University
Eskisehir, Turkey
Prof. Dr. Nabi Avci Boulevard
No:4, Meselik, Odunpazari, 26040
E-mail: mustafaeminc@gmail.com

Conflicts of interest/funding: None

Keywords: COVID-19; mRNA; myocarditis; vaccine

Abbreviations:

COVID-19: coronavirus disease 2019
SARS-CoV-2: severe acute respiratory syndrome coronavirus 2

Received: August 10, 2022

Accepted: August 15, 2022

doi:[10.1017/S1049023X22001236](https://doi.org/10.1017/S1049023X22001236)

© The Author(s), 2022. Published by Cambridge University Press on behalf of the World Association for Disaster and Emergency Medicine.

Canakci ME, Mert KU, Aydin N. Myocarditis after vaccination. *Prehosp Disaster Med.* 2022;37(5):716–717.

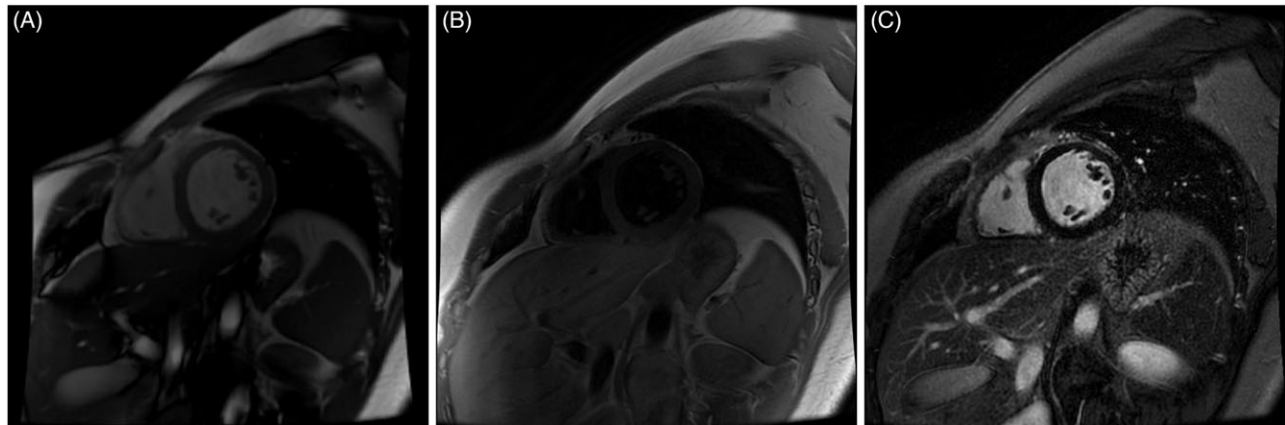
In the article “Vaccine-Induced Myocarditis in Two Intern Doctors in the Same Night Shift,” myocarditis cases that developed after the first dose of the BNT162b2 vaccine (Pfizer-BioNTech’s [New York USA] coronavirus disease 2019 [COVID-19] vaccine) were mentioned.¹ In this article, it was stated that myocarditis cases were mild. There is a need to provide information about myocarditis-related processes. Cardiac magnetic resonance imaging (MRI) was performed in both patients and Ejection Fraction ratios were found to be 68% and 62%. Left ventricular function was normal, and no increase in enhancement was detected in late contrast examinations. There was no sign which depicts scar tissue in the heart (Figure 1 and Figure 2). The echocardiography showed that left ventricular functions were normal and there was no diastolic dysfunction. Also, no valve pathology was found.

We think that some scientific data should be included in addition to the general condition of the cases. According to a study conducted in 40 centers, myocarditis cases developing on the seventh day after severe acute respiratory syndrome coronavirus 2 (SARS-CoV-2) infection in men aged 18–29 were seen at much higher rates than both the first dose and the second dose of vaccine (RR: 61.8 [95% CI, 8.5–451.8] and RR: 7.0 [95% CI, 3.7–19.1], respectively). In addition, the risk of myocarditis after SARS-CoV-2 was statistically higher than in the post-vaccination period, similarly in other age groups and female gender.²

Myocarditis linked to the COVID-19 mRNA vaccine typically affects young persons and is usually mild. Also, COVID-19 vaccination lowers the relative risk of myocarditis and arrhythmia.³

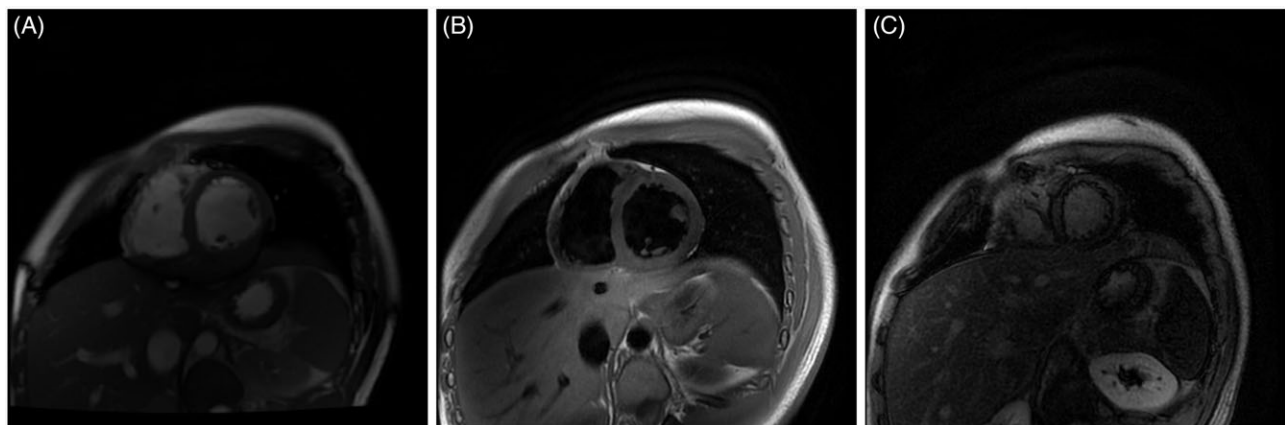
A study showed intubation or mechanical ventilation was only used in two patients, and 12 cases were treated with vasoactive drugs in patients younger than 30 years. There were no confirmed cases of myocarditis needing extracorporeal membrane oxygenation, a ventricular assist device, or a heart transplant.⁴

In the light of these information, it should not be forgotten that vaccination is still very valuable and booster vaccination should be made to prevent new pandemic waves in the ongoing process.



Canakci © 2022 Prehospital and Disaster Medicine

Figure 1. 3T Cardiac MRI of Patient One: (A) Short Axis CINE Images Taken in the Enddiastolic Phase; (B) Short Axis T1-Weighted Black Blood Fast Spin Echo Image; and (C) Short Axis Late Gadolinium Enhancement (10th minute). Abbreviation: MRI, magnetic resonance imaging.



Canakci © 2022 Prehospital and Disaster Medicine

Figure 2. 3T Cardiac MRI of Patient Two: (A) Short Axis CINE Images Taken in the Enddiastolic Phase; (B) Short Axis T1-Weighted Black Blood Fast Spin Echo Image; and (C) Short Axis Late Gadolinium Enhancement (10th minute). Abbreviation: MRI, magnetic resonance imaging.

References

1. Canakci ME, Sevik OE, Dereli G, Mert KU, Acar N. Vaccine-induced myocarditis in two intern doctors in the same night shift. *Prehosp Disaster Med.* 2022. Online ahead of print.
2. Block JP. Cardiac complications after SARS-CoV-2 infection and mRNA COVID-19 vaccination — PCORnet, United States, January 2021–January 2022. *MMWR Morb Mortal Wkly Rep.* 2022. Online ahead of print.
3. Heymans S, Cooper LT. Myocarditis after COVID-19 mRNA vaccination: clinical observations and potential mechanisms. *Nat Rev Cardiol.* 2022;19(2):75–77.
4. Oster ME, Shay DK, Su JR, et al. Myocarditis cases reported after mRNA-based COVID-19 vaccination in the US from December 2020 to August 2021. *JAMA.* 2022;327(4):331–340.