

Something's not right

Andrew Healey, MD;* Tia Renouf, MD†

Case history

A 59-year-old gentleman awoke from sleep in the morning and attempted to get out of bed. He immediately began to experience chest pain and took some of his wife's nitroglycerine with minimal relief. At this point, his wife called an ambulance.

On arrival to the emergency department, his vital signs were as follows: pulse 80 beats/min; respiratory rate 20 breaths/min; blood pressure 180/100 mm Hg and 160/100 mm Hg in the right and left arms, respectively; temperature 35.6°C, oxygen saturation, 100% on room air. He complained of chest pressure radiating to the back, ab-

domen and flanks. He also described weakness, shortness of breath and diaphoresis. His past medical history included a remote cholecystectomy, previous non-bleeding peptic ulcer disease and sleep apnea. He was recently diagnosed with hypertension and started on an angiotensin converting enzyme inhibitor. He had a heavy smoking history and considered himself a social drinker.

On examination, this obese gentleman was pale, diaphoretic and in obvious discomfort. There were no focal neurological findings, and physical examination of the heart, lungs and abdomen was unremarkable. The jugular venous pulsation was within normal limits and radial, femoral and pedal pulses were symmetric. Results of his chest x-ray (Fig. 1) and ECG (Fig. 2) are shown below. The next steps in management would include:

- A. Administer a thrombolytic regimen
- B. Start intravenous nitrates and give ASA
- C. Start a labetalol drip
- D. Give heparin
- E. Order a CT of the chest

For the Answer to this Challenge, see page 286.

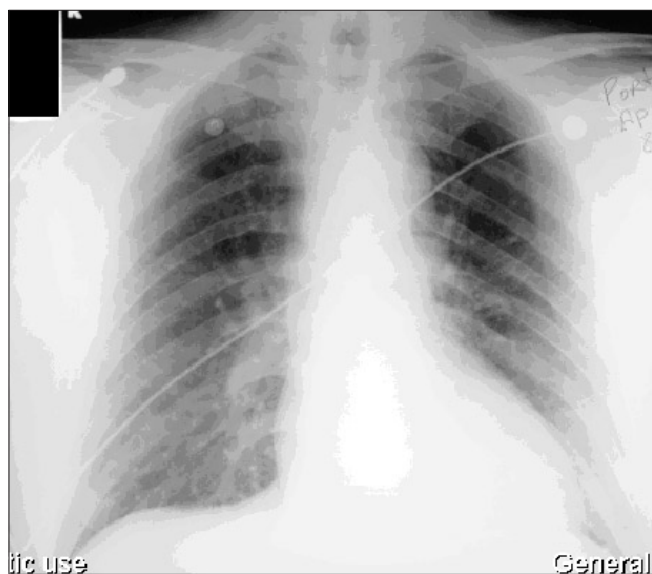


Fig. 1. Results of chest x-ray of 59-year-old man with chest pain.

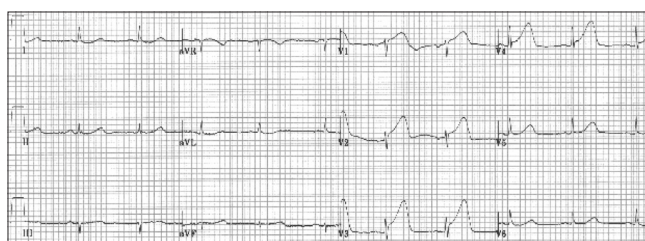

Fig. 2. Results of ECG of 59-year-old man with chest pain.

*Assistant Professor, Faculty of Medicine, Memorial University of Newfoundland, St. John's, Nfld.

†Emergency Medicine Resident, McMaster University, Hamilton, Ont.

Received: Jan. 20, 2005; final submission: Feb. 16, 2005; accepted: Apr. 23, 2005

Can J Emerg Med 2005;7(4):286