


Clinical efficacy of tobramycin dexamethasone eye ointment combined with a catheter in endoscopic dacryocystorhinostomy

Hailin Hu, Xiaoping Bi, Yimin Li, Junfang Wang and Wodong Shi 

Department of Ophthalmology, Ninth People's Hospital, Shanghai Jiao Tong University School of Medicine, Shanghai, 200011, China

Main Article

Wodong Shi takes responsibility for the integrity of the content of the paper

Cite this article: Hu H, Bi X, Li Y, Wang J, Shi W. Clinical efficacy of tobramycin dexamethasone eye ointment combined with a catheter in endoscopic dacryocystorhinostomy. *J Laryngol Otol* 2024;1–6. <https://doi.org/10.1017/S0022215124001622>

Received: 29 December 2023

Revised: 18 June 2024

Accepted: 5 July 2024

Keywords:

catheters;
tobramycin dexamethasone eye ointment;
endoscopic dacryocystorhinostomy

Corresponding authors:

Junfang Wang;
Email: wangjunfang314@163.com;
Wodong Shi;
Email: 13651800136@163.com

Abstract

Objective. To evaluate the clinical efficacy of tobramycin dexamethasone eye ointment combined with a catheter in endoscopic dacryocystorhinostomy.

Methods. Eighty chronic dacryocystitis patients were randomly divided into two groups: observation ($n = 39$) and control ($n = 41$). Both groups underwent endoscopic dacryocystorhinostomy. The observation group used tobramycin dexamethasone eye ointment and catheter support, while the control group used only the eye ointment.

Results. No statistical differences were found in gender, age, disease course or eye type. However, the anastomotic formation time and bleeding amount were significantly different between the two groups ($p < 0.001$). After six months of follow up, there were no significant complications differences ($p > 0.05$). The fluorescein disappearance test time in the observation group was significantly shorter ($p < 0.001$), and the clinical effective rate was significantly higher (97.4 per cent vs 78 per cent, $p < 0.05$) in the observation group.

Conclusion. Using tobramycin dexamethasone eye ointment combined with a catheter slightly prolongs the operation time and increases bleeding, but promotes anastomotic healing, accelerates tear drainage, improves the operation success rate and is economically efficient.

Introduction

Chronic dacryocystitis is the most common lacrimal sac disease and is common in middle-aged and older women.¹ Most chronic dacryocystitis cases are caused by the continuous retention of secretions in the lacrimal sac due to the stenosis or obstruction of the nasolacrimal duct.^{2–4} Nasolacrimal duct obstruction ultimately leads to stagnation of tears, accumulation of mucous secretions and shedding of cells, providing a suitable environment for bacterial infection and dacryocystitis.⁵ It often presents as epiphora, overflow of purulent discharge and significant conjunctival congestion at the inner canthus,⁵ which severely affects patients' health and quality of life.

Surgery is the only effective method for treating chronic dacryocystitis, with dacryocystorhinostomy being a common surgical procedure.^{6,7} Although traditional external dacryocystorhinostomy is the 'gold standard' for the treatment of dacryocystitis, it has gradually been replaced by transnasal endoscopic dacryocystorhinostomy because of the large incision and the problem of facial scarring.^{8,9} Endoscopic dacryocystorhinostomy offers advantages such as being minimally invasive, with no facial scarring and able to be corrected surgically.^{10,11} A patent pathway is formed by opening the blocked portion of the lacrimal sac mucosa and anastomosing the nasal mucosa with the lacrimal sac mucosa. However, granulation tissue proliferation and scar contraction at the nasolacrimal duct anastomosis site may lead to stoma stenosis or adhesion, which is the main cause of recurrence.^{12,13}

The success of transnasal endoscopic dacryocystorhinostomy depends largely on anastomosis formation between the lacrimal sac mucosa and the nasal mucosa, therefore finding a simple, convenient and reliable method to achieve mucosal anastomosis between the lacrimal sac and nasal mucosa, promoting epithelialisation of the anastomotic site as much as possible, and reducing adhesions and granulation tissue formation, has become a key issue in endoscopic dacryocystorhinostomy. Currently, stent placement is the preferred method to prevent nasal ostium closure.¹⁴ It has been reported that in patients undergoing dacryocystorhinostomy with adjunctive silicone tube intubation, a 1.5-mm silicone tube significantly reduces recurrence rates compared with a 1.0-mm tube.¹⁵ However, silicone stents are expensive (approximately \$230).

To alleviate the financial burden on patients, we used an No. 8 urinary catheter (\$3) as an alternative to silicone stents, which is an innovative approach. Additionally, tobramycin dexamethasone eye ointment can promote healing of the anastomotic site. Based on this, the aim of this study was to investigate the clinical efficacy of using a catheter combined with tobramycin dexamethasone eye ointment in endoscopic dacryocystorhinostomy.

Materials and methods

Patients

From January 2019 to December 2019, 80 patients with chronic dacryocystitis were selected, including 24 males and 56 females. The disease occurred in one eye and the patients' average age was 49.60 ± 18.17 years. The course of disease ranged from 4 months to 30 years. The participants were randomly divided into a control group and an observation group.

Inclusion criteria: (1) the diagnostic basis of chronic dacryocystitis refers to clinical diagnosis and treatment guidelines in ophthalmology volume,¹⁶ lacrimal overflow is one of the symptoms, mucous or purulent secretion overflow can be seen when pressing the lacrimal sac area, lacrimal passage flushing is blocked and there is mucous or purulent secretion; (2) a computed tomography scan of the lacrimal duct showed obstruction of the nasolacrimal duct; and (3) the disease of all patients occurred in one eye.

Exclusion criteria: (1) patients with traumatic dacryocystitis, recurrent dacryocystitis or small lacrimal sac; (2) patients who had previously received lacrimal duct laser, catheterisation or unsuccessful surgery; (3) patients with lower lacrimal canaliculus stenosis or obstruction; and (4) nasal septum deviation, nasal polyps, allergic rhinitis, chronic sinusitis and other nasal abnormalities.

All patients volunteered for surgery and signed informed consent. This study meets the standards of the ethics committee of the Ninth People's Hospital Affiliated to the Medical College of Shanghai Jiao tong University.

Treatment methods

All patients were treated with antibiotic eye drops 3 days in advance. Their nasal hair was cut and the nasal cavity was cleaned before the operation. The operation was performed using local anaesthesia, with general anaesthesia used for patients who could not tolerate the operation.

Following successful disinfection and draping, a proper amount of neurosurgical cottonoids were filled in the middle nasal tract. After mucosal contraction, under 0° wide-angle nasal endoscopy, an ophthalmic tunnel knife was used to make a nasal mucosal incision of about 10–12 mm in the parallel groove process at the front edge of the middle turbinate. The upper boundary was 0.7 cm above the anterior axillary of the middle turbinate and the lower boundary was 0.3 cm below the anterior axillary.

A second incision parallel to the front incision, with a length of about 10 mm, was made using a tunnel knife. The nasal mucosa was separated passively by stripping ions from the front edge of the incision and the lower mucosa was cut with scissors to form the nasal mucosal flap with the base above. After inverting and exposing the bone surface, the bone was bitten off from the lacrimal jaw seam with bone-biting forceps and the edge of the bone window was polished with a cutting bit and a polishing bit to form about a 10 × 12-mm bone window, exposing the inner side of lacrimal sac wall. Using a lacrimal probe, the boundary of the lacrimal sac cavity was explored, lifting the lacrimal sac from bottom to top with a tunnel knife, continuing to cut the lacrimal sac along the sac cavity and flattening the lacrimal sac wall below the incision to form a posterior valve. After the nasal mucosa had been reversed, it was trimmed to the appropriate size and opposite to the lacrimal sac mucosa.

For the observation group, the lacrimal passage probe with a guide wire was inserted from the upper lacrimal dot. It

entered the open dacryocyst nasal anastomosis, with the middle guide wire threaded out to the nasal orifice. One end of a No. 8 urinary catheter (diameter 2.6 mm) was threaded with 4-0 silk thread cut to a length of 2.5–3 cm (Figure 1). Using guide wire, the thread was passed through the upper lacrimal dot. Retrograde entry into the anastomosis, with exit through the lacrimal punctum under the guidance of a guide wire. The body of the catheter was then pressed against the contraposition anastomosis formed by the lacrimal sac mucosa and nasal mucosa (Figure 2).

The pre-prepared TobraDex (15 mg) and dexamethasone (5 mg/5 ml) eye ointments were applied to cover the anastomotic stoma, the contraposition mucosa and around the urinary catheter under the direct vision of nasal endoscopy. The length of the silk thread was adjusted to 5 cm and stuck onto the patient's forehead with adhesive tape (Figure 3). The patient was advised to apply eye ointment locally after surgery to the contact area between the suture and the skin to reduce discomfort caused by the suture.

For the control group, after incision of the lacrimal sac mucosa and the nasal mucosa in the opposite position, the pre-prepared TobraDex and dexamethasone eye ointments were applied under the direct vision of the nasal endoscope to cover the anastomotic stoma, and the operation was finished when there was no obvious bleeding.

Post-operative treatment

Systemic antibiotics were administered for 3 days after the operation. Topical ofloxacin eye drops were used three times a day. Furacilin nasal drops were dropped into the ipsilateral nasal cavity three times a day and budesonide nasal spray was used twice a day for one month. One week after surgery, a nasal endoscope was used to clean nasal secretions. The catheter was removed using a nasal endoscope at five weeks post-operatively. The patients were followed up for six months, with the final observation result being at six months.

Evaluation index

The time of anastomotic stoma formation and intra-operative blood loss in the two groups was observed. Six months after surgery, the times of the fluorescein disappearance test, post-operative complications (mucosal adhesion and granulation formation), post-operative effect, and post-operative total response rate were compared between the two groups.

The time for anastomosis formation during the operation refers to the time when the lacrimal mucosa was cut by a tunnel knife, anastomosed with the trimmed nasal mucosa, and the anastomosis was covered by catheter and tobramycin dexamethasone eye ointment.

A uniform specification of neurosurgical cottonoids and a negative pressure suction device was used to calculate the

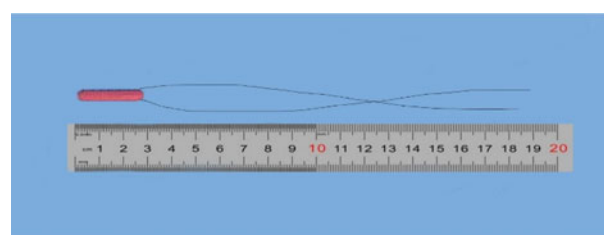


Figure 1. No. 8 catheter.

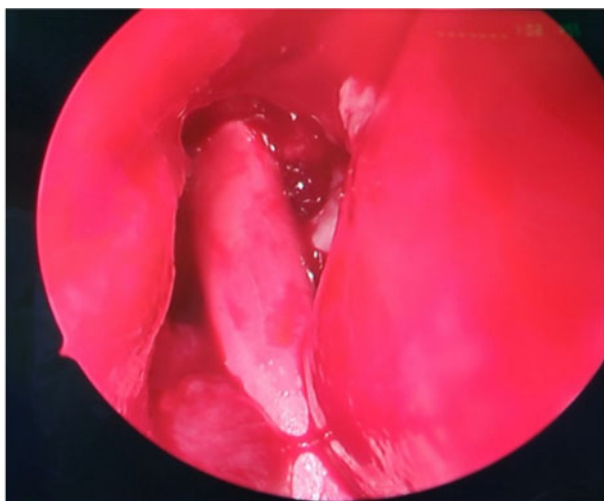


Figure 2. Catheters were placed above the anastomotic stoma formed by nasal mucosa and lacrimal mucosa.

amount of blood loss during surgery. The conversion relationship between the amount of blood loss and neurosurgical cottonoids is about 1 ml per tablet. The amount of blood loss was calculated from the number of brain pads used and the amount of blood in the suction vessel. The data were calculated and recorded by doctors and nurses post-operatively in the operation nursing record sheet.

Time of fluorescein disappearance test

The fluorescein disappearance test was performed six months after the operation. One drop of 2 per cent fluorescein was dropped into the lower conjunctival vault and the patient was asked to blink several times to observe the time of fluorescein disappearance in the conjunctival sac after the outflow of fluorescein from the anastomosis of the lacrimal sac and nasal cavity (Figure 4).

Surgical efficacy criteria

The therapeutic efficacy was evaluated by referring to the relevant standards in *Nasal Endoscopy Surgery*¹⁷ and observation of various post-operative indicators. For the cured indicator, anastomosis was formed in the patient by nasal endoscopy (Figure 5). The symptom of lacrimal overflow disappeared and the lacrimal passage was unobstructed by irrigation. For

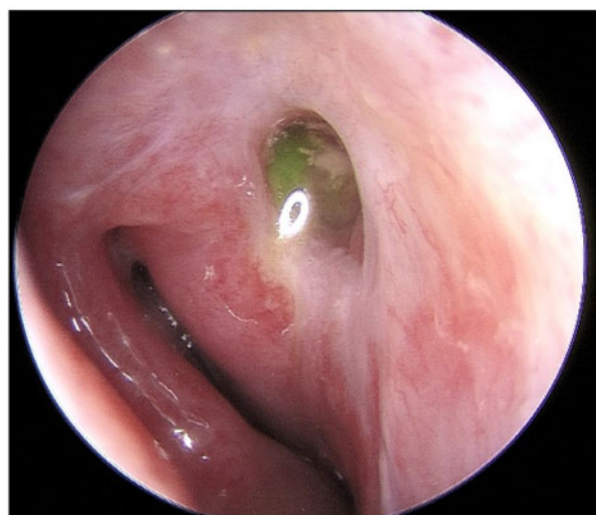


Figure 4. The fluorescein disappearance test shows that fluorescein is discharged from the anastomosis.

the valid indicator, the formation of anastomotic stoma was observed through nasal endoscopy and all clinical symptoms were significantly relieved. Although the inlet or nasal cavity was rinsed, a small amount of reflux was observed. After pressure treatment patency, overflow tears still existed, but the flushing patency resistance was high. For the invalid indicator, the patient's symptoms were not alleviated, the lacrimal duct remained blocked despite flushing or compression treatment, and the perforation was blocked. The total clinical response rate was calculated as (cured cases + valid cases)/total cases \times 100 per cent.

Statistical method

Statistical analysis was carried out using SPSS 26.0 software. Continuous variables were described by the mean \pm standard deviation ($\bar{x} \pm s$) according to data distribution, and the median (interquartile spacing) was used if they did not conform to normal distribution. A *t*-test or non-parametric rank-sum test was used to compare the data of the two groups. The categorical variables were described using frequency (per cent) and the rates were compared between groups using the chi-

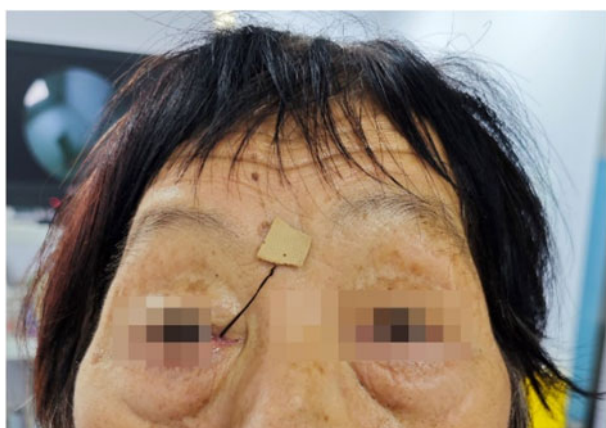

Figure 3. Catheter fixed on forehead with silk tape.

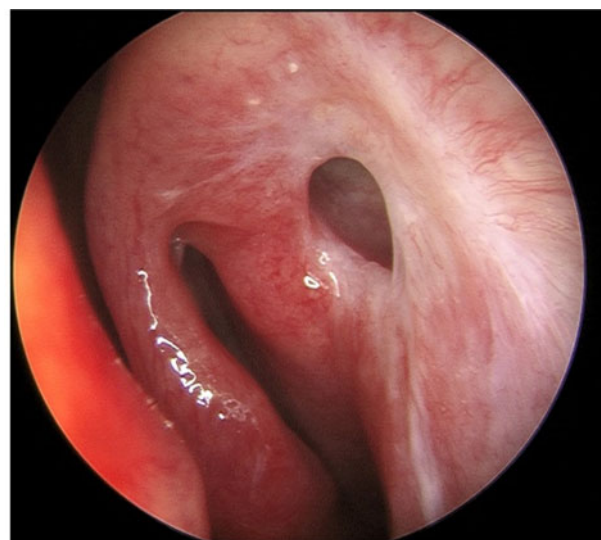


Figure 5. Anastomotic stoma formed in six months.

square test or Fisher's exact probability method. Statistically significant differences were indicated by p less than 0.05.

Results

Clinical characteristics of subjects in both groups

All 80 patients were followed up and there were no statistically significant differences in gender ratio, age, course of disease or eye type ($p > 0.05$), as shown in Table 1. There were 13 males and 26 females in the observation group, with an average age of 50.64 ± 17.95 years. The disease occurred in 18 right eyes, accounting for 46.2 per cent of patients (18 of 39), and 21 left eyes, accounting for 53.8 per cent of patients (21 of 39). There were 11 males and 30 females in the control group. The average age was 48.61 ± 18.56 years. The disease occurred in 22 right eyes (53.7 per cent) and 19 left eyes (46.3 per cent).

Surgical results for both groups of subjects

As shown in Table 2, the time of anastomotic stoma formation in the observation group [30.00 minutes (29.00, 32.50)] was longer than that in the control group [13.00 minutes (12.00, 14.00)], and the volume of blood loss [16.00 ml (15.00, 18.00)] was higher than in the control group [9.00 ml (8.00, 10.00)]. There was a statistical difference between the two groups ($p < 0.001$).

There was no statistical difference in complications (mucosal adhesion and granulation) between the two groups 6 months after the operation ($p > 0.05$). The time for fluorescein disappearance test in the observation group [12.00 minutes (10.00, 18.50)] was significantly shorter than in the control group [39.00 minutes (30.00, 45.00), $p < 0.001$]. The total clinical effective rate of the observation group (97.4 per cent, 38 of 39 patients) was significantly higher than that of the control group (78 per cent, 32 of 41 patients), with a statistical difference between the two groups ($p < 0.05$), as shown in Table 2.

Discussion

Endoscopic dacryocystorhinostomy aims to create an anastomosis between the lacrimal sac flap and the nasal mucosal flap, thereby establishing a new drainage pathway for tears.¹⁸ Since the end of the last century, anastomosis has been considered the core technical point of dacryocystorhinostomy. Wu *et al.*¹⁹ found that Merlot glue could fix mucosal flap and promote mucosal epithelisation, thereby improving the success rate of the operation. Caglar *et al.*²⁰ tried to use the direct application of a U-shaped nasal mucosal flap to improve the effective rate.

Research has shown that lacrimal punctal dilation and bilateral nasal silicone tube insertion can effectively treat acquired epiphora caused by allergic conjunctivitis-induced lacrimal punctal stenosis or obstruction. A study found that bilateral silicone tube insertion is a well-tolerated and effective tool for treating this type of acquired lacrimal punctal stenosis or obstruction caused by allergic conjunctivitis.²¹ Researchers have been continuously exploring various methods to improve the process of anastomosis formation to enhance the success rate of surgery.

This study employed tobramycin dexamethasone eye ointment to cover the anastomosis and combined it with a urinary catheter to support the union of lacrimal sac mucosa and nasal mucosa in the observation group. The results revealed that the observation group had a longer anastomosis formation time compared with the control group (using only tobramycin dexamethasone eye ointment), with a higher intra-operative blood loss. However, there was no significant difference in the incidence of complications at six months post-operatively between the two groups.

The fluorescein disappearance test time in the observation group was significantly shorter than that in the control group, and the overall clinical efficacy rate (97.4 per cent) was significantly higher in the observation group than in the control group. This indicates that the combination of ureteral catheterisation and tobramycin dexamethasone eye ointment in endoscopic dacryocystorhinostomy surgery can significantly improve surgical outcome and efficacy.

Nitin *et al.*²² found in a prospective randomised comparison that the success rate of endoscopic dacryocystorhinostomy after stent placement was 96 per cent, which is consistent with the results of our study. Compared with the control group, the observation group had a greater amount of bleeding. We speculate the reasons for this might be the lack of application of tobramycin dexamethasone ointment on the surface of the incised lacrimal sac mucosa and the nasal mucosa. The mucosa, under prolonged inflammation, is unhealthy. Even slight friction from a foreign object on the surface can easily cause bleeding.

During the six-month follow-up period, adhesion and granulation occurred in both the control group and the observation group, but there was no significant difference between the two groups. Kang *et al.*¹⁴ recently conducted a meta-analysis that found no significant difference in the incidence of complications between endoscopic dacryocystorhinostomy with or without silicone stent insertion. This suggests that the use of silicone stents does not increase the risk of adhesions, granulation tissue formation or post-operative bleeding, which is consistent with our findings. The proportion of post-

Table 1 Comparison of general data between the two groups

Characteristic	Total	Control group ($n = 41$)	Observation group ($n = 39$)	p
Gender (n (%))				0.526
– Male	24 (30.0)	11 (26.8)	13 (33.3)	
– Female	56 (70.0)	30 (73.2)	26 (66.7)	
Age (years \pm standard deviation)	49.60 ± 18.17	48.61 ± 18.56	50.64 ± 17.95	0.620
Course of disease (median (interquartile range))	3.00 (0.96, 8.50)	2.00 (1.00, 6.00)	3.00 (0.83, 10.00)	0.682
Eye (n (%))				0.502
– Right	40 (50.0)	22 (53.7)	18 (46.2)	
– Left	40 (50.0)	19 (46.3)	21 (53.8)	

Table 2 Comparison of intra-operative data and data six months after the operation for the two groups

Variable	Total (n = 80)	Control group (n = 41)	Observation group (n = 39)	p
Time for anastomotic formation (minutes)	20.50 (13.00, 30.00)	13.00 (12.00, 14.00)	30.00 (29.00, 32.50)	<0.001**
Intra-operative bleeding volume (ml)	11.50 (9.00, 16.00)	9.00 (8.00, 10.00)	16.00 (15.00, 18.00)	<0.001**
Six months after operation				
– Fluorescein dye disappearance test time (seconds)	28.00 (13.50, 39.00)	39.00 (30.00, 45.00)	12.00 (10.00, 18.50)	<0.001**
– Adhesion (n (%))	7 (8.8)	5 (12.2)	2 (5.1)	0.433
– Granulation (n (%))	7 (8.8)	6 (14.6)	1 (2.6)	0.109
– Effect (n (%))				<0.001**
– Invalid	10 (12.5)	9 (22.0)	1 (2.6)	
– Valid	43 (53.7)	31 (75.6)	11 (28.2)	
– Cured	27 (33.8)	1 (2.4)	27 (69.2)	
– Total effective rate (n (%))	70 (87.5)	32 (78.0)	38 (97.4)	0.015*

*p < 0.05, **p < 0.001

operative adhesion and granulation in the observation group is lower than that in the control group. The reason for this may be that the observation group had a urinary catheter supporting the anastomotic stoma to prevent the collapse of the anterior valve and acting as a physical partition to prevent the occurrence of adhesion.

It has been reported that²³ after dacryocystorhinostomy under a nasal endoscope, the average incidence of adhesion and granulation tissue hyperplasia was about 15 per cent. Our research average is about 8.8 per cent, which is lower than relevant reports. There are several possible reasons for this. During the operation, tobramycin dexamethasone eye ointment was applied to the anastomotic stoma under the direct vision of the nasal endoscope, avoiding blind operation and allowing the entire anastomotic stoma to be effective. An endoscopic dressing change was performed one week after the operation to clean nasal secretions.

Tobramycin dexamethasone eye ointment is mainly composed of tobramycin and dexamethasone, and contains Vaseline and other substances. Tobramycin is an aminoglycoside antibiotic and has a broad-spectrum antibacterial effect. Dexamethasone has a strong anti-inflammatory effect, which can effectively inhibit the formation of granulation tissue and prevent mucosal adhesion. Some researchers have pointed out that after lacrimal passage probing, tobramycin and dexamethasone eye ointment were injected when the needle was pulled out, which was beneficial to inhibiting tissue adhesion and improving the curative effect.²³

In addition, the fluorescein disappearance test can be used to assess the condition of the surgical incision or anastomosis. If the corneal epithelium is normal at the anastomosis site, the fluorescein dye solution will be rapidly cleared by the tears on the corneal surface, resulting in the disappearance of fluorescein. A shorter fluorescein disappearance time is therefore usually considered as an indicator of good healing of the anastomosis site.²⁴ In this study, the disappearance time of fluorescein in the observation group was significantly faster than in the control group, and the total effective rate was 97.4 per cent. This is closely related to the good alignment of the mucosa during the operation and the support of the urinary catheter after the operation.

Deka²⁵ and others also believed that good alignment was required when anastomosing the anterior and posterior valves of the lacrimal sac and nasal mucosa to ensure a large enough

open channel and avoid operation failure caused by re-obstruction. Hossain *et al.* also found that indwelling Vaseline gauze or a support tube at the anastomotic window of the surgical cavity helped to improve the long-term curative effect and led the fluid in the lacrimal sac to the nasal cavity.²⁶

- The combined use of tobramycin dexamethasone eye ointment and catheter support in endoscopic dacryocystorhinostomy may slightly prolong operation time and increase bleeding
- This treatment significantly promotes anastomotic healing, accelerates tear drainage, improves operation success rate and is economically efficient

This study has some limitations, including being a single-centre study with a short follow-up period, which may reduce the reliability of the results. In the future, efforts will be made to conduct multicentre studies across different regions, increase the sample size and extend the follow-up period. In summary, the application of a catheter combined with tobramycin dexamethasone eye ointment in endoscopic dacryocystorhinostomy surgery for the treatment of chronic dacryocystitis is effective. It promotes faster tear drainage, improves surgical success rates and utilises simple materials, thereby reducing the economic burden on patients. This finding provides a new therapeutic option for chronic dacryocystitis.

Acknowledgements. This study was supported by funds from National Science Foundation of China (No. 82171098). The study was approved by the Medical Ethics Review Committee of Ninth People's Hospital, Shanghai Jiao Tong University School of Medicine (SH9H-2023-T459-2). The data used to support the findings of this study are available from the corresponding author on request.

Competing interests. None declared

References

- 1 Bharathi MJ, Ramakrishnan R, Maneksha V, Shivakumar C, Nithya V, Mittal S. Comparative bacteriology of acute and chronic dacryocystitis. *Eye (Lond)* 2008;**22**:953–60
- 2 Islam MR, Wadud SA, Akhanda AH, Rahman MS, Habibullah M, Kabir MS *et al.* Outcome of transcanalicular endolaser and external dacryocystorhinostomy in chronic dacryocystitis. *Mymensingh Med J* 2018;**27**:673–8
- 3 Meireles MN, Viveiros MM, Meneghin RL, Galindo-Ferreiro A, Marques ME, Schellini SA. Dacryocystectomy as a treatment of chronic dacryocystitis in the elderly. *Orbit* 2017;**36**:419–21

- 4 Tang LF, Qin G, Yang YC, Gan LR, Wang Y, Long Z. [Therapeutic effect of two kinds of surgical treatment for chronic dacryocystitis: external dacryocystorhinostomy and endoscopic dacryocystorhinostomy]. *Lin Chuang Er Bi Yan Hou Tou Jing Wai Ke Za Zhi* 2017;**31**:1029–31
- 5 Amin RM, Hussein FA, Idriss HF, Hanafy NF, Abdallah DM. Pathological, immunohistochemical and microbiological analysis of lacrimal sac biopsies in patients with chronic dacryocystitis. *Int J Ophthalmol* 2013;**6**:817–26
- 6 Warren JF, Seiff SR, Kavanagh MC. Long-term results of external dacryocystorhinostomy. *Ophthalmic Surg Lasers Imaging* 2005;**36**:446–50
- 7 McDonogh M, Meiring JH. Endoscopic transnasal dacryocystorhinostomy. *J Laryngol Otol* 1989;**103**:585–7
- 8 Rabina G, Golan S, Neudorfer M, Leibovitch I. External dacryocystorhinostomy: characteristics and surgical outcomes in patients with and without previous dacryocystitis. *J Ophthalmol* 2013;**2013**:287524
- 9 Chow VJ, Tsetsos N, Poutoglidis A, Georgalas C. Quality of life in sinonasal tumors: an up-to-date review. *Curr Opin Otolaryngol Head Neck Surg* 2022;**30**:46–57
- 10 Wu W, Cannon PS, Yan W, Tu Y, Selva D, Qu J. Effects of Merogel coverage on wound healing and ostial patency in endonasal endoscopic dacryocystorhinostomy for primary chronic dacryocystitis. *Eye (Lond)* 2011;**25**:746–53
- 11 Lie J, Ma W. Comparison of application value of self-crosslinked sodium hyaluronate gel and absorbent cotton filling in endoscopic dacryocystorhinostomy for chronic dacryocystitis. *Clin Res Pract* 2024;**9**:92–5+104
- 12 Zhou K, Liu Y, Zhou M. Clinical reasearch of re-operation for post-operative recurrence of chronic dacryocystitis. *Chin J Ocular Trauma Occup Eye Dis* 2016;**38**:534–7
- 13 Prakash MD, Viswanatha B, Rasika R. Powered endoscopic endonasal dacryocystorhinostomy with mucosal flaps and trimming of anterior end of middle turbinate. *Indian J Otolaryngol Head Neck Surg* 2015;**67**:333–7
- 14 Kang MG, Shim WS, Shin DK, Kim JY, Lee JE, Jung HJ. A systematic review of benefit of silicone intubation in endoscopic dacryocystorhinostomy. *Clin Exp Otorhinolaryngol* 2018;**11**:81–8
- 15 Nakamura J, Kamao T, Mitani A, Mizuki N, Shiraishi A. Comparison of the efficacies of 1.0 and 1.5 mm silicone tubes for the treatment of nasolacrimal duct obstruction. *Sci Rep* 2022;**12**:11785
- 16 Association CM. *Ophthalmology Division of Clinical Diagnosis and Treatment Guidelines*. Beijing: People's Health Publishing House, 2006
- 17 Han D. *Nasal Endoscopic Surgery*. Beijing: People's Health Publishing House, 2001
- 18 Li S, Zhang Y. Application of valve removal technique in improved endoscopic dacryocystorhinostomy. *Int Eye Science* 2024;**24**:149–52
- 19 Wu W, Li Y, Yan W, Wang Y, Ke Z, Wang Q *et al.* Application of endoscopic minimally invasive technique in the treatment of refractory nasolacrimal duct obstruction. *Ophthalmic Res* 2007;**25**:950–2
- 20 Caglar C, Yener HI, Gul A, Ozcimen M. The modified technique of external dacryocystorhinostomy in the management of complicated nasolacrimal duct obstruction. *J Craniofac Surg* 2016;**27**:416–19
- 21 Alsulaiman N, Alsuhaibani AH. Bicanalicular silicone intubation for the management of punctal stenosis and obstruction in patients with allergic conjunctivitis. *Ophthalmic Plast Reconstr Surg* 2019;**35**:451–5
- 22 Nitin T, Uddin S, Paul G. Endonasal endoscopic dacryocystorhinostomy with and without stents: a comparative study. *Indian J Otolaryngol Head Neck Surg* 2022;**74**:1433–41
- 23 Yang Z, Qin H, Ren S. Efficacy of two probing of lacrimal passage treatments of infant dacryocystitis in different age. *Chin J Strabismus Pediatr Ophthalmol* 2014:19–21
- 24 Hamed Azzam S, Hartstein M, Dolmetsch A, Mukari A. Assessment of Lacrijet monocanalicular intubation for congenital nasolacrimal duct obstruction. *Eur J Ophthalmol* 2022;**32**:3340–5
- 25 Deka A, Saikia SP, Bhuyan SK. Combined posterior flap and anterior suspended flap dacryocystorhinostomy: a modification of external dacryocystorhinostomy. *Oman J Ophthalmol* 2010;**3**:18–20
- 26 Hossain MI, Nahar L, Rashid MA. Re-DCR with silicone tube intubation: an effective method of management of failed DCR. *Mymensingh Med J* 2015;**24**:661–4