



Left aortic arch and aberrant right subclavian artery in children: spectrum of symptoms and response to surgical intervention

Original Article

Cite this article: Cole L, Brown J, Yasuda J, Ngo P, Staffa SJ, Crilley N, Chiu P, Zendejas B, and Baird C (2024). Left aortic arch and aberrant right subclavian artery in children: spectrum of symptoms and response to surgical intervention. *Cardiology in the Young*, page 1 of 7. doi: [10.1017/S1047951124026519](https://doi.org/10.1017/S1047951124026519)

Received: 23 January 2024

Revised: 17 May 2024

Accepted: 31 August 2024



Keywords:

Vascular ring; dysphagia; tracheobronchomalacia; aberrant right subclavian artery

Corresponding author:

L. Cole;

Email: lianne.cole@childrens.harvard.edu

Lianne Cole¹ , Jennifer Brown², Jessica Yasuda³, Peter Ngo³, Steven J. Staffa⁴, Naomi Crilley², Peter Chiu² , Benjamin Zendejas¹ and Christopher Baird²

¹Department of Surgery, Boston Children's Hospital, Boston, Massachusetts, USA; ²Department of Cardiac Surgery, Boston Children's Hospital, Boston, Massachusetts, USA; ³Department of Gastroenterology, Boston Children's Hospital, Boston, Massachusetts, USA and ⁴Department of Anesthesiology, Boston Children's Hospital, Boston, USA

Abstract

Background: Children with left aortic arch and aberrant right subclavian artery may present with either respiratory or swallowing symptoms beyond the classically described solid-food dysphagia. We describe the clinical features and outcomes of children undergoing surgical repair of an aberrant right subclavian artery. **Materials and methods:** This was a retrospective review of children undergoing repair of an aberrant right subclavian artery between 2017 and 2022. Primary outcome was symptom improvement. Pre- and post-operative questionnaires were used to assess dysphagia (PEDI-EAT-10) and respiratory symptoms (PEDI-TBM-7). Paired *t*-test and Fisher's exact test were used to analyse symptom resolution. Secondary outcomes included perioperative outcomes, complications, and length of stay. **Results:** Twenty children, median age 2 years (IQR 1–11), were included. All presented with swallowing symptoms, and 14 (70%) also experienced respiratory symptoms. Statistically significant improvements in symptoms were reported for both respiratory and swallowing symptoms. Paired (pre- and post-op) PEDI-EAT-10 and PEDI-TBM-7 scores were obtained for nine patients, resulting in mean (\pm SD) scores decreasing (improvement in symptoms) from 19.9 (\pm 9.3) to 2.4 (\pm 2.5) $p = 0.001$, and 8.7 (\pm 4.7) to 2.8 (\pm 4.0) $p = 0.006$, respectively. Reoperation was required in one patient due to persistent dysphagia from an oesophageal stricture. Other complications included lymphatic drainage ($n = 4$) and transient left vocal cord hypomobility ($n = 1$). **Conclusion:** Children with a left aortic arch with aberrant right subclavian artery can present with oesophageal and respiratory symptoms beyond solid food dysphagia. A thorough multidisciplinary evaluation is imperative to identify patients who can benefit from surgical repair, which appears to be safe and effective.

Introduction

Left aortic arch with an aberrant right subclavian artery originating from the proximal descending aorta is the most common aortic arch anomaly occurring in approximately 0.5–2% of the population.¹ The presence of associated symptoms varies in the literature with some reports suggesting a low incidence of symptoms, whereas others have suggested up to 40% of patients being symptomatic.² One of the challenges in eliciting symptomatic status relates to the myriad presentations, which is thought to mainly present with solid food dysphagia but may also include dyspnoea, cough, food aversion, restrictive eating, modifying mealtime behaviours, weight loss, retrosternal pain, stridor, wheezing, upper respiratory infections, and even dysphagia to liquids.³ Given that many are diagnosed incidentally and recognising associated symptoms can be challenging, the true incidence of symptomatic aberrant right subclavian artery is not well understood.

Diagnosis and management of aberrant right subclavian arteries in children can be challenging, particularly when the classically described solid-food dysphagia is not present, presenting symptoms are vague, the child's is too young to accurately describe what they feel, or a comorbid developmental delay or chromosomal abnormality exists. Additionally, symptoms may not be attributed to an aberrant right subclavian artery given that other potentially coexisting diseases, such as gastroesophageal reflux or aspiration, may produce similar symptoms.^{2,4} Among children, the accumulated literature is limited to case reports due to the belief that most patients are asymptomatic. In this regard, surgery is often seen as a last resort due to the lack of data showing a benefit in children.⁴ Others suggest that surgical intervention is low risk and can provide significant relief of symptoms.⁵ We undertook the current study to describe the clinical features and outcomes of symptomatic children undergoing surgical repair of an aberrant right subclavian artery. We hypothesised that surgical repair of an aberrant right subclavian artery would be beneficial, even in instances of atypical symptoms.

Materials and methods

This retrospective single-centre cohort study included patients undergoing surgery for aberrant right subclavian artery at Boston Children's Hospital from January 2017 to December 2022. After approval from Boston Children's Hospital institutional review board (Protocol P00042409), patients were identified from internal departmental databases maintained by the Esophageal and Airway Treatment Center and the Department of Cardiac Surgery at Boston Children's Hospital. Patients with complex cardiac histories, esophageal atresia, or congenital lung malformations were excluded. Patient demographics, pre- and post-operative symptoms, airway and esophageal evaluations, operative techniques, hospital length of stay, and complications were extracted from the medical record.

Comprehensive management of vascular ring and aerodigestive compression syndromes

The Vascular Ring and Airway program at Boston Children's Hospital employs a multidisciplinary approach to the diagnostic evaluation and management of these patients.⁶ In brief, our approach begins with a detailed symptom review during the intake process. Next, patients are presented, and existing studies are reviewed at a multidisciplinary conference that includes specialists from cardiology, pulmonology, gastroenterology, otolaryngology, paediatric thoracic surgery, and congenital cardiac surgery, among others. Initial recommendations are made either for further diagnostic testing or surgical repair. Most patients undergoing surgery for an aberrant right subclavian artery require a pre-operative echocardiogram, three-phase dynamic tracheobronchoscopy, esophagogastroduodenoscopy with esophagram, and computed tomographic angiography. As part of a comprehensive airway evaluation, patients will also have an awake flexible nasolaryngoscopy and a sedated diagnostic laryngoscopy and bronchoscopy for evaluation of vocal fold movement and other laryngeal or glottic pathology, such as laryngeal cleft. The dynamic tracheobronchoscopy is essential for the evaluation of tracheobronchomalacia to assess the degree of airway intrusion from the aberrant subclavian artery.

Starting in 2021, the PEDI-EAT-10 questionnaire⁷ has been used to assess the severity of dysphagia symptoms both pre- and post-operatively. The PEDI-EAT-10 was modified from the adult version, which was used to monitor the severity of dysphagia and treatment efficacy in adults.⁷ The questionnaire has a score that ranges from 0–40, with greater scores reflecting more severe symptoms. The PEDI-EAT-10 has shown good reliability and validity for use in clinical practice to evaluate feeding difficulties in children.⁷ Similarly, our team has developed a tracheobronchomalacia symptom questionnaire (PEDI-TBM-7) to assess respiratory symptoms which yields a score that ranges from 0 to 25, with greater scores indicating more severe respiratory symptoms (Table 1). The PEDI-TBM-7 was developed through a local expert consensus based on the most frequently associated symptoms of tracheobronchomalacia.

Statistical analysis

Statistical analysis was performed using Stata version 17.1 (StataCorp LLC, College Station, Texas). A two-tailed $p < 0.05$ was considered statistically significant. Categorical data are described using frequencies and percentages, and continuous data are presented as median and interquartile range or mean and standard deviation. Fisher's exact test was used to compare presurgical and postsurgical reported symptoms. Paired t-tests

were used to evaluate differences between pre- and post-surgical PEDI-EAT-10 and PEDI-TBM-7 scores when available.

Results

Pre-operative characteristics

During the study timeframe, 20 symptomatic children underwent an operation for an aberrant right subclavian artery. Table 2 shows patient demographic and clinical features. Median age at time of repair was 2 years (IQR 1–11). Two patients (10%) had additional CHDs (atrial septal defect, ventricular septal defect, patent ductus arteriosus; not concurrently repaired), and three patients (15%) had Trisomy 21. On initial evaluation, all patients presented with swallowing symptoms, and 14 patients (70%) also experienced respiratory symptoms.

All but one patient ($n = 19$, 95%) underwent an intraoperative bronchoscopy to evaluate the airway, and 13 patients also underwent a pre-operative bronchoscopy (65%). Of these 19 patients, 11 (58%) were found to have moderate to severe tracheobronchomalacia, defined as $>75\%$ dynamic airway collapse.⁸ The most common regions of collapse included T3 or distal trachea ($n = 10$, 91%), L1 or proximal left mainstem ($n = 4$, 36%), and R1 or proximal right mainstem ($n = 4$, 36%). Additionally, direct laryngoscopy revealed that four patients (20%) had a deep interarytenoid groove or type I laryngeal cleft. All patients underwent a pre-operative esophagram, and 17 patients (85%) also underwent an esophagogastroduodenoscopy. Nearly all who underwent endoscopic evaluation ($n = 16$, 94%) were found to have notable extrinsic compression of the oesophagus (often seen as a posterior indentation in the upper oesophagus). Other diagnostic tests included CT angiography ($n = 20$, 100%), modified barium swallow study ($n = 9$, 45%), flexible nasolaryngoscopy for evaluation of vocal cord function ($n = 15$, 75%), and oesophageal nuclear medicine transit study ($n = 7$, 35%).

Surgical approach

All patients had a right thoracotomy with division of the aberrant right subclavian artery. Fifteen patients (75%) had subclavian to right carotid transposition via the same thoracotomy incision, four patients (20%) underwent ligation and division of the aberrant right subclavian artery only, and one patient (5%) had an interposition graft to the ascending aorta. Nineteen patients (95%) had a rotational esophagoplasty or localised oesophageal mobilisation, 11 patients (55%) had a posterior tracheopexy/bronchopexy, and 6 patients (40%) had a descending posterolateral aortopexy. Fifteen patients (75%) underwent intraoperative recurrent laryngeal nerve monitoring.

Post-operative course/complications

Median hospital length of stay was 5 days (IQR 4–6). There were no mortalities. Re-operation was required in one patient (5%) for recurrent dysphagia due to an oesophageal stricture secondary to pleural adhesions. Four patients (20%) developed low-volume lymphatic chest tube drainage (<110 ml/kg/day), which resolved after transitioning to a low-fat diet. Three patients (15%) developed Horner's syndrome, one resolved prior to discharge, one resolved post-discharge, and one was lost to follow-up. All three of these patients had a paravertebral catheter for post-operative pain control, which is a risk factor for developing transient Horner's

Table 1. PEDI-TBM-7 questionnaire

Parent-reported symptoms		0	1	2	3	4	Total
How would you rate the severity of your child's respiratory symptoms?		Asymptomatic	Mild	Moderate	Severe	Profound	
Does your child have a barking cough?		Absent	With illness	Chronic			
Approximately how many respiratory illnesses has your child had in the last year that required antibiotics or steroids?	Ages 0 to 4	Absent	1-5/yr	6-8/yr	9-12/yr	>12/yr	
	Ages 5+	Absent	2/yr	3-5/yr	6-8/yr	>8/yr	
Approximately how many respiratory illnesses has your child had in the last year that required hospitalization?		Absent			1-2/yr	>2/yr	
Approximately how many respiratory illnesses has your child had in the last year that required supplemental oxygen?		Absent			1-2/yr	>1/yr	
Does your child experience shortness of breath or decreased endurance with activity or exercise?		Absent	Only with illness	Tires with running	Tires with walking		
Has your child experienced blue spells or needed CPR?		Absent				Present	
							/25

Table 2. Patient demographic and clinical data

Demographics	Total patients 2017–2022	20
	Age range (years)	0–15
	Median age (years)	2
Preoperative symptoms and assessment	Respiratory symptoms (%)	70
	Swallowing symptoms (%)	100
	Both respiratory and swallowing symptoms (%)	70
	Moderate to severe tracheobronchomalacia >75% dynamic airway collapse by pre- or intraoperative bronchoscopy (%) (<i>n</i> = 19)	58
	Extrinsic compression of the oesophagus by preoperative endoscopic evaluation (%) (<i>n</i> = 17)	94
Surgical approach	Right Thoracotomy with Division of Aberrant Right Subclavian Artery (%)	100
	Subclavian to Carotid Transposition (%)	75
	Interposition graft to ascending aorta (%)	5
	Esophageal mobilization and lysis of adhesions (%)	95
	Posterior tracheopexy/bronchopexy (%)	55
	Descending posterolateral aortopexy (%)	40
	Intraoperative nerve monitoring (%)	75

syndrome.⁹ One patient (5%) experienced temporary unilateral vocal cord hypomobility that resolved after discharge.

Follow-up

Median follow-up after discharge was 12 months (IQR 7–16). One patient was lost to follow-up. In the majority of patients, there were significant improvements in aerodigestive symptoms post-operatively (Figure 1a–b), including reduced puree/solid food dysphagia (80% to 15.8%, $p < 0.001$), reduced coughing or choking with liquids (50% to 5.3%, $p = 0.003$), reduction in recurrent/prolonged respiratory infections (35% to 5.3%, $p = 0.04$), and reduction in chronic/barky cough (45% to 0%, $p = 0.001$). Six patients had some degree of residual swallowing symptoms, including puree/solid food dysphagia ($n = 3$, 16%), coughing/choking with liquids ($n = 1$, 5%), and disinterest in eating/slow

eating ($n = 2$, 11%). Pre- and post-operative PEDI-EAT-10 and PEDI-TBM-7 scores for 9 patients were available for analysis (Figure 1c). There was a significant improvement from mean \pm SD pre-operative (19.9 ± 9.3) to post-operative (2.4 ± 2.5) PEDI-EAT-10 scores ($p = 0.001$), as well as from pre-operative (8.7 ± 4.7) to post-operative (2.8 ± 4.0) PEDI-TBM-7 scores ($p = 0.006$). Of the 11 patients who had a concomitant tracheobronchopexy, four patients (21%) had persistent respiratory symptoms, including recurrent/prolonged respiratory infections ($n = 1$), dyspnoea on exertion ($n = 2$), and cyanosis/blue spells ($n = 1$). These cyanotic episodes were later attributed to behavioural breath holding. All four patients had severe tracheobronchomalacia in more than one region with bronchial involvement.

Ten patients underwent a post-operative endoscopy for surveillance ($n = 2$) or diagnostic ($n = 8$) purposes secondary to some degree of swallowing difficulty. Endoscopic balloon dilation

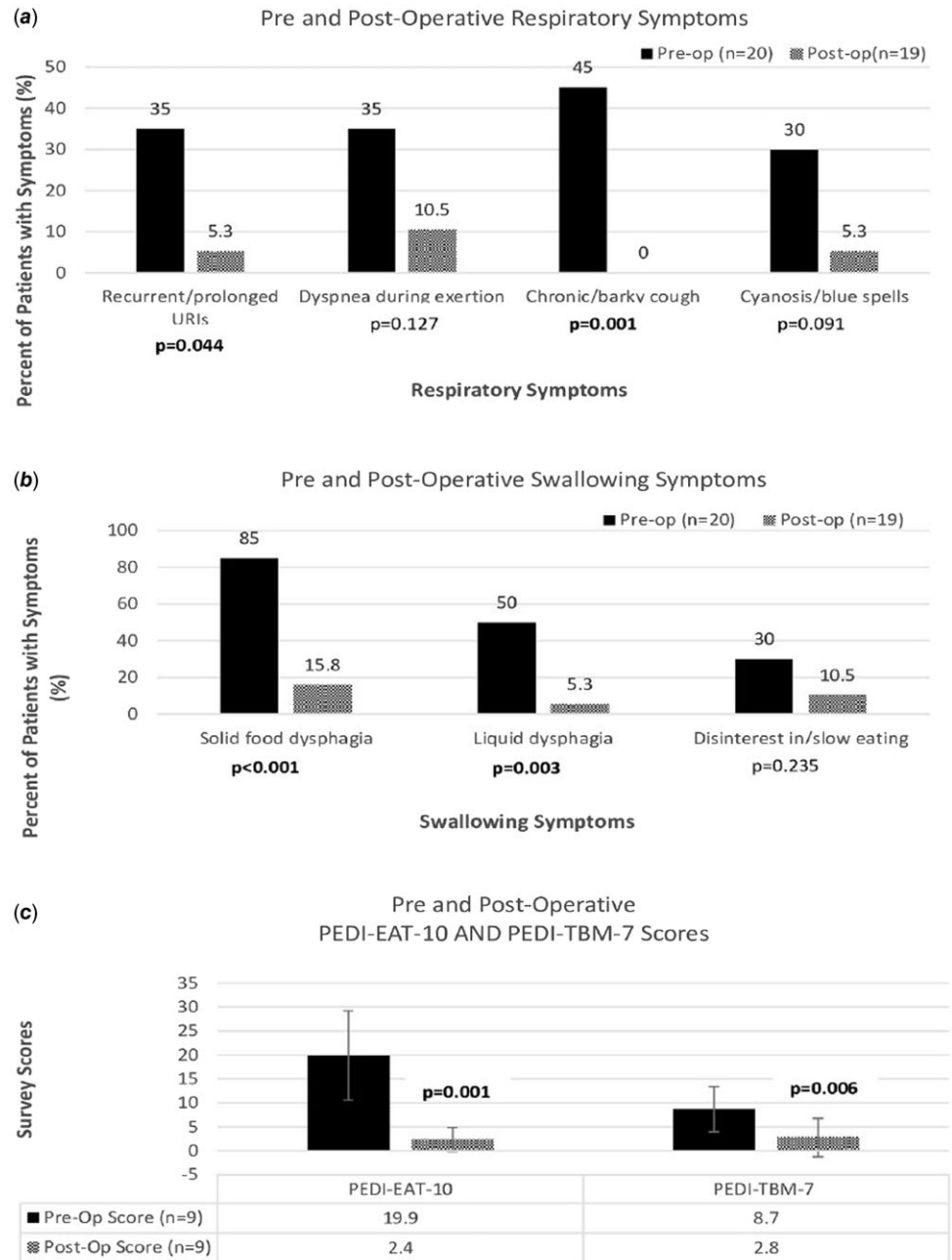


Figure 1. (a) Pre-operative compared to post-operative respiratory symptoms. (b) Pre-operative compared to post-operative swallowing symptoms. (c) Preoperative compared to post-operative PEDI-EAT-10 and PEDI-TBM-7 scores.

was performed in five out of the eight patients who experienced post-operative dysphagia due to narrowing and/or angulation of the oesophagus after localised oesophageal mobilisation ($n = 1$) or rotational esophagoplasty required for tracheopexy ($n = 4$). Of those, two patients experienced complete resolution of symptoms from dilation alone, while two others experienced symptom improvement after laryngeal cleft repair ($n = 1$) and reoperation for an oesophageal stricture ($n = 1$). One patient underwent post-operative oesophageal manometry, which was normal.

Discussion

Management of left aortic arch with an aberrant right subclavian artery is challenging because of the varied symptomatology and the

potential for underdiagnosis due to misattribution of symptoms to gastroesophageal reflux disease, aspiration, or esophagitis. In some cases, patients are labelled “picky eaters”, and the symptoms go underdiagnosed until much later. Even when an aberrant right subclavian artery is noted, it may be overlooked as a contributory factor to the patient’s dysphagia. A comprehensive diagnostic process implemented in a multidisciplinary fashion is the key element in the identification of symptomatic patients who may be able to benefit from surgical intervention. Of symptomatic patients, we found that relief of the vascular compression and mobilisation of the oesophagus significantly relieved symptoms in most instances. Additionally, a large proportion of patients had co-existing tracheobronchomalacia, a previously unreported finding, which if severe, should be treated concurrently when identified.

Pre-operative symptom evaluation

In this report, we reviewed a cohort of children who had undergone repair of their aberrant right subclavian artery. Although all patients presented with dysphagia lusoria, symptoms among our sample varied from solid food dysphagia, problems with swallowing liquids (liquid dysphagia), and slow or disinterest in eating. Liquid dysphagia may be misattributed to aspiration or oropharyngeal dysphagia in infants and is easy to overlook as a symptom of esophageal compression. The challenge of eliciting symptoms from this patient population highlights the importance of a thorough workup tailored to the child's presenting symptoms and performed by a multidisciplinary team with experience in the care of these patients. Patients and their families should be asked explicit questions about both swallowing difficulties and respiratory symptoms. Questions specific to swallowing problems should also address eating patterns and the need for modifying behaviours. Patients who are described as slow or picky eaters or who require their food to be finely chopped may be compensating for swallowing discomfort or dysfunction.

Children experiencing liquid dysphagia should be referred to a speech pathologist for a barium swallow study to evaluate for aspiration. In the presence of aspiration, significant oesophageal extrinsic compression can still be an indication for operation due to its potential contributory effect on aspiration (increased resistance for fluid or food bolus to clear from upper oesophagus). Additionally, upper endoscopies are routinely performed to evaluate the degree of extrinsic oesophageal compressions, which can be subtle but important to note both during static (without insufflation) and dynamic (with insufflation) phases. Endoscopic evaluation can also rule out other potential causes of dysphagia in children and teenagers including eosinophilic esophagitis. In patients with solid food dysphagia that is not definitively explained by the degree of oesophageal compression present, a nuclear medicine oesophageal transit study or a solid food fluoroscopy study can provide additional information about whether solid foods are delayed at the level of the aberrant right subclavian artery.

Patients with vascular rings, including incomplete rings such as aberrant right subclavian arteries, are at risk for secondary tracheobronchomalacia due to compression of the trachea during development and resultant malformation.¹⁰ Fourteen out of 20 patients in this cohort also experienced significant respiratory symptoms, with 11 patients having bronchoscopic evidence of severe tracheobronchomalacia. To our knowledge, this is the first study to document the frequency of tracheobronchomalacia in a series of patients with aberrant right subclavian arteries. For this reason, as part of a comprehensive evaluation, children with aberrant right subclavian arteries should be assessed for respiratory symptoms and undergo an endoscopic airway evaluation. Additional tracheobronchopexy procedures should be considered for patients with quality of life-limiting respiratory symptoms and evidence of significant tracheobronchomalacia on dynamic airway exam. This approach has proven effective at significantly diminishing the risk for recurrent symptoms post-operatively and the need for reoperation after vascular ring repair.¹¹ Adjunctive studies such as pulmonary function tests or cardio-pulmonary exercise testing to assess for obstructive breathing patterns may be useful in older patients who are able to participate.

Subclavian revascularization

We have found that a right thoracotomy with entry in the third interspace provides excellent exposure to the base of the aberrant

right subclavian artery to divide it flush with the aorta to avoid leaving a diverticulum that could continue to cause oesophageal and/or airway compression (Figure 2). Some have advocated for endovascular approaches to cover the orifice of the aberrant right subclavian artery with a stent graft in the aortic arch and then approach subclavian revascularization via a cervical approach.¹² The major disadvantage of this approach in children is the lack of growth potential. Additionally, patients who undergo a hybrid-type repair have an ongoing need for surveillance of the endovascular stent, which may result in a large amount of radiation over time in a young child.

Exposure of the right carotid artery via right thoracotomy can be challenging. By focusing on the apex of the chest, staying posterior to the superior vena cava and innominate vein and anterior to the trachea, proximal and distal control of the carotid artery may be achieved to perform the subclavian to carotid transposition. While some may advocate that it may not be necessary to reimplant the subclavian, we strongly advise examining the perfusion of the right arm before and after test clamping. Any loss of pulsatility (if an arterial line is present in that arm) or a drop of more than 10 mmHg in the mean arterial pressure should prompt one to consider reimplantation. Notably, we did not encounter any complications related to the vascular reimplantation itself. We place patients on aspirin for a month post-operatively and follow them clinically.¹³

Post-operative outcomes

The use of a patient-reported or parent-reported outcomes measure can provide information about the patient's symptoms at a particular point in time and can be used to track outcomes after surgery. Our team has adapted the use of the PEDI-EAT-10 and PEDI-TBM-7 for patients with vascular rings as a method for monitoring patient symptoms and clinical progress. We developed the PEDI-TBM-7 to assess for the unique symptoms that patients with tracheobronchomalacia experience, such as a harsh/barky cough, prolonged or increased frequency of upper respiratory infections, cyanosis, and activity intolerance.¹⁴ Patients or their parents by proxy complete PEDI-EAT-10 and PEDI-TBM-7 questionnaires preoperatively and at follow-up visits 1 month, 6 months, and 1 year post-operatively. The use of these patient-reported outcome measures have been essential in tracking our patient's symptoms over time.

All patients in this study experienced a decrease in the number of respiratory and/or swallowing symptoms after surgery. However, nine patients continued to have at least one symptom after repair. Some patients had comorbid conditions that could have impacted their response to surgical treatment. For instance, two patients met the criteria for obesity and experienced persistent dyspnoea on exertion. Four patients were diagnosed with deep interarytenoid groove or laryngeal cleft and experienced persistent liquid and/or solid food dysphagia. One patient with a diagnosis of Trisomy 21 continued to have oral aversion post-operatively. Additionally, variable follow-up periods could have impacted the results of this study since respiratory and swallowing symptoms may take time to fully resolve after surgery. Four patients with persistent respiratory and/or swallowing symptoms had follow-up periods of less than 1 year. Nonetheless, persistent or recurrent symptoms after surgery can occur and should be discussed with the family prior to surgical interventions to appropriately manage expectations.

Post-operative dysphagia can occur after significant lateral mobilisation of the oesophagus (i.e., rotational esophagoplasty)

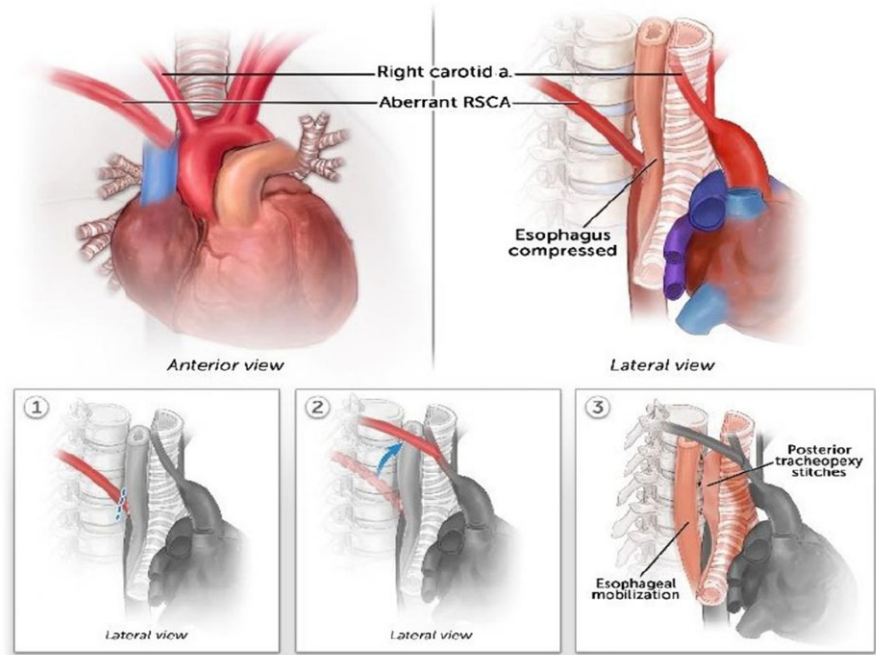


Figure 2. The aberrant right subclavian artery is divided off the aorta and revascularized to the right common carotid artery. The oesophagus is mobilized to allow space for the posterior tracheopexy. This approach provides relief of oesophageal compression and additional support for the trachea if malacia is present. RSCA = right subclavian artery.

and should be discussed preoperatively as a potential complication. Localised oesophageal mobilisation is occasionally needed to release oesophageal adhesions that have the potential to cause recurrent dysphagia symptoms. A rotational esophagoplasty is necessary during a posterior tracheopexy to provide enough space for the posterior wall of the trachea to be sutured to the spine and is occasionally needed to create more space between the trachea and aorta. Our group has observed dysphagia in some post-operative patients due to narrowing where the oesophagus makes an abrupt angle after being mobilised. From a technical standpoint, this can be minimised with careful attention to the extent of mobilisation, awareness of the baseline position of the esophagus, and can be assessed intraoperatively with flexible endoscopy when in doubt. This post-pxy dysphagia phenomenon has also been described by Torre and colleagues, who found post-operative dysphagia to occur in patients who required significant displacement of the oesophagus during posterior tracheopexy procedures.¹⁵ Five patients in our study underwent post-operative endoscopic balloon dilation to treat dysphagia thought to be associated with narrowing at the site of oesophageal angulation. However, only two patients experienced complete resolution of dysphagia symptoms with dilation alone, which demonstrates that dysphagia is often multifactorial and additional testing may be necessary. Eosinophilic esophagitis is important to rule out since inflammation of the oesophagus can lead to dysphagia, which can be treated non-invasively. Additionally, oesophageal manometry may be useful for determining whether oesophageal dysmotility from vagal nerve injury or prolonged oesophageal compression is contributing to swallowing symptoms. Its role in the pre-operative evaluation remains unclear yet warrants investigation. In general, our complication profile seems to be transient and comparable to what others have reported.¹⁶

Twenty percent of patients in this series developed post-operative lymphatic chest tube drainage. The thoracic duct is intimately related to the aberrant subclavian artery, so the mobilisation of the aberrant artery itself puts the thoracic duct at risk. Additionally, a posterior tracheopexy requires more mobilisation of the soft tissues to clear the anterior longitudinal

ligament of the spine and could increase the risk of chylothorax. However, prior work from our team showed that the risk of chyle leak was greater when a descending aortopexy was performed in addition to the posterior tracheopexy¹⁷; thus, dissection of the area is a bigger risk factor for thoracic duct injury and should be discussed with the family as a potential complication after surgery. Fortunately, all chyle leaks were transient and resolved with conservative management.

The timing of surgical repair is controversial, though most agree that symptoms should guide surgical treatment, the ideal age at which to pursue surgical management is debatable. Adult literature suggests that outcomes are worse in symptomatic patients and in those undergoing urgent operations, particularly in the setting of impending or actual diverticular rupture. Hence, some recommend surgery earlier in life, when patients are better candidates for open surgical approaches when compared to endovascular or hybrid modalities (more common in adults), given the lower likelihood of reintervention and lower early mortality rate.¹⁸

Limitations

There are several limitations to this study, including the retrospective nature, small sample size, single quaternary referral centre, and lack of long-term follow-up. However, despite these limitations, a statistically significant improvement in symptoms was observed. Given the significant potential impact on patient quality of life, a prospective multi-center study may provide greater insight into the nature of the disease process and provide a greater understanding of the scope of disease. This may be particularly important given the potential for referral or selection bias as most patients in our study were referred from other institutions or through parents seeking a second opinion after being told there was nothing that could be done for their child; thus, the pre-test probability of symptomatic disease and comorbid airway disease could be greater than that of the general population. Another limitation is that we did not compare the presence and/or size of a possible diverticulum (at the origin or base of the aberrant right

subclavian) with symptom occurrence or treatment response. Some have advocated that in adults with an aberrant right subclavian artery, the presence of a diverticulum and its size correlates with the number of symptoms and response to surgical therapy.¹⁶ Future research should explore this relationship in children, in addition to the relevance of the anteroposterior distance between the spine and the sternum, as the impact of a large aberrant subclavian in a narrow space may be more pronounced than a small artery in a child with a large chest. Lastly, the PEDI-TBM-7 has not yet been validated. However, a respiratory patient-reported outcome measure that captures tracheobronchomalacia-related symptoms has not been developed and validated, and thus, the development of the novel PEDI-TBM-7 could have implications for future research. The next steps will involve reliability and validity testing with a larger group of tracheobronchomalacia patients.

Conclusion

In conclusion, children with left aortic arch and aberrant right subclavian artery can present with a variety of swallowing and respiratory symptoms. A comprehensive review of symptoms and multidisciplinary evaluation are crucial for determining whether surgical intervention is indicated. Symptomatic patients with airway or oesophageal compression from an aberrant right subclavian artery should be considered for surgical treatment even if presenting symptoms are atypical and do not include solid food dysphagia. Relieving the oesophagus of compression by either ligating and dividing or transposing the subclavian artery while also mobilising the oesophagus is effective in relieving symptoms in most patients. Moreover, posterior tracheobronchopexy is an effective adjunct for patients with comorbid tracheobronchomalacia, which occurs frequently in this population. Though most experience improvement, a small proportion of patients can experience partial symptom resolution or continue with persistent symptoms. Thus, providing appropriate counselling and setting expectations are also critical elements in the process.

Acknowledgements. We thank the following individuals for their expertise and assistance in writing this manuscript. Dr Leah Frain, Advanced Practice Registered Nurse in the Division of Pulmonary Medicine at Boston Children's Hospital, and Dr Gary Visner, Medical Director of the Lung Transplant Program and Attending Physician in the Division of Pulmonary Medicine at Boston Children's Hospital, developed and tested initial versions of PEDI-TBM-7. Dr Mariana Chavez, Research Fellow in Cardiac Surgery at Boston Children's Hospital, drafted the IRB protocol and helped to identify eligible patients within the Department of Cardiac Surgery database. Rosella Micalizzi and Nicole Palumbo, Advance Practice Registered Nurses in the Department of Surgery at Boston Children's Hospital, helped with data entry for the Esophageal and Airway Treatment Center Database.

Financial support. This research received no specific grant from any funding agency, commercial, or not-for-profit sectors.

Competing interests. None.

References

- Nelson JS, Hurtado CG, Wearden PD. Surgery for dysphagia lusoria in children. *Ann Thorac Surg* 2020; 109: e131–e133.
- Epperson MV, Howell R. Dysphagia lusoria: problem or incidentaloma? *Curr Opin Otolaryngol Head Neck Surg* 2019; 27: 448–452.
- Polguy M, Chrzanowski Ł., Kasprzak JD et al. The aberrant right subclavian artery (arteria lusoria): the morphological and clinical aspects of one of the most important variations—a systematic study of 141 reports. *TheScientificWorld* 2014; 2014: 292734–292736.
- Coles M, Sharma A. Dysphagia lusoria: Is the dysmotility connection illusory or real? *Dig Dis Sci* 2020; 65: 942–945.
- Dranseika V, Erdil T, Schweiger M, Balmer C, Pretre R, Dave H. Dysphagia and an aberrant subclavian artery: more than just a coincidence. *Interact Cardiovasc Thorac Surg*, 2020; 31: 228–231.
- Chiu P, Zendejas B, Baird C. Multidisciplinary approach to vascular rings and vascular-related aerodigestive compression: a clinical practice review. *Transl Pediatr* 2023; 12: 1258–1277.
- Serel Arslan S, Demir N, Karaduman AAŞe, Belafsky PC. The pediatric version of the eating assessment tool: a caregiver administered dysphagia-specific outcome instrument for children. *Disabil Rehabil* 2018; 40: 2088–2092.
- Kamran A, Zendejas B, Jennings RW. Current concepts in tracheobronchomalacia: diagnosis and treatment. *Semin Pediatr Surg* 2021; 30: 151062.
- Sripriya R, Prabavathy G. Horner's syndrome following thoracic paravertebral block—radiological evidence of spread to stellate ganglion and fascial anatomy facilitating the spread. *Asian J Anesthesiol* 2022; 60: 87–88.
- Choi S, Lawlor C, Rahbar R, Jennings R. Diagnosis, classification, and management of pediatric tracheobronchomalacia: a review. *JAMA Otolaryngol Head Neck Surg*, 2019; 145: 265–275.
- Labuz DF, Kamran A, Jennings RW, Baird CW. Reoperation to correct unsuccessful vascular ring and vascular decompression surgery. *J Thorac Cardiovasc Surg* 2022; 164: 199–207. DOI: [10.1016/j.jtcvs.2021.08.089](https://doi.org/10.1016/j.jtcvs.2021.08.089).
- Tallarita T, Rogers RT, Bower TC et al. Characterization and surgical management of aberrant subclavian arteries. *J Vasc Surg* 2023; 77: 1006–1015.
- Nguyen D, Leon LR, Berman SS. Hybrid repair of aberrant right subclavian artery using open and endovascular techniques. *J Vasc Surg Cases Innov Tech* 2023; 9: 101307.
- Shieh HF, Smithers CJ, Hamilton TE et al. Posterior tracheopexy for severe tracheomalacia. *J Pediatr Surg* 2017; 52: 951–955.
- Torre M, Reali S, Rizzo F et al. Posterior tracheopexy for tracheomalacia: study of clinical and radiological consequences on esophagus. *Eur J Pediatr Surg* 2023; 34: 306–313.
- Griffeth EM, Stephens EH, Dearani JA et al. Outcomes of surgical repair of aberrant subclavian arteries in adults. *Ann Thorac Surg* 2024; 117: 396–402.
- Svetanoff WJ, Zendejas B, Frain L et al. When to consider a posterolateral descending aortopexy in addition to a posterior tracheopexy for the surgical treatment of symptomatic tracheobronchomalacia. *J Pediatr Surg* 2020; 55: 2682–2689. DOI: [10.1016/j.jpedsurg.2020.04.018](https://doi.org/10.1016/j.jpedsurg.2020.04.018).
- Bath J, D'Oria M, Rogers RT et al. Contemporary outcomes after treatment of aberrant subclavian artery and kommerell's diverticulum. *J Vasc Surg* 2023; 77: 1339–1348.e6.