



Images in Congenital Cardiac Disease

Cite this article: Pham TTM, Huynh TTM, and Vu PN (2024) A case of a tetralogy of Fallot patient treated only with classic Blalock–Taussig–Thomas shunt in modern life. *Cardiology in the Young* **34**: 2014–2015. doi: [10.1017/S1047951124025666](https://doi.org/10.1017/S1047951124025666)

Received: 12 February 2024
Revised: 11 May 2024
Accepted: 15 July 2024
First published online: 26 September 2024

Keywords:

Congenital cyanosis heart disease; tetralogy of Fallot; classic Blalock–Taussig–Thomas shunt; Blalock–Taussig–Thomas shunt

Corresponding author:

Thuy Thuc Minh Pham;
Email: bsminhthuy@gmail.com

A case of a tetralogy of Fallot patient treated only with classic Blalock–Taussig–Thomas shunt in modern life

Thuy Thuc Minh Pham^{1,2} , Thuy Thi Minh Huynh¹ and Phuc Nang Vu^{1,2}

¹Tam Anh General Hospital, Hochiminh City, Viet Nam and ²Medical and Pharmacy University of Hochiminh City, Hochiminh City, Vietnam

Abstract

We showed images of classic Blalock–Taussig–Thomas shunt in a 35-year-old male patient with tetralogy of Fallot who underwent palliative surgery in 1992. It is a rare image echocardiography in our modern life.

The classic Blalock–Taussig–Thomas shunt is a breakthrough in the treatment of cyanotic CHD [1], specifically the tetralogy of Fallot. The baby first underwent surgery and then passed away due to some complications. Therefore, the classic Blalock–Taussig–Thomas shunt, using the left subclavian artery to supply blood flow to the pulmonary artery, was gradually replaced by the modified Blalock–Taussig shunt in later palliative surgeries. Hence, nowadays, it is a rare chance for young doctors to meet a classic Blalock–Taussig–Thomas shunt image on current practicing echocardiography. The images from a 35-year-old male patient with the Fallot came to our hospital for a cardiovascular check-up. More than 30 years after his first surgery to repair Fallot with only a classic Blalock–Taussig–Thomas shunt and lost follow-up after that. An imaging examination showed good classic Blalock–Taussig–Thomas shunt flow. More than 30 years after his first surgery to repair Fallot with only a classic Blalock–Taussig–Thomas shunt, an imaging examination showed good classic Blalock–Taussig–Thomas shunt flow. A natural stenosis at the shunt anastomosis with aliasing in colour Doppler and high velocity 3.9 m/s, high-pressure gradient 63 mmHg in echocardiography. The patient so far has almost no clinical symptoms, 94% saturation in room air. Interesting images on echocardiography and cardiac CT reminded us about historical milestones in the surgery of cyanosis CHD.

Financial support. No funding.

Completing interests. The authors declare that they have no conflict of interest.

Ethical standards. This clinical case involves a human participant and, using echocardiography and CTA images was in accordance with the ethical standards of institutional and national research committee.

Reference

1. Blalock A, Taussig HB. Landmark article May 19, 1945: the surgical treatment of malformations of the heart in which there is pulmonary stenosis or pulmonary atresia. *JAMA* 1984; 251: 2123–2138. DOI: [10.1001/jama.1984.03340400051025](https://doi.org/10.1001/jama.1984.03340400051025).

© The Author(s), 2024. Published by Cambridge University Press. This is an Open Access article, distributed under the terms of the Creative Commons Attribution licence (<https://creativecommons.org/licenses/by/4.0/>), which permits unrestricted re-use, distribution and reproduction, provided the original article is properly cited.



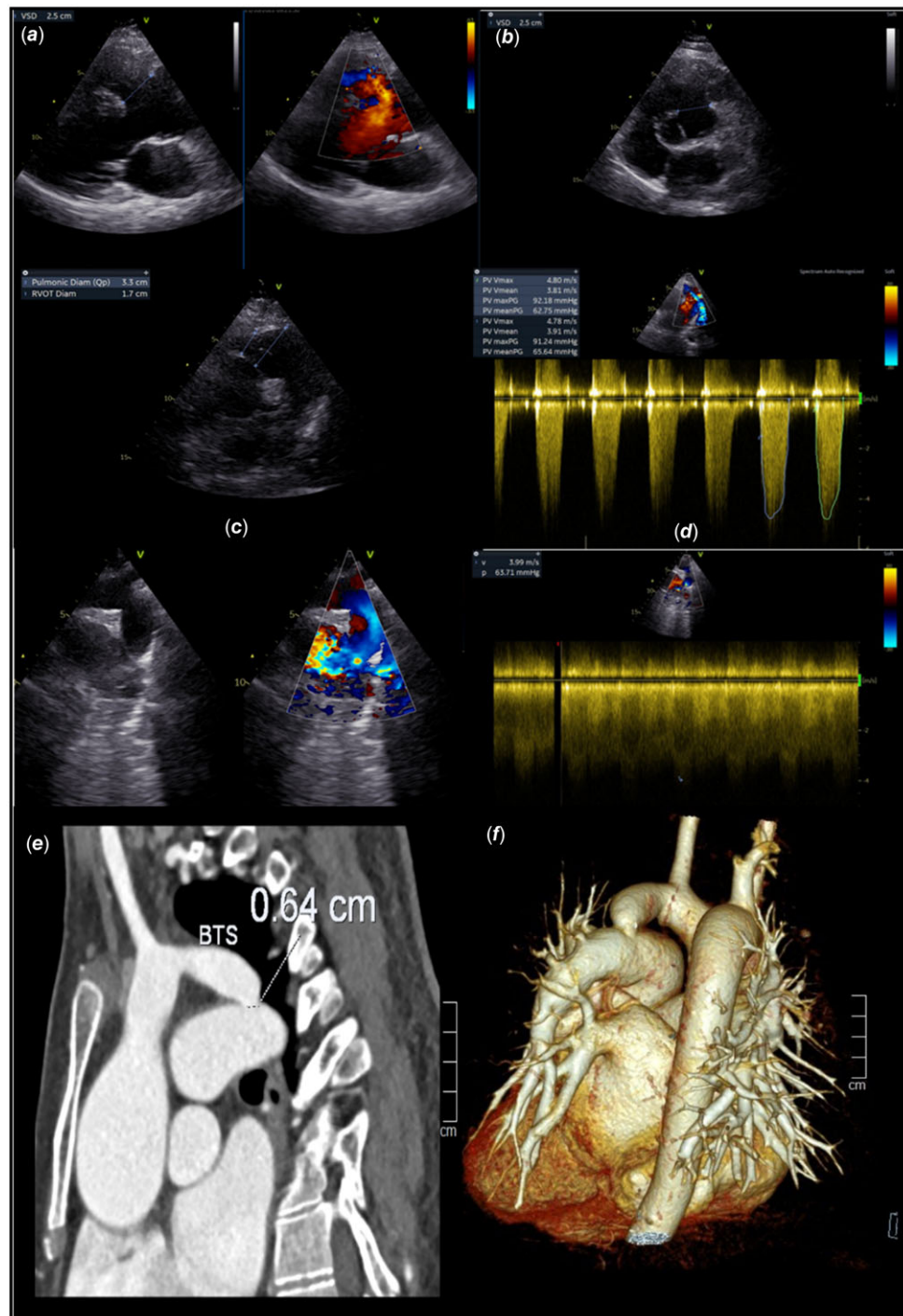


Figure 1. A-F: Echocardiography: Two-dimensional echocardiography with Doppler reveals uncorrected tetralogy of Fallot with an overriding aorta (A), a large perimembranous ventricular septal defect (A, B), right outflow tract stenosis (C, D) with high-pressure gradient of 92/62 mmHg, and marked right ventricular hypertrophy. In addition, it showed patent classic Blalock-Taussig-Thomas shunt between the left subclavian artery and the left pulmonary artery (E) with aliasing at the anastomosis with a pressure gradient of 63 mmHg (F). **G:** multi-slice computed tomography reconstruction showed the classic Blalock-Taussig-Thomas shunt. Noted a 6.4 mm anastomosis stenosis (white arrow), the dilated left pulmonary artery, and the right aortic arch.