



## Letter to the Editor: New Observation

# Prominent Frontal Bossing Following Subtotal Resection and Progression of Meningioma

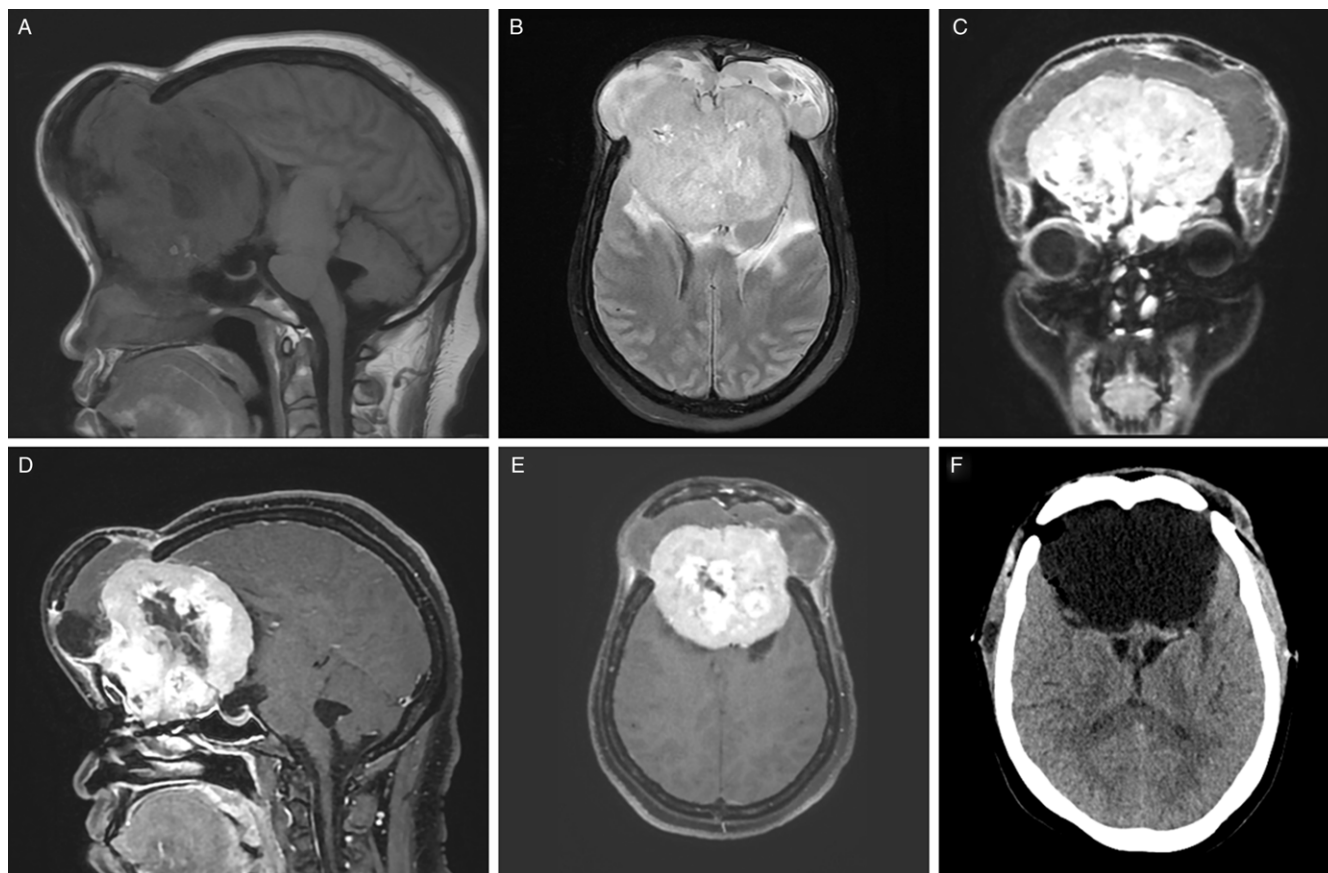
Jessica D. White, Sanghee Lim, Bryan J. Neth , Ivan D. Carabenciov, Derek Stitt and Rafid Mustafa 

Department of Neurology, Mayo Clinic, Rochester, MN, USA

**Keywords:** Health care disparities; meningioma; subtotal resection

A 40-year-old Kenyan woman presented locally with headache, nausea, and vision changes. A 5 cm olfactory groove meningioma was discovered; she underwent subtotal resection. Over the following two years, she developed progressive dizziness, nausea, gait instability, and visual loss prompting medical evaluation at our institution. Physical examination demonstrated blindness, vertical

gaze palsy, and prominent frontal bossing. Magnetic resonance imaging of brain revealed a 9 cm enhancing mass arising from the cribriform plate with elevation of an ununited overlying frontal craniotomy flap (Figure 1). She underwent successful resection (Figure) with pathology demonstrating Central Nervous System World Health Organization (CNS WHO) Grade 1 meningioma.



**Figure 1:** Large olfactory groove meningioma with elevation of an ununited overlying frontal craniotomy flap. Sagittal T1 Fluid-attenuated inversion recovery (FLAIR) (A), axial T2 FLAIR (B), coronal T1 post-gadolinium (C), sagittal T1 post-gadolinium (D), and axial T1 post-gadolinium (E) Magnetic resonance imaging of brain sequences demonstrating a 9 cm olfactory groove meningioma with areas of internal necrosis and mineralization, notable mass effect on surrounding brain parenchyma, and chronic elevation of an ununited overlying frontal craniotomy flap. Successful resection of the olfactory groove meningioma is shown on non-contrast computed tomography of head (F).

**Corresponding author:** Rafid Mustafa; Email: [mustafa.rafid@mayo.edu](mailto:mustafa.rafid@mayo.edu)

**Cite this article:** White JD, Lim S, Neth BJ, Carabenciov ID, Stitt D, and Mustafa R. (2024) Prominent Frontal Bossing Following Subtotal Resection and Progression of Meningioma. *The Canadian Journal of Neurological Sciences* 51: 707–708, <https://doi.org/10.1017/cjn.2023.292>

© The Author(s), 2023. Published by Cambridge University Press on behalf of Canadian Neurological Sciences Federation.

Low-grade meningiomas with subtotal resection carry significantly shorter recurrence-free survival rates than those with gross total resection.<sup>1</sup> In this patient, bone flap displacement from prior craniotomy allowed interval tumor growth while minimizing mass effect on brain parenchyma. This case highlights known global health disparities in low-grade meningioma management related to appropriate healthcare access in underserved patients.<sup>2</sup>

**Competing interests.** Dr Mustafa has consulted with Horizon Therapeutics regarding educational content for neuromyelitis optica spectrum disorders and neurohospitalist practice.

The remaining authors (Drs. White, Lim, Neth, Carabenciov, and Stitt) report no disclosures.

## References

1. Oya S, Kawai K, Nakatomi H, Saito N. Significance of Simpson grading system in modern meningioma surgery: integration of the grade with MIB-1 labeling index as a key to predict the recurrence of WHO Grade I meningiomas. *J Neurosurg.* 2012;117:121–8.
2. Jackson HN, Hadley CC, Khan AB, et al. Racial and socioeconomic disparities in patients with meningioma: a retrospective cohort study. *Neurosurgery.* 2022;90:114–23.