

Sick LADy

Peter G. Katis, MD

A 72-year-old woman was referred to the emergency department (ED) after experiencing chest pain during a graded exercise stress test (GXT). Shown in Figure 1 are the results of her electrocardiogram (ECG), recorded at 2 minutes of exercise. The pain had subsided 10 minutes after cessation of the GXT and following a single administration of nitroglycerine spray. On arrival to the ED, the patient was asymptomatic. The ECG was repeated, and results are shown in Figure 2 on the following page.

This patient had been well up until 2 weeks earlier, when she first began experiencing chest pain on exertion that would resolve within 10 minutes of rest. Her baseline ECG (not shown here) was identical to the one recorded in the ED (Fig. 2). She had no previous cardiac history, but was

an ex-smoker who suffered from diabetes and hypertension. Vital signs, physical examination, and chest x-ray were unremarkable. A baseline troponin-I (TnI) was ordered, and the results were normal.

Your diagnosis is:

- A. stable angina
- B. Wellens' syndrome
- C. myocardial infarction
- D. pericarditis
- E. Prinzmetal's angina

For the Answer to this Challenge, see page 135.

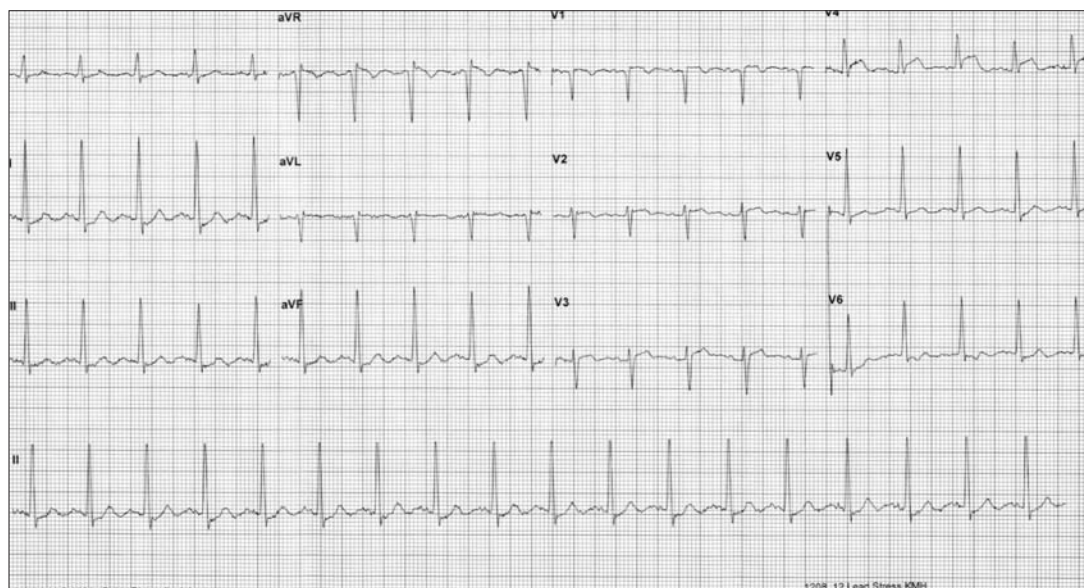


Fig. 1. ECG recorded at 2 minutes of exercise, during a graded exercise stress test.

Assistant Medical Director, Emergency Medicine, University Health Network, Toronto, Ont.; Lecturer, Department of Family and Community Medicine, University of Toronto, Toronto, Ont.

Received: Nov. 25, 2003; accepted: Jan. 15, 2004

This article has been peer reviewed.

Can J Emerg Med 2004;6(2):130-1

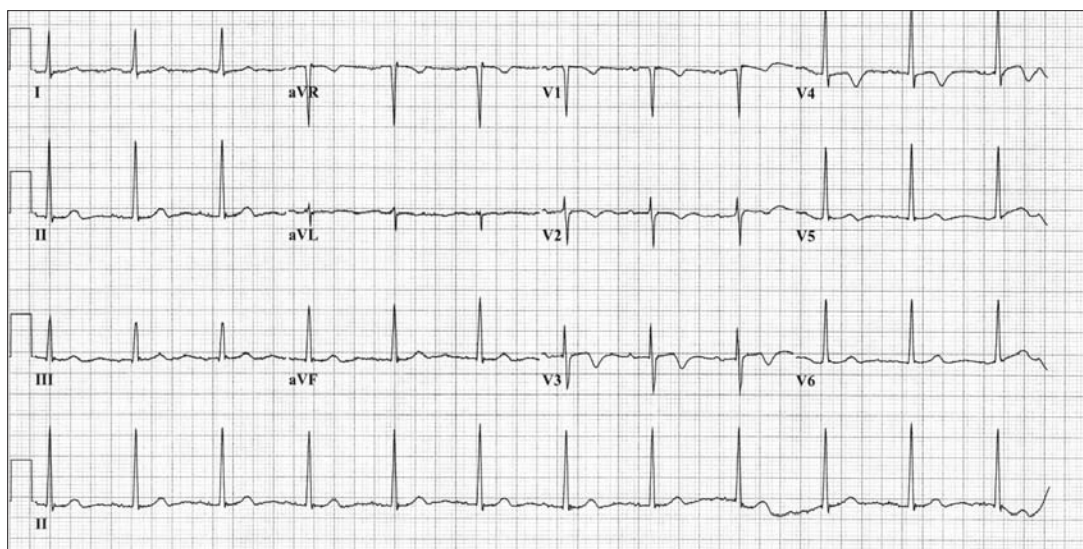


Fig. 2. Results of patient's 2nd ECG, taken in the ED.

Order your copy now

To order your copy please contact:

Brenda Brady, Membership Services
Canadian Association of Emergency Physicians
 tel.: (613) 523-3343 or 1-800-463-1158;
 fax: (613) 523-0190; email: drugmanual@caep.ca

