

## Research Paper

**Cite this article:** Ashoush SE, Saeed ZM and Soliman EK (2024). Antioxidant and anti-inflammatory effects of ellagic acid as a new therapy for *Trichinella spiralis* infection. *Journal of Helminthology*, **98**, e78, 1–8 <https://doi.org/10.1017/S0022149X24000683>

Received: 15 July 2024  
Revised: 23 September 2024  
Accepted: 24 September 2024

**Keywords:**  
trichinellosis; ellagic acid; albendazole; IL-6; IL-10; oxidative stress; NO

**Corresponding author:**  
S.E. Ashoush;  
Emails: [shaimaashoush@gmail.com](mailto:shaimaashoush@gmail.com);  
[sheashoush@zu.edu.eg](mailto:sheashoush@zu.edu.eg)

# Antioxidant and anti-inflammatory effects of ellagic acid as a new therapy for *Trichinella spiralis* infection

S.E. Ashoush<sup>1</sup> , Z.M. Saeed<sup>2</sup>  and E.K. Soliman<sup>3</sup> 

<sup>1</sup>Medical Parasitology Department, Faculty of Medicine, Zagazig University, Zagazig 44519, Egypt; <sup>2</sup>Clinical Pharmacology Department, Faculty of Medicine, Zagazig University, Zagazig 44519, Egypt and <sup>3</sup>Medical Biochemistry Department, Faculty of Medicine, Zagazig University, Zagazig 44519, Egypt

## Abstract

Trichinellosis is a widespread food-borne zoonosis, causing mild to severe illness in humans with potential fatality. Its treatment remains challenging due to the side effects and limited efficacy of specific drugs. Therefore, the current study was conducted to assess the therapeutic effects of ellagic acid (EA) alone and combined with albendazole against trichinellosis and its biochemical and pathological alterations in mice. Mice were divided into two main groups: G1 and G2 for the intestinal and muscular phases, respectively. Then each group was subdivided into five sub-groups: (a) non-infected control, (b) infected control non-treated, (c) infected and treated with EA, (d) infected and treated with albendazole, and (e) infected and treated with a combination of both. Parasitological, biochemical, and histopathological studies were used to evaluate the therapeutic outcomes. Treatment with EA resulted in a significant reduction of the mean counts of intestinal adult worms and muscular larvae compared to the infected control. EA improved oxidative stress as it reduced nitric oxide and increased catalase activities in intestinal and muscular tissues. Additionally, it alleviated the inflammatory response, as evidenced by down-regulating IL-6 and increasing IL-10 expressions in tissues. Furthermore, it improved liver functions and ameliorated the pathological alterations induced by trichinellosis. The best results were detected in combination treatments that indicated synergistic effects between EA and albendazole. In conclusion, EA can be used as an anti-inflammatory and antioxidant with a promising anti-parasitic impact against trichinellosis.

## Introduction

*Trichinella spiralis* (*T. spiralis*) is a zoonotic roundworm that causes *trichinellosis*. Trichinellosis is one of the most significant foodborne parasitic infection worldwide according to WHO (2021). It is considered a public health hazard and a dangerous threat to meat and food safety (Bai *et al.*, 2017). A large number of cases occurs annually by eating raw or undercooked pork or its products containing infective larvae (Basso *et al.*, 2022).

*T. spiralis* adult worms live in the intestinal mucosa of mammals, birds, and reptiles and the larvae are established in skeletal muscle. Therefore, the course of *T. spiralis* infection in humans consists of two major phases: intestinal phase, which is characterised by abdominal pain, diarrhea, nausea, and vomiting and the muscular phase, which is caused by the inflammatory and allergic responses induced by muscular invasion and may be accompanied with fever, myalgia, eosinophilia, and eyelid edema (Bruschi, 2014).

When larvae invade skeletal muscle cells, this leads to major cell modifications (Farid *et al.*, 2019), transforming the fully differentiated muscle cells into nurse cells. These cells are consisted of host-derived collagenous capsule that sustain the muscle larvae and cellular components (Xu *et al.*, 2017). This larval invasion can damage muscle cells directly or indirectly by stimulating inflammatory cell infiltration and altering pro-inflammatory cytokines and antioxidant capacity, leading to tissue damage (Gottstein *et al.*, 2009; Soliman *et al.*, 2013). Furthermore, the oxidative stress that occurs during trichinellosis is considered one of the major causes of tissue damage. Extreme amounts of reactive oxygen species, nitrogen species, and free radicals are produced by the activation of recruited inflammatory cells (Chiumiento & Bruschi, 2009). Additionally, elevated levels of many stress indicators, such as malondialdehyde and superoxide dismutase, were detected (Othman *et al.*, 2016).

The prevalence of trichinellosis is rising worldwide because of treatment difficulties. These difficulties are attributed to limited effectiveness of the specific medications to inhibit migrating and encysted larvae. Benzimidazole derivatives, such as mebendazole and albendazole, are the main antiparasitic drugs used against trichinellosis. However, their action is insufficient against the encapsulated larvae besides increasing resistance to them. Furthermore, they exhibited low water solubility that makes their absorption from the intestinal lumen limited and results in low

bioavailability (Khalikov, 2021). In addition, mebendazole has shown teratogenicity in various experimental animals (de la Torre-Iglesias *et al.*, 2014). Accordingly, natural medications and potent antioxidants are fundamentally needed (Nada *et al.*, 2018).

Ellagic acid (EA) is a valuable bioflavonoid found in various vegetables, fruits, and berries. EA is a thermostable dilactone of hexahydroxydiphenic acid (Vattem *et al.*, 2005). EA has effective antioxidant activities and important therapeutic benefits on the limitation of many chronic pathological disorders associated with oxidative stress, so it takes huge attention from biomedical researchers (Shakeri *et al.*, 2018). Additionally, it has numerous health profits such as anti-inflammatory, antibacterial, antiviral, anticancer, hepatoprotective, gastroprotective, and cardio-protective properties (Evtyugin *et al.*, 2020).

Ellagic acid has been studied for its anti-parasitic effect in various studies. It showed significant therapeutic effects against malaria (Soh *et al.*, 2009), and leishmaniasis (Alves *et al.*, 2020). Accordingly, the current work was planned to assess the effectiveness of EA alone and combined with albendazole against *Trichinella* infection. To our knowledge, it is the first study that evaluates the effects of EA on trichinellosis.

## Material and methods

### Experimental animals and parasite

We used 60 Swiss albino male mice, 20–25 g in weight that were provided by Theodor Bilharz Research Institute, Egypt. *T. spiralis* larvae were taken from infected pig muscles in Cairo Slaughter House, Cairo, Egypt. The parasite was maintained at the Theodor Bilharz Research Institute. Larvae were recovered using acid-pepsin digestion method (Mayer-Scholl *et al.*, 2017). Mice were infected orally by 200–250 larvae per mouse in accordance with Dunn & Wright's (1985).

### Ethical approval

Institutional Animal Care and Use Committee at Zagazig University approved the current study. The approval number is ZU-IA-CUC/3/F/30/2024.

### Drugs

A commercial albendazole (Alzental) suspension (Eipico, Egypt) containing 20 mg/mL was utilised. Mice were given 50 mg/kg/d of albendazole orally for 3 days (Esmat *et al.*, 2021). Ellagic acid powder (Sigma-Aldrich, St Louis, MO, USA) was dissolved in saline and administered orally at 20 mg/kg/d for 7 days (Khan *et al.*, 2021). Mice in combination group received the same doses.

### Experimental design

There were two main groups of mice: G1 for the intestinal phase, which initiated treatment on the first day post infection (dpi) and sacrificed at eighth dpi; and G2 for the muscular phase, which started treatment on the 30th dpi and sacrificed at 42 dpi. Each group was divided into five subgroups (six mice each) as follows: (a) control non-infected; (b) control infected and non-treated; (c) infected and treated with EA; (d) infected and treated with albendazole; and (e) infected and received a combination of both.

## Parasitological assessment

### Adult worm isolation and counting

The small intestine was taken from mice in G1 and washed to remove intestinal contents. Then it was opened longitudinally, divided into small parts of 2 cm, and placed in normal saline at 37°C for 3 hours. Washing of intestinal parts was done three times. The collected fluids were then centrifuged at 1500 rpm for 5 minutes, after which the supernatant fluid was removed, and the sediment was examined to count adult worms using the dissecting microscope (Denham, 1965; Issa *et al.*, 1998).

### Counting of muscle larvae

Muscle specimens were taken from each mouse of G2. The specimens were weighed and then digested by pepsin-HCl to make larvae out. The larval count was calculated per gram of muscle according to García *et al.* (2013).

For evaluating drug efficacy, the reduction percent (R%) was calculated: [(mean parasite count in controls - mean count in treated group) / mean count in controls] × 100% (Saad *et al.*, 2016).

## Biochemical analysis

**Serum biochemical analysis** Blood samples collection was done in Eppendorf tubes. After clotting, they were centrifuged at 1500 rpm for 15 min at 4°C to get the serum, which was stored at -20°C. Alanine aminotransferase (ALT) and aspartate aminotransferase (AST) were estimated by a colorimetric method in serum by kits bought from Spinreact, Girona, Spain, according to the kit's guidelines.

**Collection and preparation of tissue samples** The intestinal and muscular samples were washed with ice-cold saline, divided into lesser parts, weighed, and then homogenised with a proper volume of 50 mM saline phosphate buffer, pH 7.4. The homogenate was centrifuged, and the supernatant was stored at -80°C until use for determination of nitric oxide (NO) level and catalase enzyme activity by a colorimetric method. Small tissue samples were immersed in RNA later and stored at -80°C for gene expression detection of interleukin-6 (IL-6) and interleukin-10 (IL-10) by using quantitative real-time polymerase chain reaction (qRT-PCR).

**Assessment of oxidative stress markers in intestinal and muscle tissues** Nitric oxide level and catalase enzyme activity were measured using commercial kits from Biodiagnostic, Dokki, Giza, Egypt. Colorimetric test was performed as described by Montgomery and Dymock (1961) and Aebi (1984), respectively.

**qRT-PCR for IL-6 and IL-10 gene expression in intestinal and muscle tissues** (Schmittgen & Livak, 2008).

Total RNA was separated with TRIzol Reagent (Invitrogen; Thermo Fisher Scientific, Inc.). RNA quality was tested by the A260/A280 ratio that was done by the NanoDrop ND-1000 Spectrophotometer (NanoDrop Technologies; Wilmington, Delaware, USA). The step of reverse transcription and complementary DNA (cDNA) formation was carried out by HiSenScriptTMRH [-] for the cDNA Synthesis Kit, INtRON Biotechnology, China. The gene expression analysis was performed by qRT-PCR using SYBR Green 2x Master Mix Green (QuantiTect SYBR Green PCR Kits, Qiagen). PCR was done using the Mx3005P RT-PCR System (Agilent Stratagene, USA) according to the manufacturer's instructions to detect IL-6 and IL-10 relative expressions. The amplification procedure was as follows: 95°C for 5 min, followed by 35 cycles of 95°C for 30 s, 53°C for 30 s, and 72°C for 30 s, and a final

**Table 1.** IL-6 and IL-10 primer sequences for qRT-PCR

	Forward primer (5'–3')	Reverse primer (5'–3')	Accession no.	Product length
IL-6	CATGTTCTCTGGGAAATCGTGG	GTACTCCAGGTAGCTATGGTAC	NM_001314054.1	210
IL-10	CGGGAAGACAATAACTG	CATTCCGATAAGGCTTGG	NM_010548.2	186

incubation of 72°C for 5 min. GAPDH was used as a reference gene. Table 1 shows the primers used in our research.

### Histopathological examination

Tissue specimens were taken from small intestine and muscles. They were fixed by immersion in 10% formalin, washed in water, then dehydrated in ascending grades of alcohols. The samples were then cleared in xylene and embedded in paraffin blocks. Microtome was used to make 5- $\mu$ m thickness sections from these blocks. The hematoxylin and eosin method was used for staining (Banchroft *et al.*, 1996).

### Statistical analysis

SPSS version 25 (IBM, Armonk, NY, USA) was used for data analyses. Quantitative data were presented as mean  $\pm$  SD. ANOVA (f) test was utilised for comparison between three or more groups having quantitative variables, comparison between groups was done using least significant difference method. A P value < 0.05 indicated statistical significance.

## Results

### Anti-parasitic effects

Treated groups G1c, G1d, and G1e revealed statistically significant reductions in adult counts in the small intestine compared to infected control G1b ( $P < 0.001$ ). As well, there were significant differences between all groups concerning the mean adult counts except between G1d and G1e, as shown in Table 2.

Regarding larval counts in muscular tissues, treatment of infected mice resulted in a significant decrease in mean numbers of encysted larvae, and the highest reduction was detected in G2e followed by G2d then by G2c. Additionally, there were significant statistical differences within the studied groups as seen in Table 3.

### Biochemical findings

#### Liver enzymes levels during the intestinal and muscular phases

A significant increase was determined in ALT and AST levels in infected control groups (G1b and G2b) when compared to corresponding non-infected control (G1a and G2a) ( $P < 0.001$ ). Liver enzymes levels significantly decreased in EA treated groups (G1c and G2c) as well as combined treatment groups (G1e and G2e) in comparison with infected control. Their levels reached near normal in Ge groups (Table 4).

#### Oxidative stress markers in intestinal and muscle tissues

*T. spiralis* infection (G1b and G2b) caused a statistically significant increase in the NO level in intestinal and muscular tissues in comparison to the normal control. All treated groups exhibited a significant decrease in NO levels in comparison with Gb groups. NO levels reached near normal in the combined treatment groups (G1e and G2e), as shown in Table 5.

**Table 2.** *T. spiralis* adult counts of different studied groups

Groups	Mean $\pm$ SD	Range	R%	F-test	P value
G1b	81.83 $\pm$ 8.33 <sup>f</sup>	72–95		372.366	<0.001**
G1c	31.00 $\pm$ 4.34 <sup>g</sup>	26–37	62%		
G1d	4.67 $\pm$ 1.63 <sup>h</sup>	3–7	94%		
G1e	0.00 $\pm$ 0.00 <sup>h</sup>	0–0	100%		

<sup>f, g, h</sup>Significant difference ( $P < 0.05$ ) between any two groups within the same column have different superscript letter. No significant difference ( $P > 0.05$ ) between groups with the same superscript.

R%: reduction percent;

\*\*highly significant difference.

**Table 3.** Larval counts per gram muscle of different studied groups

Groups	Mean $\pm$ SD	Range	R%	F-test	P value
G2b	1816.67 $\pm$ 92.45 <sup>f</sup>	1720–1940		633.67	<0.001**
G2c	796.67 $\pm$ 61.21 <sup>g</sup>	720–900	56%		
G2d	530.00 $\pm$ 70.14 <sup>h</sup>	440–620	71%		
G2e	183.33 $\pm$ 38.82 <sup>i</sup>	140–240	90%		

<sup>f, g, h, i</sup>Significant difference ( $P < 0.05$ ) between any two groups within the same column have different superscript letter. No significant difference ( $P > 0.05$ ) between groups with the same superscript.

R%: reduction percent;

\*\*highly significant difference.

**Table 4.** Serum liver enzymes levels during intestinal and muscular phases of infection

Group	ALT U/L			AST U/L		
	Mean $\pm$ SD	F-test	P-value	Mean $\pm$ SD	F-test	P-value
G1a	26.97 $\pm$ 1.83 <sup>h</sup>	93.636	<0.001**	63.70 $\pm$ 2.26 <sup>i</sup>	587.926	<0.001**
G1b	44.02 $\pm$ 2.69 <sup>f</sup>			150.75 $\pm$ 3.87 <sup>f</sup>		
G1c	36.85 $\pm$ 0.98 <sup>g</sup>			86.42 $\pm$ 4.41 <sup>h</sup>		
G1d	43.78 $\pm$ 2.62 <sup>f</sup>			105.67 $\pm$ 3.50 <sup>g</sup>		
G1e	27.48 $\pm$ 2.01 <sup>h</sup>			66.07 $\pm$ 3.66 <sup>i</sup>		
G2a	30.88 $\pm$ 2.69 <sup>h</sup>	50.112	<0.001**	72.32 $\pm$ 3.27 <sup>i</sup>	599.963	<0.001**
G2b	51.52 $\pm$ 4.16 <sup>f</sup>			166.38 $\pm$ 3.61 <sup>f</sup>		
G2c	41.18 $\pm$ 3.64 <sup>g</sup>			94.70 $\pm$ 3.05 <sup>h</sup>		
G2d	50.87 $\pm$ 3.81 <sup>f</sup>			106.83 $\pm$ 4.26 <sup>g</sup>		
G2e	32.37 $\pm$ 2.28 <sup>h</sup>			75.55 $\pm$ 4.61 <sup>i</sup>		

<sup>f, g, h, i</sup>Significant difference ( $P < 0.05$ ) between any two groups within the same column have different superscript letter. No significant difference ( $P > 0.05$ ) between groups with the same superscript.

\*\*Highly significant difference.

On the other hand, catalase enzyme activity significantly decreased in infected control groups (G1b and G2b) when compared to normal controls ( $P < 0.001$ ). Treatments induced an elevation of catalase enzyme activity, and the highest activity was induced by the combined treatment (Table 5).

**IL-6 and IL-10 gene expression in intestinal and muscle tissues** IL-6 gene expression in infected control groups (G1b and G2b) significantly increased in relation to all other groups. There was a significant decrease in all treated groups compared to Gb groups. Combination therapy induced the maximum reduction of IL-6 gene expression in tissues (Table 6).

Regarding IL-10 expression, there was a significant increase in its relative expression level in infected control (G1b and G2b) when compared to negative controls, with no significant difference with albendazole-treated groups (G1d and G2d). Additionally, there was

a significant increase in IL-10 expression level in EA groups (G1c and G2c) as well as combined treatment groups (G1e and G2e) in comparison with other studied groups (Table 6).

### Histopathological results

Intestinal sections from infected control G1b showed sections of *T. spiralis* adult worms, distorted villous pattern, and marked inflammatory infiltration of intestinal villi and crypts. G1c presented regenerating villi with moderate infiltration by mononuclear inflammatory cells. While G1d presented an improved intestinal architecture with normal crypts and mild villous inflammatory infiltrate. G1e showed the greatest improvement of intestinal tissues with nearly normal villous and crypt patterns with the absence of *T. spiralis* worms (Fig. 1).

Muscular pathological changes in infected control G2b showed many intact cysts and intense inflammation around encysted larvae with degenerative muscular changes. In comparison, G2c showed a reduction in the number of encysted larvae and inflammatory infiltration. G2d revealed degenerated cysts and fewer intact encysted larvae with moderate inflammatory cellular infiltration, whereas G2e exhibited mild inflammation and disintegrated larvae (Fig. 2).

### Discussion

Several studies have demonstrated the significance of plant polyphenols as a class of antimicrobial compounds against bacteria, viruses and parasites. EA is a natural polyphenolic agent that has potent anti-inflammatory and antioxidant activities. It has free radical scavenging activities as it can transfer the phenolic H-atom to a free radical and is capable of accepting electrons from several substrates (Ceci *et al.*, 2018; Ríos *et al.*, 2018).

In the current study, EA and its combination with albendazole significantly reduced mean counts of *T. spiralis* intestinal adults and muscular larvae, with the highest percent reduction achieved by combination therapy. Additionally, EA was more effective in the intestinal phase than in the muscular phase. In accordance, Esmat *et al.* (2021) mentioned that *Punica granatum* peel extract, which is rich in antioxidants as EA, reduced *T. spiralis* burden and inflammation and its anti-inflammatory effect was evident by the significant downregulation of CD4+ in tissues. This also was in agreement with Mohanty *et al.* (2021), who found that oral administration of EA resulted in a significant suppression of malaria parasitemia with improved survival time. Soh *et al.* (2009) also reported that the combination of EA with current antimalarial medications presented a synergistic effect. Additionally, EA exhibited inhibitory effects on the growth and multiplication of various *Babesia* species in vitro and a reduction in *B. microti* parasitemia in vivo (Beshbishy *et al.*, 2019). Moreover, EA was found to be effective against *T. cruzi* epimastigotes (Araújo *et al.*, 2023).

In the present study, trichinellosis infected mice displayed a significant elevation in ALT and AST serum levels compared to non-infected ones. These results were consistent with the findings of Basyoni & Elsabah (2013) and Nasreldin *et al.* (2022), who observed that liver damage caused by migrating larvae resulted in higher levels of liver enzymes in infected groups than normal ones. We found that albendazole induced a significant decrease in AST levels compared to the infected control, with no significant differences in ALT levels. Since AST is present in various tissues, including the liver, heart, and muscles (Center, 2007), albendazole's reduction of the parasitic burden in these tissues likely resulted in

**Table 5.** Oxidant/antioxidants in intestinal and muscle tissues homogenate

Group	Catalase U/g tissue			NO $\mu\text{mol/g}$ tissue		
	Mean $\pm$ SD	F-test	P-value	Mean $\pm$ SD	F-test	P-value
G1a	7.10 $\pm$ 0.74 <sup>f</sup>	95.124	<0.001**	74.23 $\pm$ 8.49 <sup>h</sup>	34.26	<0.001**
G1b	2.44 $\pm$ 0.39 <sup>j</sup>			108.85 $\pm$ 8.21 <sup>f</sup>		
G1c	5.70 $\pm$ 0.54 <sup>g</sup>			99.42 $\pm$ 5.57 <sup>g</sup>		
G1d	3.44 $\pm$ 0.30 <sup>h</sup>			94.87 $\pm$ 3.16 <sup>g</sup>		
G1e	6.83 $\pm$ 0.52 <sup>f</sup>			77.70 $\pm$ 2.90 <sup>h</sup>		
G2a	9.84 $\pm$ 0.53 <sup>f</sup>	521.675	<0.001**	93.10 $\pm$ 5.61 <sup>i</sup>	119.819	<0.001**
G2b	1.92 $\pm$ 0.26 <sup>j</sup>			149.13 $\pm$ 4.98 <sup>f</sup>		
G2c	5.86 $\pm$ 0.29 <sup>h</sup>			116.00 $\pm$ 5.62 <sup>g</sup>		
G2d	4.10 $\pm$ 0.14 <sup>i</sup>			109.35 $\pm$ 4.17 <sup>h</sup>		
G2e	7.38 $\pm$ 0.28 <sup>g</sup>			97.25 $\pm$ 4.26 <sup>i</sup>		

<sup>f, g, h, i</sup> and <sup>j</sup>Significant difference ( $P < 0.05$ ) between any two groups within the same column have different superscript letter. No significant difference ( $P > 0.05$ ) between groups with the same superscript.

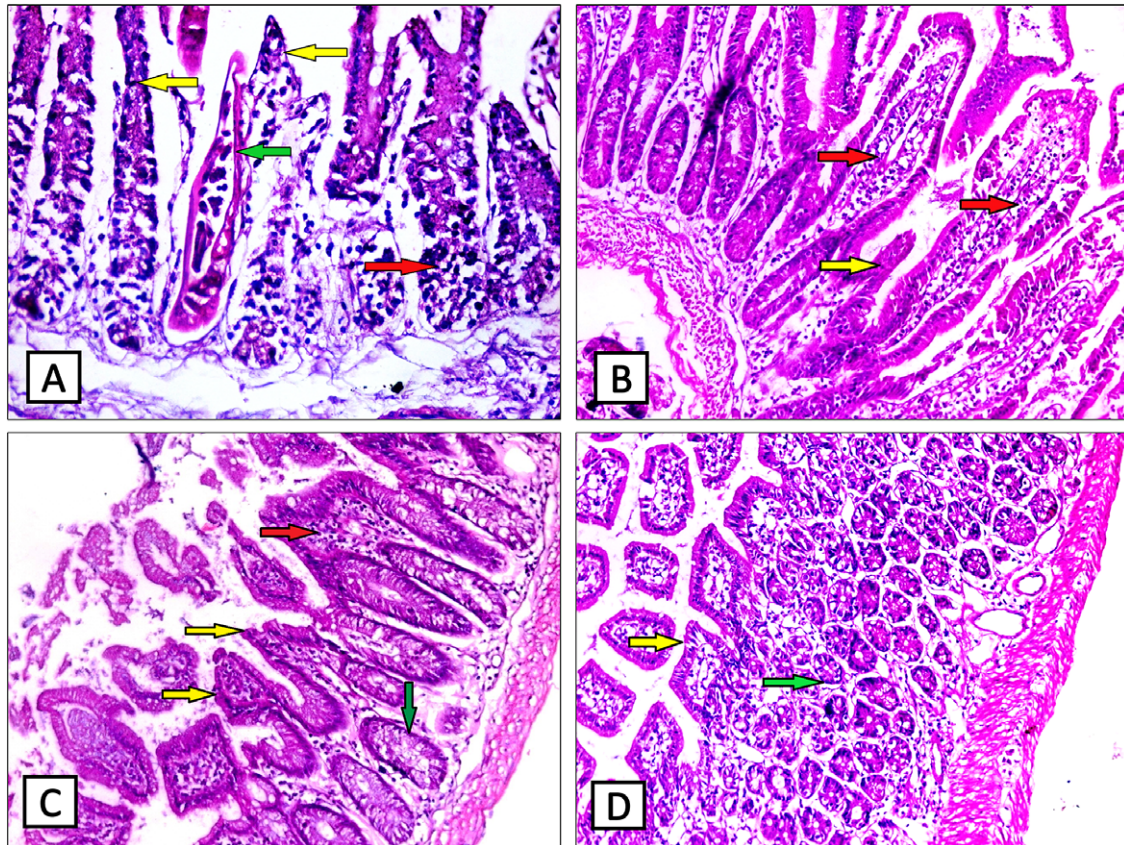
\*\*Highly significant difference.

**Table 6.** Gene expression levels of IL-6 and IL-10 in intestinal and muscle tissues homogenate

Group	IL-6 gene expression			IL-10 gene expression		
	Mean $\pm$ SD	F-test	P-value	Mean $\pm$ SD	F-test	P-value
G1a	0.98 $\pm$ 0.05 <sup>j</sup>	228.574	<0.001**	1.00 $\pm$ 0.03 <sup>i</sup>	173.414	<0.001**
G1b	1.82 $\pm$ 0.05 <sup>f</sup>			1.52 $\pm$ 0.05 <sup>h</sup>		
G1c	1.44 $\pm$ 0.06 <sup>g</sup>			1.83 $\pm$ 0.06 <sup>f</sup>		
G1d	1.31 $\pm$ 0.08 <sup>h</sup>			1.54 $\pm$ 0.05 <sup>h</sup>		
G1e	1.02 $\pm$ 0.02 <sup>i</sup>			1.68 $\pm$ 0.09 <sup>g</sup>		
G2a	1.00 $\pm$ 0.01 <sup>j</sup>	184.716	<0.001**	1.01 $\pm$ 0.01 <sup>h</sup>	150.722	<0.001**
G2b	1.44 $\pm$ 0.05 <sup>f</sup>			1.75 $\pm$ 0.07 <sup>g</sup>		
G2c	1.25 $\pm$ 0.04 <sup>g</sup>			1.90 $\pm$ 0.08 <sup>f</sup>		
G2d	1.06 $\pm$ 0.04 <sup>h</sup>			1.76 $\pm$ 0.07 <sup>g</sup>		
G2e	1.01 $\pm$ 0.02 <sup>i</sup>			1.90 $\pm$ 0.11 <sup>f</sup>		

<sup>f, g, h</sup> and <sup>i</sup>Significant difference ( $P < 0.05$ ) between any two groups within the same column have different superscript letter. No significant difference ( $P > 0.05$ ) between groups with the same superscript.

\*\*Highly significant difference.



**Figure 1.** Small intestinal sections of different groups (H&E  $\times 200$ ): (A) G1b showing *T. spiralis* adult worms (green arrow), distorted villous pattern (yellow arrows), and marked inflammatory infiltration (red arrow). (B) G1c showing regenerating villi (yellow arrow) with moderate mononuclear inflammatory infiltration (red arrows). (C) G1d showing villous regeneration (yellow arrows), normal crypts (green arrow) with mild villous inflammation (red arrow). (D) G1e showing nearly normal intestinal architecture with normal crypts (green arrow) and villi (yellow arrow).

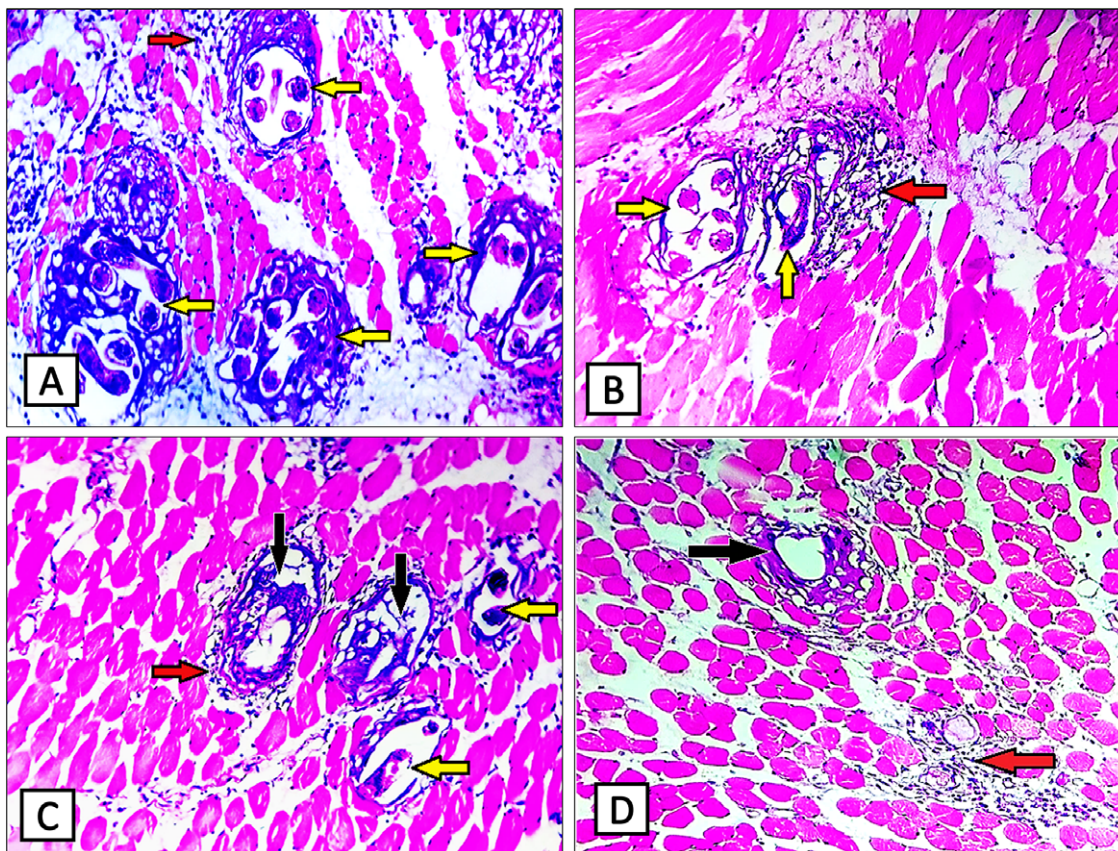
less tissue damage, leading to a subsequent decrease in AST levels. Similar results were also obtained by Nasreldin *et al.* (2022). This also aligned with Musa *et al.* (2011), who observed a notable decrease in serum AST levels following albendazole treatment of *Toxocara canis* infection. EA as well as combination therapy enhanced liver functions by decreasing both ALT and AST levels. This decrease may be the result of the antioxidant properties of EA, which improve hepatic oxidative stress by raising antioxidant capacity. These findings concurred with those of Widyawati *et al.* (2023), who reported that EA therapy improved hepatic functions.

The present study revealed that trichinellosis altered the oxidative status as the infected control groups showed higher NO levels and lower catalase enzyme activity in the intestinal and muscular tissues compared to the non-infected controls. Zhou *et al.* (2015) found that the generation of NO during trichinellosis was a significant mediator of enteropathy because of the infection and may be a therapeutic target. We found that treatments resulted in a significant decline in NO levels and an elevation of catalase activity, and combination therapy induced the greatest improvement during both phases. Ateşşahin *et al.* (2006) reported that EA improved antioxidant activities as catalase and glutathione peroxidase enzymes. El-Shitany *et al.* (2014) also reported that EA induced protection against oxidative stress by decreasing NO, cyclooxygenase-2, and malondialdehyde expression and stimulating reduced glutathione production. Similarly, Mohanty *et al.* (2021) found that EA therapy could protect from oxidative stress during *Plasmodium* infection. Albendazole was also found to

improve the oxidative stress in *T. spiralis*-infected mice as it decreased inducible nitric oxide synthase and NO levels (Abdeltawab *et al.*, 2022), with better results when combined with antioxidants (Albogami, 2023).

In addition, we detected high expression levels of the pro-inflammatory cytokine IL-6 in intestinal and muscle tissue homogenates in infected controls, which was consistent with Munoz-Canoves *et al.* (2013), and Park *et al.* (2018). Additionally, we detected a significant decrease in IL-6 in the EA and albendazole-treated groups compared to infected control, with levels returning to near normal by the combined therapy. These findings support the anti-inflammatory properties of EA. Umesalma and Sudhandiran (2010) detected negligible IL-6 expression in rats receiving EA, indicating that EA modulates inflammatory processes by inhibiting nuclear factor kappa B (NF- $\kappa$ B) activity and suppressing inflammatory cytokines. This also agreed with Mohanty *et al.* (2021) who stated that EA induced a significant suppression of pro-inflammatory cytokines as tumor necrosis factor- $\alpha$  (TNF- $\alpha$ ), interleukin-1 $\beta$  (IL-1 $\beta$ ), and IL-6 in tissue homogenate of malaria-infected mice. Song *et al.* (2024) also found that EA diminished IL-6 and TNF- $\alpha$  gene expression in the jejunum.

Our results showed a significant rise in IL-10 relative expression in the intestinal and muscular tissues of infected controls when compared to normal controls. Ding *et al.* (2017) detected that T helper 2 cytokines levels, including IL-4, IL-5, IL-10, and transforming growth factor- $\beta$ , were increased in the small intestinal tissues of *T. spiralis*-infected animals. According to Park *et al.*



**Figure 2.** Skeletal muscular sections of different groups (H&E ×200). (A) G2b showing disintegrated muscle tissue by many intact cysts (yellow arrows) and intense inflammation (red arrow). (B) G2c showed a reduction in the number of encysted larvae (yellow arrows) and mononuclear inflammatory infiltration (red arrow). (C) G2d showing degenerated cysts (black arrows) and fewer intact encysted larvae (yellow arrows) with inflammatory cellular infiltrate (red arrow). (D) G2e showing a disintegrated cyst (black arrow) with few inflammatory cells (red arrow).

(2018), although IL-10 rose steadily and peaked at 42 days following infection, muscular inflammation started to decline at day 42. These results imply that IL-10 expression may affect the muscular anti-inflammation produced by trichinellosis. Additionally, we demonstrated that EA and combination therapy resulted in a significant elevation of IL-10 expression in comparison with other studied groups. Our results agreed with Favarin *et al.* (2013), who found that EA treatment of acute lung injury increased IL-10 anti-inflammatory concentration in the bronchoalveolar lavage, indicating that EA can be used as an alternative therapy for inflammation control with less side effects than corticosteroids. Similarly, El-Shitany *et al.* (2014) stated that EA protects against inflammation by reducing NO, IL-1 $\beta$ , TNF- $\alpha$ , and NF- $\kappa$ B expression and enhancing IL-10 production.

Concerning histopathological examination of intestinal tissue sections, infected control revealed abnormal intestinal villi with marked inflammatory infiltration. This is mostly because of excretory-secretory proteins produced by adult worms that enable intestinal penetration (Khan, 2008). These findings were in accordance with those of Elmehy *et al.* (2021) and Salama *et al.* (2022). Improvement in pathological alteration was noticed in all treated groups. EA therapy resulted in the regeneration of villi with fewer inflammatory infiltrations, and combination therapy induced the most pronounced improvement. EA was found to diminish the severity and extension of the intestinal damage and inflammation in animal models of colitis (Rosillo *et al.*, 2011; Marín *et al.*, 2013). Khedr *et al.* (2024) also

informed that combining albendazole with curcumin displayed a significant potentiation against trichinellosis induced pathological changes better than albendazole alone. Concerning the muscular tissue examination of infected controls, there were many encysted larvae with intense inflammation and muscular degeneration. This was in agreement with Salama *et al.* (2022) and Khedr *et al.* (2024). EA displayed a considerable decrease in encysted larvae and a reduction in inflammatory infiltration, and combination therapy presented the best improvement. According to Labrecque *et al.* (2005) and Ceci *et al.* (2018), EA has significant antiangiogenic effects as it can inhibit VEGF receptors. That can interfere with larval nourishment, subsequently decreasing the larval count and controlling trichinellosis. Furthermore, its improving effects on the oxidative status and inflammatory response can help in enhancing the pathological alterations.

In conclusion, EA can ameliorate trichinellosis pathogenesis by suppressing proinflammatory cytokine production and oxidative stress and improving pathological alterations induced by *T. spiralis* infection. It also showed promising anti-*trichinella* therapeutic effects, which were greater in the intestinal phase, with synergistic activity when combined with albendazole. These results suggested the suitability of EA as a beneficial bioflavonoid for the treatment of trichinellosis.

**Financial support.** Nil.

**Competing interest.** The authors declare no conflict of interests

## References

- Abdeltawab, MS, Abdel-Shafi, IR, Aboulhoda, BE, Wanas, H, Saad El-Din, S, Amer, SI, and Hamed, AM (2022) Investigating the effect of the nitric oxide donor L-arginine on albendazole efficacy in *Trichinella spiralis*-induced myositis and myocarditis in mice. *Parasitologists United Journal* 15 (1), 60–70. doi: 10.21608/puj.2022.119638.1153.
- Aebi, H (1984) Catalase in vitro. *Methods Enzymology* 105, 121–126. doi: 10.1016/S0076-6879(84)05016-3
- Albogami, B (2023) Ameliorative synergistic therapeutic effect of gallic acid and albendazole against *Trichinella spiralis* muscular phase infection and assessment of their effects on hepatic and cardiac tissues in male mice. *Saudi Journal of Biological Sciences* 30, 103763. doi: 10.1016/j.sjbs.2023.103763.
- Alves, MMM, Arcanjo, DDR, Figueiredo, KA, Oliveira, J SSM, Viana, FJ C, Coelho, ES, Lopes GLN, Gonçalves JCR, Carvalho ALM, Rizzo MDS, Chaves MH, Mendonça IL, and Carvalho, FA (2020) Gallic and ellagic acids are promising adjuvants to conventional amphotericin B for the treatment of cutaneous leishmaniasis. *Antimicrobial Agents and Chemotherapy* 64 (12), e00807–20. doi: 10.1128/AAC.00807-20.
- Araújo, SA, Lima, ADS, Rocha, CQD, Previtali-Silva, H, Haridoim, DJ, Taniwaki, NN, Calabrese, KDS, Almeida-Souza, F, and Abreu-Silva, AL (2023) In vitro antioxidant and antitypanosomal activities of extract and fractions of *Terminalia catappa*. *Biology (Basel)* 12(7), 895. doi: 10.3390/biology12070895.
- Atesşahin, A, Çeribasi, AO, Yuce, A, Bulmus, O, and Çikim, G (2006) Role of ellagic acid against cisplatin-induced nephrotoxicity and oxidative stress in rats. *Basic & Clinical Pharmacology & Toxicology* 100, 121–126. doi: 10.1111/j.1742-7843.2006.00015.x.
- Bai, X, Hu, X, Liu, X, Tang, B, and Liu, M (2017) Current research of Trichinellosis in China. *Frontiers in Microbiology* 8, 1472. doi: 10.3389/fmicb.2017.01472.
- Banchroft, JD, Stevens, A, and Turner, DR (1996) Theory and practice of histological techniques. 4th edn. Livingstone, New York.
- Basso, W, Marreros, N, Hofmann, L, Salvisberg, C, Lundström-Stadelmann, B, and Frey, CF (2022) Evaluation of the PrioCHECK™ *Trichinella* AAD kit to detect *Trichinella spiralis*, *T. britovi*, and *T. pseudospiralis* larvae in pork using the automated digestion method Trichomatic-35. *Parasitology International* 86, 102449. doi: 10.1016/j.parint.2021.102449.
- Basyoni, MMA, and El-Sabaa, AA (2013) Therapeutic potential of myrrh and ivermectin against experimental *Trichinella spiralis* infection in mice. *The Korean Journal of Parasitology* 51(3), 297–304. doi: 10.3347/kjp.2013.51.3.297.
- Beshbishy, AM, Batiha, GE, Yokoyama, N, and Igarashi, I (2019) Ellagic acid microspheres restrict the growth of *Babesia* and *Theileria* in vitro and *Babesia microti* in vivo. *Parasites and Vectors* 12, 269. doi: 10.1186/s13071-019-3520-x.
- Bruschi, D (2014) Trichinellosis. In: Bruschi, F (ed), *Helminth Infections and their impact on global public health*. Springer, pp. 229–273. doi: 10.1007/978-3-7091-1782-8.
- Ceci, C, Lecal, PM, Tentori, L, De Martino, MG, Miano, R, and Graziani, G (2018) Experimental evidence of the antitumor, antimetastatic and antiangiogenic activity of ellagic acid. *Nutrients* 10(11), 1756. doi: 10.3390/nu10111756.
- Center, SA (2007) Interpretation of liver enzymes. *Veterinary Clinics of North America: Small Animal Practice* 37, 297–333. doi: 10.1016/j.cvsm.2006.11.009
- Chiumiento, I, and Bruschi, F (2009) Enzymatic antioxidant systems in helminth parasites. *Parasitology Research* 105(3), 593–603. doi: 10.1007/s00436-009-1483-0.
- de la Torre-Iglesias, PM, García-Rodríguez, JJ, Torrado, G, Torrado, S, Torrado-Santiago, S, and Bolás-Fernández, F (2014) Enhanced bioavailability and anthelmintic efficacy of mebendazole in redispersible microparticles with low-substituted hydroxypropylcellulose. *Drug Design, Development and Therapy* 8, 1467–1479. doi: 10.2147/DDDT.S65561.
- Denham DA, (1965) Studies with methyridine and *Trichinella spiralis*. I. Effect upon the intestinal phase in mice. *Experimental Parasitology* 17(1), 10–14. doi: 10.1016/0014-4894(65)90003-2.
- Ding, J, Bai, X, Wang, X, Shi, H, Cai, X, Luo, X, Liu, M, and Liu, X (2017) Immune cell responses and cytokine profile in intestines of mice infected with *Trichinella spiralis*. *Frontiers Microbiology* 8, 2069. doi: 10.3389/fmicb.2017.02069.
- Dunn, IJ, and Wright, KA (1985) Cell injury caused by *Trichinella spiralis* in the mucosal epithelium of B10A mice. *The Journal of Parasitology* 71(6), 757–766.
- Elmehy, DA, Saad, MAH, Gamal, M, El Maghraby, GM, Arafa, MF, Soliman, NA, Elkhaliny, HH, and Elgendy, DI (2021) Niosomal versus nanocrystalline ivermectin against different stages of *Trichinella spiralis* infection in mice. *Parasitology Research* 120, 2641–2658. doi: 10.1007/s00436-021-07172-1.
- El-Shitany, NA, El-Bastawissy, EA, and El-desoky, K (2014) Ellagic acid protects against carrageenan-induced acute inflammation through inhibition of nuclear factor kappa B, inducible cyclooxygenase and proinflammatory cytokines and enhancement of interleukin-10 via an antioxidant mechanism. *International Immunopharmacology* 19(2), 290–299. doi: 10.1016/j.intimp.2014.02.004.
- Esmat, M, Abdel-Aal, AA, Shalaby, MA, Fahmy, MA, Badawi, MAM, Elmallawany, MA, Magdy, M, Afife, AA, and Shafi, IRA (2021) Punica granatum and amygdalin extracts plus cobalamin combined with albendazole reduce larval burden and myositis in experimental trichinosis. *Revista Brasileira de Parasitologia Veterinaria* 30(4), e012021. doi: 10.1590/S1984-29612021084.
- Evtuguin, DD, Magina, S, and Evtuguin, DV (2020). Recent advances in the production and applications of ellagic acid and its derivatives. *A review*. *Molecules* 25, 2745. doi: 10.3390/molecules25122745.
- Farid, AS, Fath, EM, Mido, S, Nonaka, N and Horii, Y. (2019): Hepatoprotective immune response during *Trichinella spiralis* infection in mice. *The Journal of Veterinary Medical Science* 81(2), 169–176. doi: 10.1292/jvms.18-0540.
- Favarin, DC, Teixeira, MM, de Andrade, EL, Alves, C, Chica JEL, Sorgi CA, Faccioli LH, and Rogerio, AP (2013) Anti-inflammatory effects of ellagic acid on acute lung injury induced by acid in mice. *Mediators of Inflammation*, 164202. doi: 10.1155/2013/164202.
- García, A, Barrera, MG, Piccirilli, G, Vasconi, MD, Ricardo, JD, Leonardi, D, Hinrichsen, LI, and Lamas, MC (2013) Novel albendazole formulations given during the intestinal phase of *Trichinella spiralis* infection reduce effectively parasitic muscle burden in mice. *Parasitology International* 62 (6), 568–570. doi: 10.1016/j.parint.2013.08.009.
- Gottstein, B, Pozio, E, and Nöckler, K (2009) Epidemiology, diagnosis, treatment, and control of trichinellosis. *Clinical Microbiology Reviews* 22(1), 127–145. doi: 10.1128/CMR.00026-08.
- Issa, RM, El-Arousy, MH, and Abd El-Aal, AA (1998) Albendazole: a study of its effect on experimental *Trichinella spiralis* infection in rats. *Egyptian Journal of Medical Sciences* 19, 281–290.
- Khalikov, SS (2021) Solid dispersions of anthelmintics and plant protection preparations. *Solids* 2(1), 60–75. doi:10.3390/solids2010003
- Khan, WI (2008) Physiological changes in the gastrointestinal tract and host protective immunity: learning from the mouse-*Trichinella spiralis* model. *Parasitology* 135(6), 671–682. doi: 10.1017/S0031182008004381.
- Khan, MA, Khan, A, Azam, M, Allemailem, KS, Alrumaihi, F, Almatroudi, AA, Alhumaydhi, F, Azam, F, Khan, SH, Zofair, SFF, Ahmad, S, and Younus H (2021) Liposomal ellagic acid alleviates cyclophosphamide-induced toxicity and eliminates the systemic *Cryptococcus neoformans* infection in leukopenic mice. *Pharmaceutics* 13, 882. doi: 10.3390/pharmaceutics13060882.
- Khedr, SI, Gomaa, MM, Mogahed, NMFH, Gamea, GA, Khodear, GAM, Sheta, E, Soliman, NA, El Saadany, AA, and Salama, AM (2024) *Trichinella spiralis*: a new parasitic target for curcumin nanoformulas in mice models. *Parasitology International* 98, 102810. doi: 10.1016/j.parint.2023.102810.
- Labrecque, L, Lamy, S, Ame'lie Chapus, A, Samira Mihoubi, S, Durocher, Y, Cass, B, Bojanowski, MW, Denis Gingras, D, and Be'liveau, R (2005) Combined inhibition of PDGF and VEGF receptors by ellagic acid, a dietary-derived phenolic compound. *Carcinogenesis* 26(4), 821–826. doi: 10.1093/carcin/bgi024.
- Marín, M, Giner R, Ríos JL, and Recio MC (2013) Intestinal anti-inflammatory activity of ellagic acid in the acute and chronic dextrane sulfate sodium

- models of mice colitis. *Journal of Ethnopharmacology*, **150**(3):925–934. doi: 10.1016/j.jep.2013.09.030.
- Mayer-Scholl, A, Pozio, E, Gayda, J, Thaben, N, Bahn, P, and Nöckler, K (2017) Magnetic stirrer method for the detection of *Trichinella* larvae in muscle samples. *Journal of Vis Exp*. **121**, 55354. doi: 10.3791/55354.
- Mohanty, S, Gupta, AC, Maurya, AK, Shanker, K, Pal, A, and Bawankule, DU (2021) Ameliorative effects of dietary ellagic acid against severe malaria pathogenesis by reducing cytokine storms and oxidative stress. *Frontiers in Pharmacology* **12**, 777400. doi: 10.3389/fphar.2021.777400.
- Montgomery, HAC and Dymock, JF (1961) The determination of nitrate in water. *Analyst* **86**, 414–416.
- Munoz-Canoves, P, Scheele, C, Pedersen, BK, and Serrano, AL (2013) Interleukin-6 myokine signaling in skeletal muscle: a double-edged sword? *FEBS Journal* **280**, 4131–4148. doi: 10.1111/febs.12338.
- Musa, D, Senocak, G, Borazan, G, Altas, M, Ozgonul, A, Sogut, O, and Güldür, ME (2011). Effects of nigella sativa and albendazole alone and in combination in *Toxocara canis* infected mice. *JPMA-Journal of the Pakistan Medical Association* **61**(9), 866–870. PMID: 22360025.
- Nada, SM, Mohammad, SM, Moad, HSF, EL-Shafey, M.A., Al-Ghandour, AMF, and Ibrahim, N (2018) Therapeutic effect of Nigella Sativa and ivermectin versus albendazole on experimental trichinellosis in mice. *Journal of the Egyptian Society of Parasitology* **48** (1), 85–92. doi: 10.21608/JESP.2018.77029
- Nasreldin, N, Swilam, S, Abd-Elrahman, SM, and Abd El-ghaffar, SK (2022) Evaluation of clinicopathological alterations in mice experimentally infected with *Trichinella spiralis* and the nematocidal effect of tannic acid and albendazole. *New Valley Veterinary Journal* **2**(1), 16–27. doi:10.21608/nv.vj.2022.141188.1005.
- Othman, AA, Abou Rayia, DM, Ashour, DS, Saied EM, Zineldeen, DH, and El-Ebiary AA (2016) Atorvastatin and metformin administration modulates experimental *Trichinella spiralis* infection. *Parasitology International* **65**, 105–12. doi: 10.1016/j.parint.2015.11.001.
- Park, M, Kang, Y, Jo, J, Baek, K, Yu, H, Choi, Y, Cha, H, and Ock, MS (2018) Effect of muscle strength by *Trichinella spiralis* infection during chronic phase. *International Journal of Medical Sciences* **15**(8), 802–807. doi: 10.7150/ijms.23497.
- Ríos, JL, Giner, RM, Marín, M, and Recio, MC (2018) A pharmacological update of ellagic acid. *Planta Medica* **84**(15), 1068–1093. doi: 10.1055/a-0633-9492.
- Rosillo, MA, Sanchez-Hidalgo, M, C'ardeno, A, and Lastra, CA (2011) Protective effect of ellagic acid, a natural polyphenolic compound, in a murine model of Crohn's disease. *Biochemical Pharmacology* **82**(7), 737–745. doi:10.1016/j.bcp.2011.06.043.
- Saad, AE, Ashour, DS, Abou Rayia, DM, and Bedeer, AE (2016) Carbonic anhydrase enzyme as a potential therapeutic target for experimental trichinellosis. *Parasitol Res* **115**(6), 2331–2339. doi: 10.1007/s00436-016-4982-9.
- Salama, MA, Mostafa, NE, Abd El-Aal NF, Moawad, HS, Hammad SK, Adel R, and Mostafa, E (2022) Efficacy of Zingiber officinale and Cinnamomum zeylanicum extracts against experimental *Journal of Parasitic Disease* **46**(1), 24–36. doi: 10.1007/s12639-021-01412-y.
- Schmittgen, TD, and Livak, KJ (2008) Analyzing real-time PCR data by the comparative CT method. *Nature Protocols* **3**(6), 1101–1108. doi: 10.1038/nprot.2008.73.
- Shakeri, A, Zirak, MR, and Sahebkar, A (2018). Ellagic acid: a logical lead for drug development? *Current Pharmaceutical Design* **24**, 106–122. doi: 10.2174/1381612823666171115094557
- Soh, PN, Witkowski, B, Olganier, D, Nicolau, ML, Garcia-Alvarez, MC, Berry, A, and Benoit-Vical, F (2009) In vitro and in vivo properties of ellagic acid in malaria treatment. *Antimicrobial Agents and Chemotherapy* **53**, 1100–1106. doi: 10.1128/AAC.01175-08.
- Soliman, N, Shafik, N, Shoheib, Z, and Ashour, D (2013) Expression of some pro-inflammatory cytokines and inflammatory mediators in experimental model of *Trichinella Spiralis*. *Bulletin of Egyptian Society for Physiological Sciences* **33**(2), 37–60. doi: 10.21608/BESPS.2013.35220.
- Song, z, Deng, C, Chen Q, Zhao, S, Li, P, Wu, T, Hou, Y, and Yi, D (2024) Protective effects and mechanisms of ellagic acid on intestinal injury in piglets infected with porcine epidemic diarrhea virus. *Frontiers in Immunology* **15**, 1323866. doi: 10.3389/fimmu.2024.1323866.
- Umehsalma, S, and Sudhandiran, G (2010) Differential inhibitory effects of the polyphenol ellagic acid on inflammatory mediators NF- $\kappa$ B, iNOS, COX-2, TNF- $\alpha$ , and IL-6 in 1,2-Dimethylhydrazine-induced rat colon carcinogenesis. *Basic & Clinical Pharmacology & Toxicology* **107**, 650–655. doi: 10.1111/j.1742-7843.2010.00565.x.
- Vattem, DA, Ghaedian, R, and Shetty, K (2005) Enhancing health benefits of berries through phenolic antioxidant enrichment: focus on cranberry. *Asia Pacific Journal of Clinical Nutrition* **14**, 120–130. PMID: 15927928.
- Widyawati R, Yuniarti WM, and Lukiswanto BS (2023). Ellagic acid from whole pomegranate fruit reduces liver injury in a rat model of hepatic cholestasis. *Open Veterinary Journal* **13**(4), 466–472. doi: 10.5455/OVJ.2023.v13.i4.8.
- World Health Organization (WHO) (2021) Foodborne parasitic infections: Trichinellosis (trichinosis). Available at <https://www.who.int/publications/item/WHO-UCN-NTD-VVE-2021.7> (accessed on 16 September 2024).
- Xu, F, Hou, B, Zhu, X, Liu, Y, Shi, X, Li, S, Li, Z, Cai, W, Zhou, Y, and Qui, L (2019) Vaccaria n-butanol extract lower the production of proinflammatory cytokines and the infection risk of *T. spiralis* in vivo. *Acta Parasitologica* **64** (3), 520–527. doi: 10.2478/s11686-019-00064-6.
- Xu, J, Bai, X, Wang, LB, Shi, HN, Van Der Giessen, JWB, Boireau, P, Liu, MY, and Liu, XL (2017) Immune responses in mice vaccinated with a DNA vaccine expressing serine protease-like protein from the new-born larval stage of *Trichinella spiralis*. *Parasitology* **144**, 712–719. doi: 10.1017/S0031182016002493.
- Zhou, X, Dong, L, Yang, B, He, Z, Chen, Y, Deng, T, and Lan, C (2015) Preinduction of heat shock protein 70 protects mice against post-infection irritable bowel syndrome via NF- $\kappa$ B and NOS/NO signaling pathways. *Amino Acids* **47**(12), 2635–2645. doi: 10.1007/s00726-015-2056-4.