

Neuroimaging Highlight

Glomus Coccygeum Masquerading as Chordoma

Bryan J. Neth¹ , Hamed R. Youshanlouei¹, Andrew L. Folpe², Michelle J. Clarke³ and Ugur Sener^{1,4} 

¹Department of Neurology, Mayo Clinic, Rochester, MN, USA, ²Department of Pathology, Mayo Clinic, Rochester, MN, USA, ³Department of Neurosurgery, Mayo Clinic, Rochester, MN, USA and ⁴Department of Medical Oncology, Mayo Clinic, Rochester, MN, USA

Keywords: Neuroimaging; magnetic resonance imaging; glomus coccygeum; chordoma

(Received 23 June 2023; final revisions submitted 13 July 2023; date of acceptance 4 August 2023; First Published online 14 August 2023)

A 73-year-old male presented with progressive lumbosacral pain near the coccyx exacerbated when sitting and worse upon awakening. He additionally had a change in the frequency and characteristics of bowel movements without change in urinary function. His neurologic examination was normal except for reduced patellar and Achilles reflexes. Motor and sensory examinations of the lower extremities were normal. A pelvis magnetic resonance imaging (MRI) (Fig. 1) showed an enhancing, T2 hyperintense mass at the distal tip of the coccyx, measuring $1.8 \times 1.4 \times 2.4$ cm. This lesion was not visible on CT imaging (Fig. 1) of the pelvis obtained 13 years prior but noted on repeat CT pelvis obtained 15 months prior to MRI for reassessment of surgical changes from an unrelated umbilical hernia repair. The most likely clinical and radiographic concern preoperatively was for chordoma. Due to persistent pain localized to the location of the coccyx lesion, the patient underwent gross total resection via en bloc approach. Histopathology (Fig. 2) was consistent with glomus coccygeum without morphologic features of malignancy in glomus tumor (e.g., high nuclear grade and elevated mitotic activity). He clinically improved postoperatively with minimal pain/discomfort, without new motor symptoms. There was no residual tumor on three-month postoperative MRI. No adjuvant therapy was recommended.

We report on glomus coccygeum, which is an uncommon, nonpathologic entity. Glomera can be found in various locations throughout the body. One such location is the lesser-known glomus coccygeum, which is a glomus body located just ventral to the tip of the coccyx.¹ Glomus coccygeum is often found during examinations of resection specimens taken from the coccyx or peri-coccygeal soft tissue. These specimens are typically removed for various indications, such as pilonidal cysts and sinuses, fractures, or pain.^{2–4} While the function of the glomus coccygeum is not entirely understood, it has been theorized to play a role in thermal and blood flow regulation, with a secretory function.^{2,5} Glomus coccygeum is a larger glomus body, which has been reported to grow up to 4–5 mm in size.^{6,7} Glomus tumors tend to develop in regions where glomus bodies are present and may lead to pain.⁸ A large series of coccygeal specimens revealed that a glomus body was present in 13 out of 40 (35%) specimens, all of which were removed for pain.⁸ An autopsy study (n = 20) found that intracoccygeal glomus bodies were present in 6 out of the 9 pediatric specimens and in all 11 adult specimens. All of the glomus bodies were microscopic structures and did not appear to have caused bony destruction.³

This case highlights the importance of considering glomus coccygeum in the differential diagnoses of patients with coccygeal

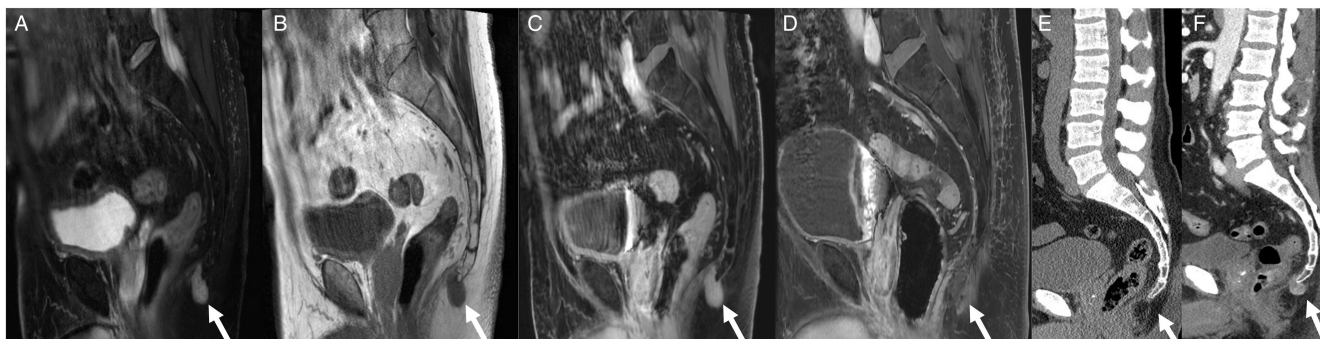


Figure 1: Magnetic resonance imaging of coccygeal tumor. **a)** T2 fat saturated image showing hyperintense $1.8 \times 1.4 \times 2.4$ cm coccygeal mass, **b)** T1 precontrast image showing hypointense mass that **c)** homogeneously enhances on post contrast images, **d)** T1 post contrast MRI revealing gross total resection of mass, **e)** noncontrast CT imaging of the pelvis 13 years prior to presentation showing no apparent lesion, **f)** that was noted on repeat CT pelvis with contrast obtained 15 months prior to MRI.

Corresponding author: U. Sener; Email: sener.ugur@mayo.edu

Cite this article: Neth BJ, Youshanlouei HR, Folpe AL, Clarke MJ, and Sener U. (2024) Glomus Coccygeum Masquerading as Chordoma. *The Canadian Journal of Neurological Sciences* 51: 569–570, <https://doi.org/10.1017/cjn.2023.273>

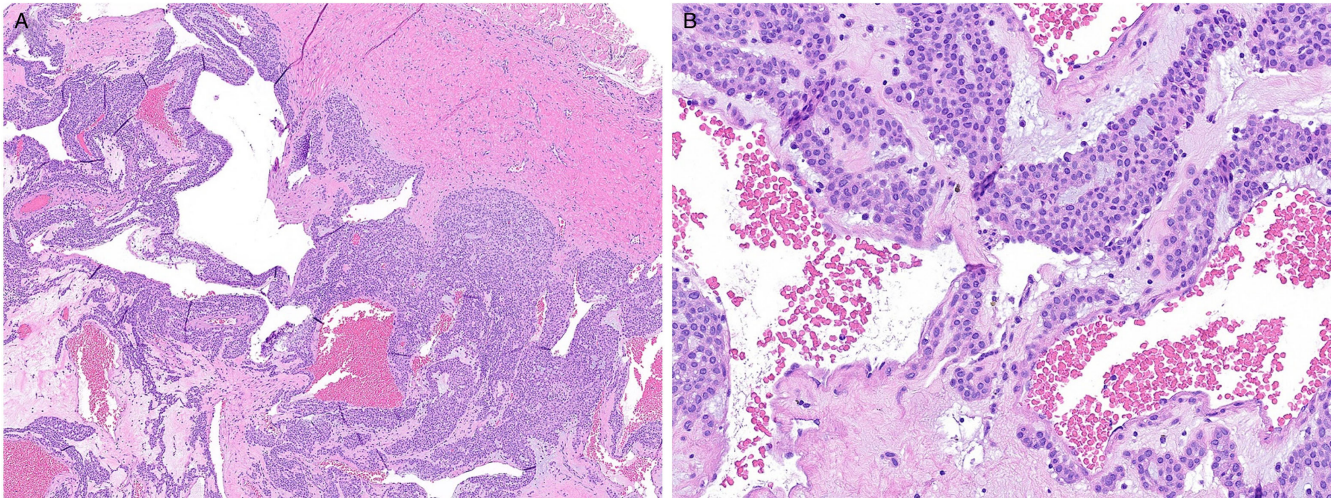


Figure 2: Histology images of glomus coccygeum. **a)** Glomus coccygeum, showing dilated vascular channels lined by round, regular glomus cells (hematoxylin and eosin, x40). **b)** Higher power view of glomus cell in a glomus coccygeum (hematoxylin and eosin, x200).

masses. For symptomatic cases, resection can be both diagnostic and therapeutic.

Competing interests. None.

Statement of authorship. BJN – wrote primary draft, data collection, obtained images; HRY – data collection, reviewed manuscript for intellectual content; ALF – provided pathology slides, reviewed manuscript for intellectual content; MJC – reviewed manuscript for intellectual content; US – project design and oversight, reviewed manuscript for intellectual content.

References

1. Santos LD, Chow C, Kennerson AR. Glomus coccygeum may mimic glomus tumour. *Pathology*. 2002;34:339–43.
2. Rahemtullah A, Szyfelbein K, Zembowicz A. Glomus coccygeum: report of a case and review of the literature. *Am J Dermatopathol*. 2005;27:497–9.
3. Albrecht S, Hicks M, Antalffy B. Intracoccygeal and pericoccygeal glomus bodies and their relationship to coccygodynia. *Surgery*. 1994; 115:1–6.
4. Albrecht S, Zbieranowski I. Incidental glomus coccygeum when a normal structure looks like a tumor. *Am J Surg Pathol*. 1990;14:922–4.
5. Shugart R. Glomus tumor. *Surg Gynecol Obstet*. 1963;117:334–40.
6. Bell R, Goodman S, Fornasier V. Coccygeal glomus tumors: a case of mistaken identity? *JBJS*. 1982;64:595–7.
7. Gatalica Z, Wang L, Lucio ET, Miettinen M. Glomus coccygeum in surgical pathology specimens: small troublemaker. *Arch Path Lab*. 1999; 123:905–8.
8. Maggiani F, Kashima T, Ostlere SJ, Athanasou NA. Immunophenotypic analysis of glomus coccygeum associated with coccygodynia. *Skelet radiol*. 2011;40:1455–9.