

SPECIAL ISSUE REVIEW

Strongyloides spp. infections of veterinary importanceSTIG M. THAMSBORG^{1*}, JENNIFER KETZIS², YOICHIRO HORII³ and JACQUELINE B. MATTHEWS⁴¹ University of Copenhagen, Veterinary Parasitology Group, 100 Dyrølægevej, DK-1870 Frederiksberg C, Denmark² Ross University School of Veterinary Medicine, P. O. Box 334, Basseterre, St. Kitts, West Indies³ University of Miyazaki, Faculty of Agriculture, Veterinary Parasitic Diseases, Gakuen-kibanadai, Nishi 1-1, Miyazaki 889-2192, Japan⁴ Moredun Research Institute, Pentlands Science Park, Edinburgh, Midlothian, EH26 0PZ, UK

(Received 11 March 2016; revised 6 May 2016; accepted 10 May 2016; first published online 4 July 2016)

SUMMARY

This paper reviews the occurrence and impact of threadworms, *Strongyloides* spp., in companion animals and large livestock, the potential zoonotic implications and future research. *Strongyloides* spp. infect a range of domestic animal species worldwide and clinical disease is most often encountered in young animals. Dogs are infected with *Strongyloides stercoralis* while cats are infected with different species according to geographical location (*Strongyloides felis*, *Strongyloides tumefaciens*, *Strongyloides planiceps* and perhaps *S. stercoralis*). In contrast to the other species, lactogenic transmission is not a primary means of infection in dogs, and *S. stercoralis* is the only species considered zoonotic. *Strongyloides papillosus* in calves has been linked to heavy fatalities under conditions of high stocking density. *Strongyloides westeri* and *Strongyloides ransomi* of horses and pigs, respectively, cause only sporadic clinical disease. In conclusion, these infections are generally of low relative importance in livestock and equines, most likely due to extensive use of macrocyclic lactone anthelmintics and/or improved hygiene. Future prevalence studies need to include molecular typing of *Strongyloides* species in relation to different hosts. More research is urgently needed on the potential zoonotic capacity of *Strongyloides* from dogs and cats based on molecular typing, information on risk factors and mapping of transmission routes.

Key words: *Strongyloides*, dogs, cats, cattle, sheep, horses, pigs, companion animals, livestock.

INTRODUCTION

Threadworms, *Strongyloides* spp. within the Rhabditoidea superfamily are small (3–8 mm), slender nematodes of the small intestine (and caeca in some species). Only the female worms are parasitic and adult worms produce eggs by the process of parthenogenesis. Larvated eggs or first stage larvae (L1), in the case of *Strongyloides stercoralis*, are excreted in the hosts' feces and undergo either rapid development through L1 and second stage larvae (L2) to infective third stage larvae (L3, homogenic cycle), or develop through the larval stages into free-living adult worms that may reproduce in the external environment to generate infective L3 (heterogenic cycle). Under certain conditions, some *Strongyloides* species may have further generations externally, but at present it is unknown whether this takes place under natural conditions (Streit, 2008). The life cycle for *Strongyloides ransomi* of pigs, as representative of the species of

veterinary importance, is summarized in Fig. 1. Percutaneous or oral (by penetration of oral mucosa) infection by L3, after the free-living phase, is followed by migration; for example via the lymphatic or haemato-tracheal routes (Mansfield *et al.* 1995), after which adult female worms develop in the proximal small intestine. The pre-patent period varies with nematode species and route of transmission. Lactogenic, mainly colostral, transmission from the dam to offspring following reactivation of inhibited somatic larvae is common in almost all species (Moncol, 1975; Shoop *et al.* 2002).

Strongyloides spp. infect a range of domestic animal species worldwide. In general, there is host specificity for each *Strongyloides* spp. However, this has been based primarily on morphology and not genetic confirmation. In studies on the prevalence and impact of infection, it is generally assumed that the species present is the one that has been previously identified as belonging to that host. Despite being capable of infecting different age groups, clinical disease is most often encountered in the young animals. In herbivores, the small, oval, thin-shelled, larvated (atypical) eggs are easily recognized when fecal material is subject to flotation, a diagnostic procedure commonly

* Corresponding author. Veterinary Parasitology Group, Department of Veterinary Disease Biology, Faculty of Health and Medical Sciences, University of Copenhagen, 100 Dyrølægevej, DK-1870 Frederiksberg C, Denmark. Phone +45 35333778. E-mail: smt@sund.ku.dk

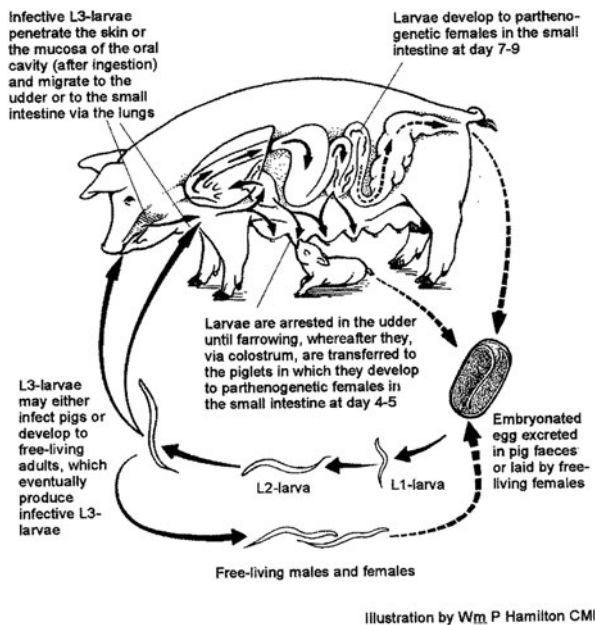


Fig. 1. The life cycle of *Strongyloides ransomi* in pigs. (Source: Food and Agriculture Organization of the United Nations, Roepstorff and Nansen (1998), Epidemiology, diagnosis and control of helminth parasites of swine. Reproduced with permission.)

performed for gastrointestinal nematodes. These infections are only sporadically associated with clinical signs in herbivores and in recent years clinical reports have been relatively few. However, the recent findings of *Strongyloides stercoralis* in dogs in some Nordic countries (Finland and Norway) (Dillard *et al.* 2007; Hoegaasen *et al.* 2012) are interesting and may perhaps represent spreading of this potential zoonotic infection. This paper reviews the occurrence and impact of *Strongyloides* spp. in companion animals and large livestock (Table 1), although we are also aware of the importance of these infections in other species, e.g. rabbits and birds. The potential zoonotic implications of these parasites and future research requirements are discussed.

CANINE AND FELINE STRONGYLOIDOSIS

Occurrence

Strongyloides stercoralis occurs worldwide in dogs and infects people, non-human primates and wild canids (Fig. 2). Cats have been infected with *S. stercoralis* experimentally, but natural infections, until recently, have only been reported with *Strongyloides tumefaciens* (North America; India), *Strongyloides planiceps* (Japan; also infecting wild canids and weasels) and *Strongyloides felis* (India; Australia). *Strongyloides* also occurs in cats in Europe and Africa, but the species has not been specified and could potentially be *S. stercoralis* (Abu-Madi *et al.* 2007). The identification of the species in dogs and cats has been based on morphology and, in studies on prevalence and

life cycles, morphology or assumptions regarding the species present in these hosts, are used.

Strongyloides stercoralis prevalence ranges from 0 to over 50% in dogs, with most studies indicating 0.2 to <5% with younger dogs more likely to be infected (Junior *et al.* 2006; Palmer *et al.* 2008; Gates and Nolan, 2009; Paulos *et al.* 2012; Riggio *et al.* 2013). Based on the few longitudinal studies available, *S. stercoralis* does not appear to be decreasing in prevalence (Asano *et al.* 2004; Itoh *et al.* 2009a, b).

Prevalence of *Strongyloides* in cats ranges from 0 to 4% (Mircean *et al.* 2010; Mohd Zain *et al.* 2013; Takeuchi-Storm *et al.* 2015). However, in Qatar and Christmas Island, higher prevalence (up to 46%) has been seen (Abu-Madi *et al.* 2007; Adams *et al.* 2008). In cases where dog and cat parasites were studied together, *Strongyloides* infections were less common in cats compared with dogs.

Prevalence of infection is influenced by the environment, age of the dog or cat and the housing situation. Prevalence, as well as the clinical significance of *Strongyloides* in neonatal dogs, is likely underestimated since standard fecal flotation methods have low sensitivity for recovery of *S. stercoralis*, *S. tumefaciens* and *S. felis* L1, which are more frequently present than larvated eggs (Bowman *et al.* 2002; Zajac and Saleh, 2013). Non-reproductive female adults can live for several months also resulting in underestimating prevalence (Mansfield *et al.* 1996).

Biology and transmission

All of the *Strongyloides* species infecting dogs and cats have the typical lifecycle with adult female worms residing in the host reproducing via parthenogenesis and male and female adults in the environment reproducing sexually. The adult females live in the mucosal epithelium and lay eggs within the crypts of the small intestine, except for *S. tumefaciens*, which is located in tumors in the mucosa of the large intestine. While eggs with L1 can be found in fresh feces, hatched L1 are more frequently seen with *S. stercoralis*, *S. tumefaciens* and *S. felis*. The eggs are oval and range from 50 to 58 μm by 30–34 μm , with *S. planiceps* being slightly larger. The L1 of *S. stercoralis* has a prominent genital primodium, a rhabditiform oesophagus and straight tail. The host, the environment and the strain determine if the L1 enter the homogonic or heterogonic route, with the homogonic route favoured at higher environmental temperatures. With the heterogonic route, there typically is only one generation of free-living adults, although more might occur with *S. planiceps*.

The primary mode of infection for *S. stercoralis* is percutaneous, with oral exposure resulting in oral mucosal penetration (Galliard, 1950, 1951a, b). Arrested larvae do not appear to serve as a primary source of transmammary infection or reinfection

Table 1. FACTS BOX: different *Strongyloides* species in domestic animals

| Parasite species | Final hosts | Comments |
|-----------------------|---|--|
| <i>S. stercoralis</i> | dogs, humans, non-human primates, wild canids, (cats) | L1 in feces, potentially zoonotic; not all species in cats are known |
| <i>S. felis</i> | cats | L1 in feces, mainly India, Australia |
| <i>S. tumefaciens</i> | cats | L1 in feces, mainly North America, India, large intestine |
| <i>S. planiceps</i> | cats, wild canids, weasels | mainly Japan, Malaysia |
| <i>S. papillosus</i> | cattle, sheep, goats, rabbits | worldwide, sudden death in calves in Japan, perhaps a separate species for cattle (<i>S. vituli</i>) |
| <i>S. westeri</i> | horses and other equids | worldwide, occasional diarrhoea when high burdens present |
| <i>S. ransomi</i> | pigs, wild boars | worldwide, low prevalence |

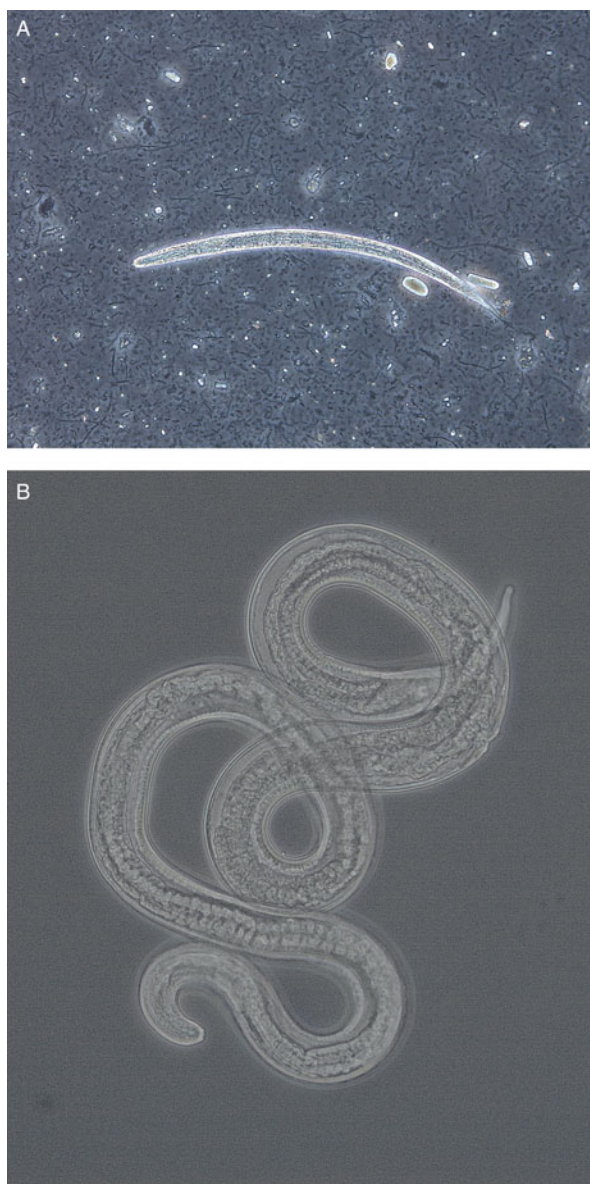


Fig. 2. (A) Larva (approximately 290 μm) and (B) adult female (1.5 mm) of *Strongyloides stercoralis* from dogs in Norway. The adult worm was recovered from a fecal smear of a puppy with severe diarrhoea. Photos kindly provided by Inger Sofie Hamnes, Norwegian Veterinary Institute.

(Mansfield and Schad, 1995; Mansfield *et al.* 1996). However, transmammmary infection can occur if the bitch is infected late in gestation or during lactation (Shoop *et al.* 2002). The migration route of the larvae during initial infection appears to be related to the strain or an adaptation of the parasite to the host (Genta, 1989). While pulmonary migration has been demonstrated with some strains, its role might be limited in dog specific strains (Faust and Kagy, 1933; Schad *et al.* 1989; Mansfield *et al.* 1995).

The larvae reach the small intestine within 4–5 days with the prepatent period ranging from 5 to 21 days. Maximum egg output occurs approximately 20 days post infection and can continue at a lower level for up to 11 weeks. It is hypothesized that the immune system of the dog inhibits egg production prior to the death of the female worms. This has been supported by studies in which exposure to corticosteroids results in recrudescence of larval shedding (Genta *et al.* 1986; Mansfield *et al.* 1996).

Autoinfection (the ability of L1 to molt to L2, then L3 and become an adult without leaving the host) does not appear to occur with the dog strain under normal conditions. If dogs are infected with a human strain, autoinfection can occur, but within a few generations, reverts to normal infections (requiring the L1 to leave the dog to continue development) (Faust and Kagy, 1933; Genta, 1989). Autoinfection leading to hyperinfection (migrating L3 throughout the body) also can occur in neonatal dogs and when dogs are exposed to steroids. Dissemination of adult worms to the trachea, lungs and other extra-intestinal sites is rare, but has been observed in animals treated with high doses of prednisolone (Genta *et al.* 1986).

Less is known about the life cycles of *S. tumefaciens*, *S. planiceps* and *S. felis*. The mode of infection for these species is believed to be percutaneous and per os. *Strongyloides tumefaciens* females reside in nodules in the large intestine and L1 are found in feces. Other aspects of the *S. tumefaciens* life cycle are unknown. *Strongyloides planiceps* infects the host percutaneously and per os, has a prepatent period of 10–11 days, resides in the small intestine

and produces partially embryonated eggs in the feces (Fukase *et al.* 1985). *Strongyloides felis* infects largely older cats and enters the host percutaneously, followed by pulmonary migration. The prepatent period ranges from 9 to 14 days and results in L1 in the feces (Speare and Tinsley, 1986, 1987).

Clinical signs and diagnosis

Most *Strongyloides* infections in dogs and cats are asymptomatic and self-limiting. In cases of high worm burdens in dogs, diarrhoea (watery and with or without mucous) and bronchopneumonia can occur (Nolan, 2001). More severe clinical signs including extensive skin lesions and bronchopneumonia, sometimes leading to death, have occurred when dogs were infected with human and non-human primate strains (Faust and Kagy, 1933). In neonatal dogs, *S. stercoralis* is a differential diagnosis for pulmonary disease and diarrhoea. Clinical signs of infection with *S. planiceps* have not been noted and are rare with *S. felis*, while *S. tumefaciens* infections result in tumour-like nodules in the large intestine and loose or diarrhetic feces.

Specific methods for recovering L1, such as the Baermann method or Zinc sulphate flotation solution, are recommended for *S. stercoralis* and *S. felis*; however, fecal flotation is effective for *S. planiceps* (Nolan, 2001; Zajac and Saleh, 2013). Differentiation of *Strongyloides* L1 from those of *Ancylostoma* spp. is sometimes required. Also, larvated *S. felis* and *Ancylostoma* spp. eggs are similar, requiring culture to differentiate. At necropsy, the various species can be distinguished by location, size, appearance of the ovaries (straight or spiralled) and the shape of the tail. However, due to size, special attention is needed if sieving is applied.

Treatment and prevention

No products are registered for the treatment of *Strongyloides* infections in dogs and cats. Treatment doses can be higher than for other gastro-intestinal nematodes, due to the location of the female worms in the mucosa and crypts. In normal infections, ivermectin (200 µg kg⁻¹ BW), albendazole (100 mg kg⁻¹ BW 2x days⁻¹ for 3 days) and fenbendazole (50 mg kg⁻¹ BW 1x day⁻¹ for 3–5 days) are expected to be efficacious in the treatment of *S. stercoralis* dogs (Nolan, 2001; Itoh *et al.* 2009b). Treatments are less efficacious against migrating *S. stercoralis* L3, but unless the infected dog is very young or has been treated with steroids, the number of migrating L3 is low. In cases of hyperinfection, fenbendazole (50 mg kg⁻¹ BW 1x day⁻¹ for 7–14 days) and ivermectin (200 µg kg⁻¹ BW 1x day⁻¹ every 4 days for 3 or 4 doses) have been demonstrated to be effective (Nolan, 2001). In cats, ivermectin (200 µg kg⁻¹ BW) has been proposed as a treatment for all species (Bowman *et al.* 2002).

Due to the wide environmental dissemination of *S. stercoralis*, prevention is challenging. Proper hygiene and sanitation in the human population and common methods such as removing dog and cat faeces from the environment and preventing free-roaming dogs could decrease infections. In kennels and breeding facilities, good hygiene and management can prevent heavy infections (Dillard *et al.* 2007).

Zoonotic aspects

A primary concern with *S. stercoralis* infections in dogs is the zoonotic potential. Dogs have been infected with *S. stercoralis* obtained from people in experimental studies and human infections have been related to dog exposure, although genetic typing has not occurred in these cases. More recently, molecular techniques have shown that there are clear differences between the strains and the existence of subspecies has been proposed (Ramachandran *et al.* 1997; Schär *et al.* 2014). The zoonotic potential of dog *S. stercoralis* is now being challenged (Takano *et al.* 2009; Schär *et al.* 2014). However, as the studies by Faust and Kagy (1933) demonstrated, *S. stercoralis* can adapt from a human to dog host, changing its virulence (autoinfection and hyperinfection capabilities) and migratory pathways. If the converse is true, with dog strains adapting to humans and increasing in virulence, then while zoonosis might be less common than previously proposed, dog infections could still pose a significant health risk to people. The zoonotic potential of cat *Strongyloides* has not been studied, but with its spread into Nordic countries and potential reports of *S. stercoralis* infections, requires research.

EQUINE STRONGYLOIDOSIS

Occurrence and impact

Strongyloides westeri is relatively common worldwide. Clinical disease is invariably only observed in young foals (i.e. animals of 2–7 weeks-old; Hiepe *et al.* 1975) and only when high levels of infection are present (Netherwood *et al.* 1996). Prevalence has been measured as high at stud farm level, but at low levels in individual horses; for example, the parasite was detected in <10% of all horses sampled in a number of studies (Mfitilodze and Hutchinson, 1989; Lyons *et al.* 1993; Gawor, 1995; Teixeira *et al.* 2014). In populations where there is a history of high use of prophylactic anthelmintic treatments such as ivermectin, prevalence at stud farm level is lower (Relf *et al.* 2013). In one study, performed where the prevalence of *S. westeri* within the same population was compared over time, prevalence was found to be greater (i.e. 30% of foals) in 2014 than in previous reports from the same area sampled during the late 1990s and early 2000s (Lyons and Tolliver,

2014). The authors of this study proposed that the relative increase may have been due to a reduced usage of ivermectin in foals over time due to concerns about resistance to this compound in the other important foal parasitic nematode, *Parascaris equorum* (Lyons and Tolliver, 2014). This theory remains to be substantiated by further evidence.

Biology and transmission

Like other species of *Strongyloides*, *S. westeri* can undergo parasitic cycles and free-living reproductive cycles in the environment, with females only in the host cycle and free-living males and females sexually reproducing outside the host. Survival of *S. westeri* worms in the environment is favoured by warm and humid conditions, which can lead to high levels of infection and clinical signs. Thus, disease is more likely to be seen in foals reared where bedding accumulates and management is poor. An important source of infection to foals is transmission of larvae within days after birth from the mare's milk. Mares are thought to harbour inhibited larvae from early life infections. These larvae reactivate around the time of parturition and travel to the mammary gland to be transmitted in the milk. There is little known about how long *S. westeri* larvae persist in the milk. In one study, in a single pony mare, larvae were found to be present in the milk on days 10, 24 and 32 days post-partum (Mirck, 1977). However, in other mares under study, larvae were not detected in milk despite the fact that their foals had patent infections between 13 and 16 days post-partum. The experimental conditions in this study precluded environmental transmission, so the infections were likely to be lactogenic and the lack of larvae detected in the mares' milk was probably due to the relatively low sensitivity of the test applied (Mirck, 1977). In the same study, 10 foals were reared artificially; these did not develop *S. westeri* infections, indicating that vertical transmission via the placenta does not occur. In foals, the pre-patent period has been measured as 10–14 days, with the length of patency ranging from 43 to 83 days (Mirck and Franken, 1978). By the time foals are 4–6 months old, egg shedding ceases (Hiepe *et al.* 1975).

Clinical signs and diagnosis

As indicated above, *S. westeri* only causes clinical signs in young foals when present in high numbers. Signs in foals up to a few weeks-old include acute diarrhoea, weakness and weight loss as well as respiratory signs. One study demonstrated that the association between *S. westeri* and clinical signs of diarrhoea was dependent on the numbers of eggs shed, with a positive association only observed when more than 2000 eggs per gram (EPG) of feces were detected (Netherwood *et al.* 1996). Infection with large numbers of larvae leads to inflammation, oedema and erosion of the

small intestinal epithelium (Brown *et al.* 1997). This can affect absorption and digestion and result in diarrhoea. It is important to appreciate that *S. westeri* is one of several pathogens that are associated with diarrhoea in foals. Other pathogens include bacteria such as *Salmonella* and *Clostridium* spp., and viruses such as rotavirus, and, indeed, these are more likely causes of diarrhoea in young foals than *S. westeri* infections (Netherwood *et al.* 1996). When foals are infected via the environment, the larvae penetrate the skin or are ingested, and the larvae then undergo a migratory life cycle, via the circulatory system and lungs. As larvae migrate through the lungs, they cause inflammation and haemorrhage, which can lead to respiratory signs in heavy infections. Clinical signs are much less common in older foals. Older foals are more likely to display clinical signs of infection with the intestinal ascarid nematode, *P. equorum*.

Diagnosis is made on the basis of the detection of large numbers of the characteristic larvated eggs or hatched larvae in faeces; however, it should be noted that high numbers of eggs and larvae can be found in the faeces of foals exhibiting no clinical signs of strongyloidosis.

Treatment and prevention

Control of this parasite on stud farms where there has been a clinical problem requires both chemical and environmental interventions. Treatment of infected foals with anthelmintics will lower environmental contamination, but it is also important to remove fecal-contaminated bedding and to provide dry stabling to limit amplification of free-living generations. The parasites are susceptible to macrocyclic lactones, modern benzimidazoles and pyrantel (Ludwig *et al.* 1983; Felippelli *et al.* 2015). As mares can act as a reservoir of infection, periparturient anthelmintic treatments can be administered in an attempt to reduce transmammary transmission. Transmission of larvae to foals via milk may be prevented by the treatment of mares with ivermectin within 24 h of foaling (Di Pietro, 1989). Anthelmintic resistance has not been reported in *S. westeri* thus far, but it is important to balance chemotherapeutic administration of anthelmintics to control these worms against the risk of increasing selection pressure in other equine parasitic nematode species for which drug resistance is an issue.

RUMINANT STRONGYLOIDOSIS

Occurrence

Strongyloides papillosus, a universally common intestinal nematode of cattle and small ruminants, generally parasitizes the small intestine as female adult stages and can cause diarrhoea and malnutrition, especially in young animals. The prevalence of

S. papillosus has been reported to vary between age groups, management systems, areas and climates; for example, the parasite was detected in 58% of lambs in northern Tunisia during spring (Akkari *et al.* 2012), in 18% of sheep on pasture in southern Poland during summer (Balicka-Ramis *et al.* 2013) and in only 3% of sheep in winter season in northern Egypt, while nil were infected in the other seasons in the same area (Khalafalla *et al.* 2011). In calves, *S. papillosus* was detected in 10–53% of 1-month old of beef calves during housing in central Germany, however, during the grazing season the prevalence decreased to 6% (Jäger *et al.* 2005). In Costa Rica, 4–20% of 4 month-old dairy calves were found infected by coproscopy (Jiménez *et al.* 2010). High levels of infections in calves have been seen in the wet/humid summer season in southern Japan (Taira and Ura, 1991).

Clinical impact

Infections in small ruminants are commonly associated with maceration of pedal skin in young animals, and more than 50 000 EPG of feces have been observed in perinatal lambs grazing wet (waterlogged) areas without clinical signs. The penetration of the interdigital and/or coronary area may predispose to foot-rot (Deplazes *et al.* 2013). An experimental infection with *S. papillosus* in goats showed clinical signs, including transient diarrhoea, elongated fecal pellets terminally, dehydration, anorexia and anaemia (Pienaar *et al.* 1999). The pre-patent period is similar to that in cattle infections: 8–14 days. Heavy infection causes serious strongyloidosis (Vegors, 1954; Davis *et al.* 1960) and, in the 1980s, more than 150 calves died suddenly in southern Japan in association with *S. papillosus* infection (Taira and Ura, 1991). These calves died within a few minutes of collapsing, without any significant preceding clinical signs. The animals had a large number of *S. papillosus* eggs and numerous adult worms in the intestine at post mortem. The deaths were attributed to hyperinfection by L3 due to rearing of similar-aged calves on sawdust bedding at high stocking density (Taira and Ura, 1991). Sudden death of calves was subsequently confirmed by experimental infection with a large amount of *S. papillosus* L3 (Taira *et al.* 1992). Heavily infected calves showed accelerated respiration as the first clinical sign shortly before death, but body temperature remained almost normal and no consistent hematological, biochemical or histological changes were identified (Ura *et al.* 1992; Nakanishi *et al.* 1993). Vocal noises and general spasms were observed several times during the course of death. All animals died within 3–4 minutes from the first respiratory signs (Ura *et al.* 1992). When electrocardiographic and pneumographic examinations were employed on infected calves, various patterns of tachy- and

brady-arrhythmia were observed 1–2 days before death while abnormal pneumograms were not observed (Tsuji *et al.* 1992; Ura *et al.* 1993). Although Taira *et al.* intensively investigated sudden death in cattle due to *S. papillosus*, the mechanisms underlying cardiac sudden death have yet to be definitively confirmed. The only way to predict an occurrence of sudden death in calves is by performing fecal egg counts. Calves with high counts (EPG > 10 000) should be treated with effective anthelmintics to avoid disease and build-up of infections in the group.

Pathogenesis

Rabbits are also susceptible to *S. papillosus*, but experimental rodents are not (Buzubik 1965; Neilson and Ngheim 1974; Nwaorgu and Connan, 1980; Taira *et al.* 1991). Heavily infected rabbits often die due to significant wasting, characterized by anaemia, severe anorexia and weight loss, but no cardiac abnormalities have been seen (Nakamura *et al.* 1994). In addition, gastrointestinal motor disturbances were identified as underlying the manifestations and death in infected animals (Kobayashi and Horii, 2008). However, the mechanisms for death resulting from *S. papillosus* infection have yet to be identified in either ruminants or rabbits. Despite the importance of these symptoms, little is known about the mechanisms causing the gastrointestinal manifestations of this infection. Enteric parasitic infections are known to evoke changes in intestinal motility (Gregory *et al.* 1985; Crosthwaite *et al.* 1990; Marzio *et al.* 1990; Palmer *et al.* 1998). Although various reports have described the effects of parasitic infection on intestinal transit, the mechanisms inducing gastrointestinal motor disturbance are poorly understood. In a study by Kobayashi *et al.* (2009), adult *S. papillosus* were surgically implanted into the duodenum and established in Mongolian gerbils. These worms persisted in the small intestine for at least 4 days after implantation. Following decreased fecal output, however, increased death rate and decreased survival time were observed in the gerbils. The increase in death rate and decrease in survival time correlated with increases in the number of implanted adult worms. Animals were then intraperitoneally inoculated with extracts from homogenized adult worms of *S. papillosus*, and the effects on gastrointestinal motility assessed by contrast radiography after oral administration of barium sulphate. Paralytic ileus was observed, and these symptoms intensified with increasing inoculation of adult worm extract, but were completely lost with heat treatment of the extract. Such results suggest that paralytic ileus underlies the subsequent death observed in Mongolian gerbils after implantation of adult *S. papillosus*. However, the effector molecules causing gastrointestinal motor

disturbance in *Strongyloides* infections remain unknown. Besides the sudden cardiac death in calves and lambs, *S. papillosus* infection in sheep may cause oxidative/nitrosative stress, depending on infection intensity, and the condition is relieved by treatment with albendazole (Dimitrijevic *et al.* 2012).

Treatment and prevention

Strongyloides papillosus-related early damage can be treated and/or completely prevented by use of effective anthelmintics. Macrocytic lactones such as ivermectin, doramectin and moxidectin are the most popular drugs to treat *S. papillosus* (Tassi *et al.* 1990; Marley *et al.* 1999; Ranjan and Delay, 2004). Albendazole is also effective (Dimitrijevic *et al.* 2012). Again, it is important to emphasize the risk of selecting for anthelmintic resistance in other worm species when unnecessary treatments are applied; treatments should be applied on an evidence basis. As general preventive measures, the first is to avoid mass rearing of naïve calves in a pen or mass deworming before grouping, and the second is keeping bedding dry by using a roof fan, avoiding saw dust, or frequent renewal of litter.

The relationship between *Strongyloides spp.* in cattle and in small ruminants

To date, most veterinary parasitologists consider that all *Strongyloides* of farm ruminants to belong to the same species, *S. papillosus*. Eberhardt *et al.* (2008) reported that, in southern Germany, the predominant *Strongyloides* species found in cattle and in sheep belonged to separate genetically isolated populations. They prepared L3 by culturing collected feces from each farm and single worms were used for polymerase chain reaction (PCR) for sequencing portions of the small subunit (SSU) sequence of 18S rDNA. While mixed haplotype infections were found in cattle, one form clearly dominated. This heterogeneity was not found in the sheep population, indicating that the two forms have different host preferences. By comparing with molecular phylogenetic analysis of the human parasite, *S. stercoralis*, and the laboratory model species, *S. ratti*, these authors concluded that *Strongyloides* from sheep and the predominant *Strongyloides* from cattle should be considered separate species, suggesting the name *S. papillosus* for *Strongyloides* in sheep and the name *S. vituli* for the predominant *Strongyloides* in cattle. However, supporting studies by others have yet to be published.

PORCINE STRONGYLOIDOSIS

Occurrence and impact

Strongyloides ransomi (s. *S. suis*) is found in wild boars (Barutzki *et al.* 1992) and domestic pigs

throughout the world, usually at low levels. The worms are found predominantly in young piglets, as adult worms, while sows host somatic larval stages. The incidence of infection is most likely related to management procedures, but a large epidemiological study in the Nordic countries provided no conclusive information on the distribution of this parasite in different production systems due to the sporadic occurrence and low prevalence (as measured by coproscopy) in all age groups (<2%) (Roepstorff *et al.* 1998). Similar prevalence levels (3.3%) were observed in fattening pigs on a Polish commercial farm (Knecht *et al.* 2011). Some studies indicate that small, traditional herds and low levels of hygiene may predispose to infection (Raynaud *et al.* 1975; Roepstorff, 1991), but prevalence levels on these farms may in fact not be related to hygiene *per se* but rather, a high rate vertical transmission as infections occur in young piglets (Raynaud *et al.* 1975). In these studies, whole litters were infected with mean fecal egg counts of 5500 EPG (range 300–9500 EPG) at 5–8 weeks of age. Infections occur in both indoor and outdoor reared pigs. Cross-sectional studies in tropical production systems with variable outdoor access have found a prevalence of 3.4% by necropsy (Nganga *et al.* 2008) or 1.1% by fecal examination during dry season (Kabululu *et al.* 2015). Burdens varied from 1 to 449 worms in the former study, performed during a relatively dry period. Although organic farms in many cases experience more severe helminth infections, a study on nine pig farms with an organic farming history of up to 8 years, found no *S. ransomi* by repeated fecal examination (Carstensen *et al.* 2002). A range of experimental infection studies, performed in the 1960–1970s in the USA, showed a substantial impact of this parasite on weight gains and feed efficiency in weaners and fatteners, depending on infection levels, and even lethality at high infection levels (up to 30%)(reviewed by Stewart and Hale, 1988). Infection levels ranged from 5000 to 20 000 L3 kg⁻¹ body weight, and it is difficult to judge how relevant these levels are in the context of field infections at the current time. What these experimental studies do demonstrate though is that, if *S. ransomi* is present in sufficient numbers, subclinical and clinical disease can occur and, indeed, this has been observed in the field in a relatively recent outbreak on a Danish commercial pig farm (Roepstorff *et al.* 2011). On the flip side, many researchers do not consider *S. ransomi* as a major pathogen in piglets anymore (e.g. Joachim and Dausgchies, 2000) as infections are becoming relatively rare. Intensive indoor rearing and associated high levels of hygiene, and the widespread use of macrocyclic lactones for control of e.g. sarcoptic mange, may be reasons for this low disease incidence.

Biology and transmission

Pigs can be infected orally or percutaneously by free-living infective L3. Oral infection is expected to take place through the oral mucosa. Like other *Strongyloides* spp., the larval stages undergo migration through the lungs to become egg-laying females in the small intestine. A prominent feature is the very efficient vertical transfer of infections via colostrum to suckling piglets (Moncol and Batte, 1966; Stewart *et al.* 1976), while prenatal infection is very unusual (Enigk *et al.* 1974b). Larvae were usually shed in the colostrum within 24 h post-partum, but were also found for up to 20 days (Stewart *et al.* 1976). Reactivation of hypobiotic somatic stages in sows is most likely related to acquired immunity. Reactivation of larvae deposited in the fat tissues around the mammary gland takes place during pregnancy but the exact mechanism, i.e. the triggering stimulus, is not known. Evidence indicates that a sow may transmit L3 for 4–5 litters without reinfection needing to take place (Stewart *et al.* 1976). Colostral infections are followed by a brief pre-patent period (4 days) as no somatic migration takes place in the infected piglets (Moncol and Batte, 1966; Enigk *et al.* 1974b), and nematode egg excretion is observed for a relatively short period as the piglets rapidly acquire protective immunity (Murrell, 1981). If other routes of infection take place, the pre-patent period has been reported as up to 9 days (Deplazes *et al.* 2013).

Clinical signs, pathogenesis and diagnosis

Clinical symptoms are mainly observed in the neonatal period up to 2 weeks of age. Clinical signs in acute disease include anorexia, anaemia, diarrhoea, growth retardation or weight loss and, in some cases, sudden death. Severe experimental infections show that profuse diarrhoea can be observed 8–10 days post infection (Dey-Hazra *et al.* 1979). Like many other gastrointestinal nematode infections, infection is accompanied by increased intestinal losses of plasma proteins and reduced amino acid absorption, reflected in hypoalbuminaemia and, occasionally, hypoproteinaemia (Enigk and Dey-Hazra, 1975).

Infection is diagnosed in pigs by the detection of larvated eggs in feces by flotation; for example, by the modified McMaster method. Fecal egg counts are generally higher in young pigs (thousands EPG) compared with older stock, e.g. gilts and sows have counts of 100–300 EPG (Moncol, 1975). Egg size is 20–35 × 40–55 µm and should be differentiated from *Metastrongylus* (lung worm) eggs, which are slightly larger (45–50 × 55–60 µm) and generally have a thicker shell (Deplazes *et al.* 2013). The eggs hatch within 8–12 h at room temperature. Note that false negative results can occur if fecal samples are kept at room temperature too long without refrigeration.

False positives also have to be considered if eggs are misidentified, e.g. eggs of free-living nematodes. Studies based on fecal samples picked up from the ground/pen floor need to be considered cautiously.

Treatment and prevention

Intestinal stages are sensitive to modern benzimidazoles, levamisole and macrocyclic lactones (Deplazes *et al.* 2013). The somatic larval stages are susceptible to macrocyclic lactones such as ivermectin or repeated administrations of benzimidazoles, while levamisole is less efficacious (Enigk *et al.* 1974a). Treatment of infected sows in late gestation with in-feed ivermectin (100 µg kg⁻¹ BWT for 7 days) has been demonstrated to result in almost complete elimination of L3 in the milk post-partum with no measurable transfer to piglets (Barth *et al.* 1996; Drag *et al.* 1998). Single subcutaneous injection of 300 µg kg⁻¹ ivermectin had a similar effect (Barth and Preston, 1985). The high efficacy and persistence of ivermectin and other macrocyclic lactones, for example, doramectin (Logan *et al.* 1996) and abamectin (Lopes *et al.* 2014), is probably the main reason for relatively few clinical cases and less importance of this infection in modern pig production systems, as milk-borne infections are effectively prevented by the administration of such compounds to pregnant sows. Alternatively, or additionally, one or more strategic treatments of the piglets can be considered. Other preventive measures include sanitation of the pen environment (i.e. cleaning and drying), thus reducing the numbers of free-living larvae and avoiding maceration of the skin with less risk of percutaneous transmission. Recently introduced welfare-promoting changes in pig management (i.e. the provision of sprinklers and rooting material) may result in a higher risk of infection (Roepstorff *et al.* 2011).

Concluding remarks

To conclude, all domestic livestock species, equine, cats and dogs can be affected by members of the *Strongyloides* genus. Generally, these infections are of low relative importance compared with other (for example, Clade V) nematode species. In livestock and equines, this is because *Strongyloides* infections are probably not as common as they used to be due to extensive use of macrocyclic lactone anthelmintics that prevent and/or reduce the important route of vertical transmission via the milk after parturition. Furthermore, unlike other gastrointestinal nematode species in domestic animals, young hosts develop protective immunity rapidly to these parasites so that the effects are generally short lived and immature hosts play a negligible part in the transmission cycle. Nevertheless, infections are not uncommon in colder temperate

climates in livestock and equines and in all climates in dogs. Further, low-input and organic livestock production systems, where use of macrocyclic lactones is either banned or limited, or management systems applying selective targeted treatments may experience more intense transmission and higher risk of disease. However, as mentioned above, to date the limited evidence available does not indicate increased prevalence on organic pig farms. Clinical cases, when they occur, are usually only seen in very young animals due to the acquisition of high levels of infection, which can be associated with low levels of hygiene and/or maceration of pedal skin. The subclinical impact of early life infection with these nematodes is largely unknown and deserves further investigation, including studies on the putative increase in prevalence in foals. Future prevalence studies need to include molecular typing of different *Strongyloides* species in relation to different hosts e.g., the uncertainties regarding species (or subtypes) of *Strongyloides* that are exchanged between different ruminant species. Also, more research is urgently needed on the potential zoonotic capacity of *Strongyloides* from dogs and cats based on molecular typing, detailed information on risk factors and mapping of transmission routes.

FINANCIAL SUPPORT

This research received no specific grant from any funding agency, commercial or not-for-profit sectors.

REFERENCES

- Abu-Madi, M. A., Al-Ahbab, D. A., Al-Mashhadani, M. M., Al-Ibrahim, R., Pal, P. and Lewis, J. W. (2007). Patterns of parasitic infections in faecal samples from stray cat populations in Qatar. *Journal of Helminthology* **81**, 281–286.
- Adams, P. J., Elliot, A. D., Algar, D. and Brazell, R. I. (2008). Gastrointestinal parasites of feral cats from Christmas Island. *Australian Veterinary Journal* **86**, 60–63.
- Akkari, H., Gharbi, M. and Darghouth, M. A. (2012). Dynamics of infestation of tracers lambs by gastrointestinal helminths under a traditional management system in the North of Tunisia. *Parasite* **19**, 407–415.
- Asano, K., Suzuki, K., Matsumoto, T., Sakai, T. and Asano, R. (2004). Prevalence of dogs with intestinal parasites in Tochigi, Japan in 1979, 1991 and 2002. *Veterinary Parasitology* **120**, 243–248.
- Balicka-Ramisz, A., Ramisz, G. and Zychlinska-Buczek, J. (2013). The annual population dynamics of gastrointestinal nematodes in breeding sheep of the Silesian Foothills, southern Poland. *Annals of Parasitology* **59**, 163–167.
- Barth, D. and Preston, J. M. (1985). Efficacy of ivermectin against somatic *Strongyloides ransomi* larvae. *Veterinary Record* **116**, 366–367.
- Barth, D., Rehbein, S., Reid, J. F. S. and Barrick, R. A. (1996). Efficacy of an in-feed formulation of ivermectin against adult worms and somatic larvae of *Strongyloides ransomi*. *Veterinary Parasitology* **65**, 89–97.
- Barutzki, D., Randelzhofer, A. and Gothe, R. (1992). Artenspektrum und Befallshäufigkeit von Helminthen bei Mutterschweinen und ihren Ferkeln in Süddeutschland. *Tierärztlicher Umschau* **47**, 179–190.
- Bowman, D. D., Hendrix, C. M., Lindsay, D. S. and Barr, S. C. (2002). *Feline Clinical Parasitology*. Iowa State University Press, Ames, USA.
- Brown, C. A., MacKay, R. J., Chandra, S., Davenport, D. and Lyons, E. T. (1997). Overwhelming strongyloidosis in a foal. *Journal of American Veterinary Medicine Association* **211**, 333–334.
- Buzubik, B. (1965). Failure to establish infection in rats and guinea pigs exposed to the larvae of *Strongyloides papillosus*. *Acta Parasitologica Polonica* **13**, 349–354.
- Carstensen, L., Vaarst, M. and Roepstorff, A. (2002). Endoparasite infections in Danish organic swine herds. *Veterinary Parasitology* **106**, 253–264.
- Crosthwaite, A. I., Huizinga, J. D. and Fox, J. A. (1990). Jejunal circular muscle motility is decreased in nematode-infected rat. *Gastroenterology* **98**, 59–65.
- Davis, L. R., Herlich, H. and Bowman, G. W. (1960). Studies on experimental concurrent infections of dairy calves with coccidia and nematodes. III. *Eimeria* spp. and the thread worm, *Strongyloides papillosus*. *American Journal of Veterinary Research* **21**, 181–187.
- Deplazes, P., Eckert, J., von Samson-Himmelstjerna, G. and Zahner, H. (2013). *Lehrbuch der Parasitologie für die Tiermedizin*, Enke Verlag, Stuttgart, 639 pp.
- Dey-Hazra, A., Sallmann, H. P., Enigk, K. and Harisch, G. (1979). Protein synthesis changes in the liver of piglets infected with *Strongyloides ransomi*. *Veterinary Parasitology* **5**, 339–351.
- Dillard, K. J., Saari, S. A. M. and Anttila, M. (2007). *Strongyloides stercoralis* infection in a Finnish kennel. *Acta Veterinaria Scandinavica* **49**, 37.
- Dimitrijevic, B., Borozan, S., Katic-Radojevic, S. and Stojanovic, S. (2012). Effects of infection intensity with *Strongyloides papillosus* and albendazole treatment on development of oxidative/nitrosative stress in sheep. *Veterinary Parasitology* **186**, 364–375.
- Di Pietro, J. A. (1989). A review of *Strongyloides westeri* infection in foals. *Equine Practice* **11**, 35–37.
- Drag, M. D., Green, S. E., Howser, R. A., Wallace, D. H., Cox, J. L. and Barrick, R. A. (1998). Efficacy of an in-feed formulation of ivermectin against somatic larvae of *Strongyloides ransomi* in pregnant swine. *American Journal of Veterinary Research* **59**, 277–279.
- Eberhardt, A. G., Mayer, W. E., Bonfoh, B. and Streit, A. (2008). The *Strongyloides* (Nematoda) of sheep and the predominant *Strongyloides* of cattle form at least two different, genetically isolated populations. *Veterinary Parasitology* **157**, 89–99.
- Enigk, K. and Dey-Hazra, A. (1975). Intestinal plasma and blood loss in piglets infected with *Strongyloides ransomi*. *Veterinary Parasitology* **1**, 69–75.
- Enigk, K., Weingartner, E. and Schmelzle, H. M. (1974a). Chemoprophylaxis of *Strongyloides* infection in milk of the pig. *Zentralblatt für Veterinärmedizin, B* **21**, 413–425.
- Enigk, K., Weingartner, E., Hazem, A. S., Schmelzle, H. M. and Stoye, M. (1974b). Prenatal *Strongyloides* infection of pigs. *Tierärztliche Umschau* **29**, 265–268.
- Faust, E. C. and Kagy, E. S. (1933). Experimental studies on human and primate species of *Strongyloides*. I. The variability and instability of types. *American Journal of Tropical Medicine* **12**, 47–65.
- Felippelli, G., Cruz, B. C., Gomes, L. V., Lopes, W. D., Teixeira, W. F., Maciel, W. G., Buzzulini, C., Bichuette, M. A., Campos, G. P., Soares, V. E., Bergamasco, P. L., Oliveira, G. P. and Costa, A. J. (2015). Susceptibility of helminth species from horses against different chemical compounds in Brazil. *Veterinary Parasitology* **212**, 232–238.
- Fukase, T., Chinone, S. and Itagaki, H. (1985). *Strongyloides planiceps* (Nematoda; Strongyloididae) in Some Wild Carnivores. *Japanese Journal of Veterinary Science* **47**, 627–632.
- Galliard, H. (1950). Recherches sur l'infestation expérimentale à *Strongyloides stercoralis* au Tonkin (1ère note). *Annales de Parasitologie Humaine et Comparée* **25**, 441–473.
- Galliard, H. (1951a). Recherches sur l'infestation expérimentale à *Strongyloides stercoralis* au Tonkin (2e note). *Annales de Parasitologie Humaine et Comparée* **26**, 67–84.
- Galliard, H. (1951b). Recherches sur l'infestation expérimentale à *Strongyloides stercoralis* au Tonkin (3e note). *Annales de Parasitologie Humaine et Comparée* **26**, 201–227.
- Gates, M. C. and Nolan, T. J. (2009). Endoparasite prevalence and recurrence across different age groups of dogs and cats. *Veterinary Parasitology* **166**, 153–158.
- Gawor, J. J. (1995). The prevalence and abundance of internal parasites in working horses autopsied in Poland. *Veterinary Parasitology* **58**, 99–108.
- Genta, R. M. (1989). *Strongyloides stercoralis*: loss of ability to disseminate after repeated passage in laboratory beagles. *Transactions of the Royal Society of Tropical Medicine and Hygiene* **83**, 539–541.
- Genta, R. M., Schad, G. A. and Hellman, M. E. (1986). *Strongyloides stercoralis*: parasitological, immunological and pathological observations in immunosuppressed dogs. *Transactions of the Royal Society of Tropical Medicine and Hygiene* **80**, 34–41.
- Gregory, P. C., Wenham, G., Poppi, D., Coop, R. L., MacRae, J. C. and Miller, S. J. (1985). The influence of chronic subclinical infection of *Trichostrongylus colubriformis* on gastrointestinal motility and digesta flow in sheep. *Parasitology* **91**, 381–396.
- Hiepe, T., Nickel, S. and Siebeke, F. (1975). Studies on the dynamics of *Strongyloides* egg release under stud conditions. *Folia Parasitologica (Praha)* **22**, 341–344.

- Hoegaasen, H. R., Hamnes, I. S., Davidson, R. and Lund, A. (2012). Import risk of street dogs from Eastern Europe [in Norwegian]. *Norwegian Veterinary Institute Report Series* **11**, 1–30.
- Itoh, N., Kanai, K., Hori, Y., Hoshi, F. and Higuchi, S. (2009a). Prevalence of *Giardia intestinalis* and other zoonotic intestinal parasites in private household dogs of the Hachinohe area in Aomori prefecture, Japan in 1997, 2002 and 2007. *Journal of Veterinary Science* **10**, 305–308.
- Itoh, N., Kanai, K., Hori, Y., Nakao, R., Hoshi, F. and Higuchi, S. (2009b). Fenbendazole treatment of dogs with naturally acquired *Strongyloides stercoralis* infection. *Veterinary Record* **164**, 559–560.
- Jäger, M., Gaulty, M., Bauer, C., Failing, K., Erhardt, G. and Zahner, H. (2005). Endoparasites in calves of beef cattle herds: management systems dependent and genetic influences. *Veterinary Parasitology* **131**, 173–191.
- Jiménez, A. E., Fernandez, A., Alfaro, R., Dolz, G., Vargas, B., Epe, C. and Schnieder, T. (2010). A cross-sectional survey of gastrointestinal parasites with dispersal stages in feces from Costa Rican dairy calves. *Veterinary Parasitology* **173**, 236–246.
- Joachim, A. and Dauschies, A. (2000). Endoparasites in swine in different age groups and management systems. *Berliner Munchen Tierärztliche Wochenschrift* **113**, 129–133.
- Junior, A. F., Goncalves-Pires, M. R. F., Silva, D. A. O., Goncalves, A. L. R. and Costa-Cruz, J. M. (2006). Parasitological and serological diagnosis of *Strongyloides stercoralis* in domesticated dogs from southeastern Brazil. *Veterinary Parasitology* **136**, 137–145.
- Kabululu, M. W., Ngowi, H. A., Kimera, S. I., Lekule, F. P., Kimbi, E. C. and Johansen, M. V. (2015). Risk factors for prevalence of pig parasitoses in Mbeya Region, Tanzania. *Veterinary Parasitology* **212**, 460–464.
- Khalafalla, R. E., Elseify, M. A. and Elbahy, N. M. (2011). Seasonal prevalence of gastrointestinal nematode parasites of sheep in Northern region of Nile Delta, Egypt. *Parasitology Research* **108**, 337–340.
- Knecht, D., Popiołek, M. and Zale, G. (2011). Does meatiness of pigs depend on the level of gastro-intestinal parasites infection? *Preventive Veterinary Medicine* **99**, 234–239.
- Kobayashi, I. and Horii, Y. (2008). Gastrointestinal motor disturbance in rabbits experimentally infected with *Strongyloides papillosus*. *Veterinary Parasitology* **158**, 67–72.
- Kobayashi, I., Kajisa, M., Farid, A. S., Yamanaka, A. and Horii, Y. (2009). Paralytic ileus and subsequent death caused by enteric parasite, *Strongyloides papillosus*, in Mongolian gerbils. *Veterinary Parasitology* **162**, 100–105.
- Logan, N. B., Weatherley, A. J. and Jones, R. M. (1996). Activity of doramectin against nematode and arthropod parasites of swine. *Veterinary Parasitology* **66**, 87–94.
- Lopes, W. D. Z., Teixeira, W. F. P., Felipelli, G., Cruz, B. C., Buzulini, C., Maciel, W. G., Fávero, F. C., Gomes, L. V. C., Prando, L., Bichuette, M. A., Santos, T. R. and Costa, A. J. (2014). Anthelmintic efficacy of ivermectin and abamectin, administered orally for seven consecutive days ($100 \mu\text{g}^{-1}\text{kg day}^{-1}$), against nematodes in naturally infected pigs. *Research in Veterinary Science* **97**, 546–549.
- Ludwig, K. G., Craig, T. M., Bowen, J. M., Ansari, M. M. and Ley, W. B. (1983). Efficacy of ivermectin in controlling *Strongyloides westeri* infections in foals. *American Journal of Veterinary Research* **44**, 314–316.
- Lyons, E. T. and Tolliver, S. C. (2014). Prevalence of patent *Strongyloides westeri* infections in thoroughbred foals in 2014. *Parasitology Research* **113**, 4163–4164.
- Lyons, E. T., Tolliver, S. C., Drudge, J. H., Granstrom, D. E. and Collins, S. S. (1993). Natural infections of *Strongyloides westeri*: prevalence in horse foals on several farms in central Kentucky in 1992. *Veterinary Parasitology* **50**, 101–107.
- Mansfield, L. S. and Schad, G. A. (1995). Lack of transmammmary transmission of *Strongyloides stercoralis* from a previously hyperinfected bitch to her pups. *Journal of the Helminthological Society of Washington* **62**, 80–83.
- Mansfield, L. S., Alavi, A., Wortman, J. A. and Schad, G. (1995). Gamma camera scintigraphy for direct visualization of larval migration in *Strongyloides stercoralis*-infected dogs. *American Journal of Tropical Medicine and Hygiene* **52**, 236–240.
- Mansfield, L. S., Niamatali, S., Bhopale, V., Volk, S., Smith, G., Lok, J. B., Genta, R. M. and Schad, G. A. (1996). *Strongyloides stercoralis*: maintenance of exceedingly chronic infections. *American Journal of Tropical Medicine and Hygiene* **55**, 617–624.
- Marley, S. E., Illyes, E. F., Keller, D. S., Meinert, T. R., Logan, N. B., Hendrickx, M. O. and Conder, G. A. (1999). Efficacy of topically administered doramectin against eyeworms, lungworms, and gastrointestinal nematodes of cattle. *American Journal of Veterinary Research* **60**, 665–668.
- Marzio, L., Blennerhassett, P., Chiverton, S., Vermillion, D. L., Langer, J. and Collins, S. M. (1990). Altered smooth muscle function in worm-free gut regions of *Trichinella*-infected rats. *American Journal of Physiology* **259**, G306–G313.
- Mfitlodze, M. W. and Hutchinson, G. W. (1989). Prevalence and intensity of non-strongyle intestinal parasites of horses in northern Queensland. *Australian Veterinary Journal* **66**, 23–26.
- Mircean, V., Titilincu, A. and Vasile, C. (2010). Prevalence of endoparasites in household cat (*Felis catus*) populations from Transylvania (Romania) and association with risk factors. *Veterinary Parasitology* **171**, 163–166.
- Mirck, M. H. (1977). *Strongyloides westeri* Ihle, 1917 (Nematoda: Strongyloidea). I. Parasitological features of natural infection. *Tijdschrift Diergeneeskunde* **102**, 1039–1043.
- Mirck, M. H. and Franken, P. (1978). *Strongyloides westeri* Ihle, 1917 (Nematoda: Strongyloidea). II. Parasitological and haematological features of experimental infection. *Tijdschrift Diergeneeskunde* **103**, 355–360.
- Mohd Zain, S. N., Sahimin, N., Pal, P. and Lewis, J. W. (2013). Macroparasite communities in stray cat populations from urban cities in Peninsular Malaysia. *Veterinary Parasitology* **196**, 469–477.
- Moncol, D. J. (1975). Supplement to the life history of *Strongyloides ransomi* Schwartz and Alicata, 1930 (Nematoda: Strongyloidea) of pigs. *Proceedings of the Helminthological Society of Washington* **42**, 86–92.
- Moncol, D. J. and Batte, E. G. (1966). Transcolostral infection of newborn pigs with *Strongyloides ransomi*. *Veterinary Medicine Small Animal Clinician* **61**, 583–686.
- Murrell, K. D. (1981). Induction of protective immunity to *Strongyloides ransomi* in pigs. *American Journal of Veterinary Research* **42**, 1915–1919.
- Nakanishi, N., Nakamura, Y., Ura, S., Tsuji, N., Taira, N., Tanimura, N. and Kubo, M. (1993). Sudden death of calves by experimental infection with *Strongyloides papillosus*. III. Hematological, biochemical and histological examinations. *Veterinary Parasitology* **47**, 67–76.
- Nakamura, Y., Tsuji, N. and Taira, N. (1994). Wasting condition under normal cardiac rhythms in rabbits following *Strongyloides papillosus* infection. *Journal of Veterinary Medical Science* **56**, 1005–1007.
- Neilson, J. T. and Ngheim, N. D. (1974). The dynamics of *Strongyloides papillosus* primary infection in neonatal and adult rabbits. *Journal of Parasitology* **60**, 786–789.
- Netherwood, T., Wood, J. L., Townsend, H. G., Mumford, J. A. and Chanter, N. (1996). Foal diarrhoea between 1991 and 1994 in the United Kingdom associated with *Clostridium perfringens*, rotavirus, *Strongyloides westeri* and *Cryptosporidium* spp. *Epidemiology of Infections* **117**, 375–383.
- Nganga, C. J., Karanja, D. N. and Mutune, M. N. (2008). The prevalence of gastrointestinal helminth infections in pigs in Kenya. *Tropical Animal Health and Production* **40**, 331–334.
- Nolan, T. J. (2001). Canine Strongyloidiasis. In Companion and Exotic Animal Parasitology (ed. Bowman, D. D.), International Veterinary Information Service (www.ivia.org), Ithaca, New York, USA.
- Nwaorgu, O. C. and Connan, R. M. (1980). The migration of *Strongyloides papillosus* in rabbits following infection by the oral and subcutaneous routes. *Journal of Helminthology* **54**, 223–232.
- Palmer, J. M., Wong-Riley, M. and Sharkey, K. A. (1998). Functional alterations in jejunal myenteric neurons during inflammation in nematode-infected guinea pigs. *American Journal of Physiology* **275**, G922–G935.
- Palmer, C. S., Thompson, R. C., Traub, R. J., Reese, R. and Robertson, I. D. (2008). National study of the gastrointestinal parasites of dogs and cats in Australia. *Veterinary Parasitology* **151**, 181–190.
- Paulos, D., Addis, M., Fromsa, A. and Mekibib, B. (2012). Prevalence of gastrointestinal helminthes among dogs and owners perception about zoonotic dog parasites in Hawassa Town, Ethiopia. *Journal of Public Health and Epidemiology* **4**, 205–209.
- Pienaar, J. G., Basson, P. A., du Plessis, J. L., Collins, H. M., Naude, T. W., Boyazoglu, P. A., Boomker, J., Reyers, F. and Pienaar, W. L. (1999). Experimental studies with *Strongyloides papillosus* in goats. *Onderstepoort Journal of Veterinary Medicine* **66**, 191–235.
- Ramachandran, S., Gam, A. A. and Neva, F. A. (1997). Molecular differences between several species of *Strongyloides* and comparison of selected isolates of *S. stercoralis* using a polymerase chain reaction-linked restriction fragment length polymorphism approach. *American Journal of Tropical Medicine and Hygiene* **56**, 61–65.
- Ranjan, S. and Delay, R. (2004). Therapeutic and persistent efficacy of moxidectin 1% nonaqueous injectable formulation against natural and experimentally induced lung and gastrointestinal nematodes in cattle. *Veterinary Parasitology* **120**, 305–317.
- Raynaud, J. P., Sennelier, J., and Irisarri, E. (1975). Post-natal parasitic infection of piglets in contact with infected mothers. A study of 20 sows and 164 piglets, 42 of which were killed at weaning. *Folia Veterinaria Latina* **5**, 412–429.
- Relf, V. E., Morgan, E. R., Hodgkinson, J. E. and Matthews, J. B. (2013). Helminth egg excretion with regard to age, gender and management practices on UK Thoroughbred studs. *Parasitology* **140**, 641–652.

- Riggio, F., Mannella, R., Ariti, G. and Perrucci, S.** (2013). Intestinal and lung parasites in owned dogs and cats from central Italy. *Veterinary Parasitology* **193**, 78–84.
- Roepstorff, A.** (1991). Transmission of intestinal parasites in Danish sow herds. *Veterinary Parasitology* **39**, 149–160.
- Roepstorff, A. and Nansen, P.** (1998). *Epidemiology, Diagnosis and Control of Helminth Parasites of Swine*. FAO Animal health manual No. 3, FAO, Rome.
- Roepstorff, A. K., Nilsson, O., Oksanen, A., Gjerde, B., Richter, S. H., Ortenberg, E., Christensson, D., Martinsson, K. B., Bartlett, P. C., Nansen, P., Eriksen, L., Helle, O., Nikander, S. and Larsen, K.** (1998). Intestinal parasites in swine in the Nordic countries: prevalence and geographical distribution. *Veterinary Parasitology* **76**, 305–319.
- Roepstorff, A., Mejer, H., Nejsum, P. and Thamsborg, S. M.** (2011). Helminth parasites in pigs: new challenges in pig production and current research highlights. *Veterinary Parasitology* **180**, 72–81.
- Schad, G. A., Aikens, L. M. and Smith, G.** (1989). *Strongyloides stercoralis*: is there a canonical migratory route through the host? *Journal of Parasitology* **75**, 740–749.
- Schär, F., Guo, L., Streit, A., Khieu, V., Muth, S., Marti, H. and Odermatt, P.** (2014). *Strongyloides stercoralis* genotypes in humans in Cambodia. *Parasitology International* **63**, 533–536.
- Shoop, W. L., Michael, B. F., Eary, C. F. and Haines, H. W.** (2002). Transmammary transmission of *Strongyloides stercoralis* in dogs. *Journal of Parasitology* **88**, 536–539.
- Speare, A. and Tinsley, D. J.** (1986). *Strongyloides felis*: an “old” worm rediscovered in Australian cats. *Australian Veterinary Practitioner* **16**, 10–18.
- Speare, A. and Tinsley, D. J.** (1987). Survey of cats for *Strongyloides felis*. *Australian Veterinary Journal* **64**, 191–192.
- Stewart, T. B. and Hale, O. M.** (1988). Losses to internal parasites in swine production. *Journal of Animal Science* **66**, 1548–1554.
- Stewart, T. B., Stone, W. M. and Marti, O. G.** (1976). *Strongyloides ransomi*: prenatal and transmammmary infection of pigs of sequential litters from dams experimentally exposed as weanlings. *American Journal of Veterinary Research* **37**, 541–544.
- Streit, A.** (2008). Reproduction in *Strongyloides* (Nematoda): a life between sex and parthenogenesis. *Parasitology* **135**, 285–294.
- Taira, N. and Ura, S.** (1991). Sudden death in calves associated with *Strongyloides papillosum* infection. *Veterinary Parasitology* **39**, 313–319.
- Taira, N., Minami, T. and Smitanon, J.** (1991). Dynamics of faecal egg counts in rabbits experimentally infected with *Strongyloides papillosum*. *Veterinary Parasitology* **39**, 333–336.
- Taira, N., Nakamura, Y., Tsuji, N., Kubo, M. and Ura, S.** (1992). Sudden death of calves by experimental infection with *Strongyloides papillosum*. I. Parasitological observations. *Veterinary Parasitology* **42**, 247–256.
- Takano, Y., Minakami, K., Kodama, S., Matsuo, T. and Satozono, I.** (2009). Cross infection of *Strongyloides* between humans and dogs in the Amami Islands, Japan. *Tropical Medicine and Health* **37**, 149–152.
- Takeuchi-Storm, N., Mejer, H., Al-Sabi, M. N., Olsen, C. S., Thamsborg, S. M. and Enemark, H. L.** (2015). Gastrointestinal parasites of cats in Denmark assessed by necropsy and concentration McMaster technique. *Veterinary Parasitology* **214**, 327–332.
- Tassi, P., Barth, D. and Gross, S. J.** (1990). The efficacy of ivermectin against *Strongyloides papillosum* in cattle. *Parasitologia* **32**, 347–352.
- Teixeira, W. F., Felippelli, G., Cruz, B. C., Maciel, W. G., Fávero, F. C., Gomes, L. V., Buzzulini, C., Prando, L., Bichuette, M. A., Lopes, W. D., Oliveira, G. P. and Costa, A. J.** (2014). Endoparasites of horses from the Formiga city, located in center-west region of the state of Minas Gerais, Brazil. *Brazilian Journal of Veterinary Parasitology* **23**, 534–538.
- Tsuji, N., Itabisashi, T., Nakamura, Y., Taira, N., Kubo, M., Ura, S. and Genno, A.** (1992). Sudden cardiac death in calves with experimental heavy infection of *Strongyloides papillosum*. *Journal of Veterinary Medical Science* **54**, 1137–1143.
- Ura, S., Nakamura, Y., Tsuji, N. and Taira, N.** (1992). Sudden death of calves by experimental infection with *Strongyloides papillosum*. II. Clinical observations and analysis of critical moments of the disease recorded on videotape. *Veterinary Parasitology* **44**, 107–110.
- Ura, S., Taira, N., Nakamura, Y., Tsuji, N. and Hirose, H.** (1993). Sudden death of calves by experimental infection with *Strongyloides papillosum*. IV. Electrocardiographic and pneumographic observations at critical moments of the disease. *Veterinary Parasitology* **47**, 343–347.
- Vegors, H. H.** (1954). Experimental infection of calves with *Strongyloides papillosum* (Nematode). *American Journal of Veterinary Research* **15**, 429–433.
- Zajac, A. M. and Saleh, M.** (2013). The Baermann test: try this parasitology test in your practice. *Veterinary Medicine* **108**, 18–23.