


Long-term outcomes of visual motor integration and motor development children with retinopathy of prematurity

Seval Kutlutürk Yıkılmaz¹ , Gokhan Celik², Murat Gunay³, Osman Kizilay² and Zeliha Candan Algun⁴

Original Article

Cite this article: Kutlutürk Yıkılmaz S, Celik G, Gunay M, Kizilay O, and Algun ZC. (2024) Long-term outcomes of visual motor integration and motor development children with retinopathy of prematurity. *Journal of Developmental Origins of Health and Disease* 15: e10, 1–8. doi: [10.1017/S2040174424000151](https://doi.org/10.1017/S2040174424000151)

Received: 27 March 2024

Revised: 11 April 2024

Accepted: 12 April 2024

Keywords:

Intravitreal bevacizumab; laser; motor development; neurodevelopmental outcomes; retinopathy of prematurity; visual motor integration

Corresponding author:

S. Kutlutürk Yıkılmaz;
Email: seval.kutluturkyikilmaz@sbu.edu.tr

¹Department of Physiotherapy and Rehabilitation, Faculty of Hamidiye Health Sciences, University of Health Sciences, Istanbul, Turkey; ²Department of Ophthalmology, Zeynep Kamil Maternity and Children's Diseases Training and Research Hospital, Istanbul, Turkey; ³Department of Ophthalmology, Faculty of Medicine, Karadeniz Technical University, Trabzon, Turkey and ⁴Department of Physical Therapy and Rehabilitation, Graduate School of Health Sciences, Istanbul Medipol University, Istanbul, Turkey

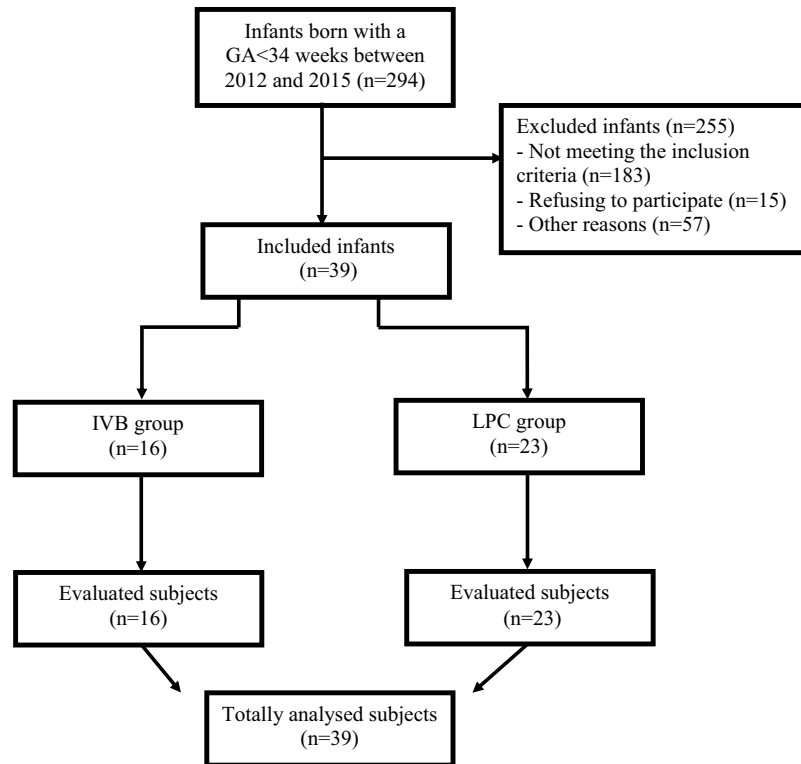
Abstract

Premature infants have a risk of neurodevelopmental deficits. Little is known, however, about how retinopathy of prematurity (ROP) affects visual motor integration (VMI), which is necessary for both fine motor skills and further school abilities. Due to the systemic escape of bevacizumab in the treatment of ROP, concerns regarding the long-term neurodevelopmental effect of the drug have arisen. The aim is to evaluate VMI and motor development long-term outcomes after intravitreal bevacizumab (IVB) injection and laser treatment for ROP. Two groups of premature children were included: Bevacizumab group – 16 premature children who received IVB treatment and laser group – 23 premature children who underwent laser photocoagulation treatment in this single center cross-sectional study. At 2–6 years of age, VMI (Beery–Buktenica Developmental Test), motor development (Peabody Developmental Motor Scales-2), visual acuity, and refractive status were assessed. The incidence of abnormal visual function was significantly higher in bevacizumab group than in laser group ($p = 0.022$). The incidence of abnormal VMI skill was significantly higher in bevacizumab group than in laser group ($p = 0.024$). Incidences of abnormal gross, fine, and total motor skills were significantly higher in bevacizumab group compared to laser group ($p < 0.05$). Premature children who received bevacizumab for ROP demonstrated significantly lower VMI and motor development features than those with laser treatment at preschool age. Although our results suggest the relevance of bevacizumab injection in impaired VMI and motor development outcomes, general level of sickness rather than treatment might be the cause of delayed motor development.

Introduction

Retinopathy of prematurity (ROP) is a leading cause of childhood blindness in developed and developing countries worldwide. Approximately 32,300 infants worldwide are diagnosed with irreversible vision impairment due to ROP annually, of which approximately 20,000 become blind or severely visually impaired.¹ The main mechanism of this disease includes the arrest of normal retinal and neuronal vascular development that results in aberrant pathological retinal vascularization.² Laser therapy has been approved to be the gold standard approach in ROP treatment, however it showed some failures especially in severe ROP cases in terms of structural and functional results.^{3,4} Later on, studies have demonstrated a clear treatment benefit of intravitreal anti-vascular endothelial growth factor (VEGF) injections in severe ROP cases resulting in prompt regression of the disease. For this purpose, intravitreal bevacizumab (IVB) has been commonly used as an anti-VEGF agent in ROP treatment.^{5,6} In 2011, The Bevacizumab Eliminates the Angiogenic Threat of ROP (BEAT-ROP) study, a prospective, controlled, randomized, and multicenter trial has shown that IVB as monotherapy was significantly useful as compared to laser treatment particularly for the infants with Zone I ROP.⁷

It has been shown that VEGF has a fundamental effect on neurodevelopmental status of the infants,⁸ and concerns have arisen whether systemic suppression of VEGF with IVB may have an influence on long-term neurodevelopment of the premature children.⁹ Thus far, several studies have evaluated this issue, some indicating no adverse effects of IVB on neurodevelopmental outcomes while others showing higher risk of neurodevelopmental disabilities following IVB.^{9–12} It is suggested that detecting differences in neurodevelopmental outcomes between treatment modalities, evaluating measurable differences, and careful and systematic evaluation of long-term outcomes in these populations. It is also reported that a better understanding of the long-term structural and functional ocular outcomes following anti-VEGF



Abbreviations: GA, Gestational age; IVB, Intravitreal bevacizumab; LPC, Laser photocoagulation

Figure 1. Flow chart of the study.

therapy will assist in providing the context and balancing the potential benefits and harms of anti-VEGF therapy in ROP.¹³

In a few ROP studies, there has been discussed visual motor integration (VMI) skills and motor development's long-term outcomes.^{14,15} The impact of ROP on VMI, however, is less well understood. VMI is the ability to perceive visual information, analyze it, and achieve a motor response. It comprises fine and gross motor skills, visual perceptual (VP) abilities, eye-hand coordination, and motor coordination (MC).¹⁶ Being cognitively normal at preschool age but having difficulty in writing, sketching, and throwing or catching a ball abilities that are achieved with VMI skills could be a risk factor for poor school achievement.¹⁷ As far as we know, the differences between the VMI skills of children with ROP according to the types of treatment received were not included in previous studies. The present study aimed to investigate long-term outcomes of VMI and motor development outcomes of premature infants between 2 and 6 years of age who previously had IVB injections and laser treatment. The hypothesis of the study is that there are differences in long-term VMI and motor development outcomes between premature infants who have received prior IVB injection and laser treatment.

Methods

Participants

This cross-sectional study conducted at a single center received approval from the institutional review board of Istanbul Medipol

University under the reference number 10840098-604.01.01-E.34158, adhering to the principles of the Declaration of Helsinki. Prior to participation, written and oral informed consent was voluntarily obtained from the parents of each participant. The authors have access to participant information, with measures taken to protect confidentiality both during and after data collection.

The research encompassed children who underwent treatment for ROP from 2012 to 2015 at Zeynep Kamil Maternity and Children's Diseases Training and Research Hospital, recognized as a leading tertiary referral center for ROP in Turkey. This investigation comprised two distinct groups: the IVB group, comprising children who underwent IVB treatment, and the LPC (laser photocoagulation) group, comprising children treated with LPC. A visual representation of the study's progression can be found in Figure 1.

All children were chosen from the hospital's patient records and contacted via telephone to participate in the study. Those aged between 2 and 6 years with a gestational age (GA) below 34 weeks were eligible for inclusion. Exclusion criteria encompassed children displaying insufficient cooperation during ophthalmologic examinations and neurodevelopmental tests, as well as those with a history of ocular diseases unrelated to ROP or any systemic ailments, including neurological, congenital, and metabolic conditions.

All premature infants in the study underwent standard ROP screening examinations four weeks after birth, adhering to international protocols.¹⁸ Treatment eligibility was determined

based on predefined criteria, with options including IVB or LPC. Treatment decisions were guided by established guidelines.³ Ahead of interventions, parents were briefed on LPC treatment, highlighting its limitations in posterior ROP and potential side effects such as hindering peripheral retinal vascularization and yielding higher refractive outcomes compared to IVB.⁴ Subsequently, parents were tasked with deciding whether to pursue IVB or LPC treatment. In cases where IVB was chosen, patients and/or guardians were informed of the potential treatment effects and systemic considerations associated with bevacizumab before proceeding with treatment.

Demographic and clinical data of the children including, gender, GA, birth weight (BW), zone and stage of ROP, mode of delivery, multiple pregnancy, and duration of hospitalization in neonatal intensive care unit were recorded. ROP stages were defined according to the International Committee for the Classification of Retinopathy of Prematurity (ICROP).¹⁹

Assessments

Visual and refractive assessments

Best corrected visual acuity (BCVA) was measured in all children by using a Snellen chart. Snellen VA was converted to the logarithm of the minimum angle of resolution (logMAR) VA for statistical analysis. The VA results were categorized according to the current World Health Organization visual outcome criteria as follows,²⁰ mild vision impairment (worse than 6/12 and equal to or better than 6/18), moderate vision impairment (worse than 6/18 and equal to or better than 6/60) and severe vision impairment (worse than 6/60 and equal to or better than 3/60). For the purpose of the present study, normal vision was considered if BCVA was $\geq 6/12$ (0.3 logMAR) and abnormal vision was considered if BCVA was $< 6/12$ (0.3 logMAR).

Automatic refraction was performed with a handheld autorefractometer (HandyRef-K Autorefractometer, Nidek, Gamagori, Japan) in each child after 30 minutes following two instillations of cyclopentolate eye drop. Refractive results were converted into spherical equivalent (SE) values and categorized as emmetropia if SE was $(-1 \text{ D} - 1 \text{ D})$, myopia if SE was under -1 D and hypermetropia if SE was above 1 D which was based on previous studies.^{21,22}

The Beery-Buktenica Developmental Test of Visual Motor Integration

A pediatric physiotherapist with nine years of experience (SKY), who was unaware of the study groups, assessed the neurodevelopmental status of the children. The Beery-Buktenica Developmental Test of Visual Motor Integration (Beery VMI) was employed to gauge the levels of VMI, VP, and MC in the children. Following the administration of the Beery VMI – Short Form test, the Beery VP and MC tests were conducted individually. Utilizing both the total score and the child's chronological age, the VMI, MC, and VP levels were categorized as “very low, low, below average, above average, high, or very high,” based on normative values outlined in the test's instruction manual.¹⁶

The Peabody Developmental Motor Scales-2 (PDMS-2)

We utilized the motor development assessment scale to facilitate an early childhood motor development program tailored for children from birth to 5 years old, offering comprehensive evaluation and intervention for both gross and fine motor skills.²³ Notably, the upper age limit for administering the PDMS-2

assessment is 71 months. Thus, we restricted our study to children aged between 24 and 71 months. The PDMS-2 scores are comprised of three key components: (1) Gross Motor Quotient, encompassing Reflexes, Stationary, Locomotion, and Object Manipulation subtests; (2) Fine Motor Quotient, derived from Grasping and VMI subtests; and (3) Total Quotient, integrating both gross and fine motor subtests.^{23,24}

During the study, under average levels were classified as “abnormal”, average and above average levels were classified as “normal” for both BBDT and PDMS-2 test findings.

Statistical analyses

The sample size of the study was used with G-Power Sample Size Calculator and reference study data within the 95% confidence interval, and Cohen's *d* coefficient was taken as the effect size. In the power analysis at the end of the study, the power of the study was calculated to be 83% with a 5% error and a large effect size (0.40).²⁵ Statistical Package for Social Sciences-21 (SPSS-21) was used for statistical analysis. Missing values were not inferred. Demographic and clinical characteristics were compared between the groups using Student's *t*-test, Chi-square tests, and Fisher's exact test. For the comparison of visual and refractive outcomes, Fisher's exact and Chi-square tests were used, respectively. As for neurodevelopmental outcomes, comparison of age equivalents of VMI, VP, and MC between the groups were made by using Student's *t*-test. The incidences of BBDT and PDMS-2 test outcomes were compared between the groups by Fisher's exact test except for VP outcomes which were compared by Chi-square test. Statistical significance was assessed at levels of $p < 0.05$.

Results

Two hundred ninety four infants with GA < 34 weeks were admitted to our ophthalmology department between 2012 and 2015; of these, totally 39 children were accepted in the study. There were 16 children (41%), including eight girls and eight boys in IVB group and 23 children (59%), including 8 girls (34.8%) and 15 boys in LPC group. No significant differences of sex was observed between the groups ($p = 0.342$). There were no significant differences between the groups in terms of GA and BW ($p = 0.060$ and $p = 0.075$, respectively). The disease severity was similar between the groups which was indicated by no significant differences in incidences of ROP zone ($p = 0.096$) and ROP stage ($p = 0.208$). The mean duration of hospitalization was significantly higher in IVB-treated children compared to LPC-treated children ($p = 0.004$). The clinical characteristics of the study population are shown in Table 1.

Visual acuity and refractive outcomes are summarized in Table 2. The incidence of abnormal visual function was significantly higher in IVB group than in LPC group ($p = 0.022$). No significant differences were observed regarding refractive status of children in the study. The incidences of emmetropia, hypermetropia, and myopia were similar between the groups ($p = 0.173$).

Motor development outcomes are provided in Table 3, Table 4, and Table 5. The mean age at motor development evaluation was found to be earlier in IVB-treated children compared to LPC-treated children ($p = 0.044$). Referring to BBDT results, mean age equivalents of VMI, VP, and MC did not significantly differ between IVB and LPC groups ($p > 0.05$). The incidence of abnormal VMI level was significantly higher in IVB group than in LPC group ($p = 0.024$). Regarding PDMS-2 results, incidences of

Table 1. Clinical characteristics of the study population

	IVB group	LPC group	<i>P</i>	Effect size
	Mean ± SD	Mean ± SD		
Age at neurodevelopmental assessment (months)	52.81 ± 9.98	60.30 ± 11.69	0.044*	−0.679 ^d
Gestational age (weeks)	27.06 ± 2.82	28.57 ± 2.02	0.060*	−0.633 ^d
Birth weight (g)	1002.13 ± 329.28	1211.74 ± 364.79	0.075*	−0.597 ^d
Duration of hospitalization (days)	81.63 ± 28.76	53.35 ± 27.50	0.004*	1.009 ^d
	<i>N</i> (%)	<i>N</i> (%)		
Gender				
Girls	8 (50%)	8 (%34.8%)	0.342**	0.142 ^v
Boys	8 (50%)	15 (%65.2%)		
ROP zone				
Zone I	4 (25%)	1 (4.3%)	0.096**	0.304 ^v
Zone II	12 (75%)	22 (95.7%)		
ROP stage				
Stage 1 ⁺	2 (12.5%)	0 (0%)	0.208**	0.284 ^v
Stage 2 ⁺	5 (31.3%)	7 (30.4%)		
Stage 3 ⁺	9 (56.2%)	16 (69.6%)		

SD, standard deviation; ROP, retinopathy of prematurity; IVF, in vitro fertilization; C/S, cesarean section, “+” indicates plus disease.

*Student's *t*-test.

**Chi-square test.

***Fisher's exact test, statistical significance ($p < 0.05$).

^dCohen's *d*.

^vCramer's *V*.

Table 2. Visual and refractive outcomes of the study population

	IVB group	LPC group	<i>P</i>	Effect size
	<i>N</i> (%)	<i>N</i> (%)		
Visual acuity				
Normal visual function $\geq 6/12$ (≤ 0.3 logMAR)	12 (75%)	23 (100%)	0.022**	0.405 ^v
Abnormal visual function $< 6/12$ (> 0.3 logMAR)	4 (25%)	0 (0%)		
Refractive state				
Emmetropia	6 (37.5%)	10 (43.5%)	0.547*	0.176 ^v
Hypermetropia	6 (37.5%)	5 (21.7%)		
Myopia	4 (25%)	8 (34.8%)		

logMAR, logarithm of the minimum angle of resolution.

*Chi-square test.

**Fisher's exact test, statistical significance ($p < 0.05$).

^vCramer's *V*.

Table 3. Comparison of age equivalents of VMI, VP, and MC among groups obtained by Beery–Buktenica Developmental Test

Variables (age equivalents, months)	IVB group	LPC group	<i>P</i> *	Effect size
	mean ± SD	mean ± SD		
VMI	39.88 ± 10.49	48.35 ± 14.84	0.057	−0.639 ^d
VP	45.25 ± 12.28	54.65 ± 18.70	0.087	−0.573 ^d
MC	40.69 ± 8.32	44.35 ± 12.18	0.304	−0.339 ^d

SD, standard deviation; VMI, visual motor integration; VP, visual perception; MC, motor coordination.

*Student's *t*-test, statistical significance ($p < 0.05$).

^dCohen's *d*.

Table 4. The BBDT and PDMS-2 results among groups

Variables	IVB group	LPC group	P	Effect size
	N (%)	N (%)		
BBDT				
VMI level				
Abnormal	13 (81.3%)	10 (43.5%)	0.024**	0.378 ^v
Normal	3 (18.7%)	13 (56.5%)		
VP level				
Abnormal	10 (62.5%)	8 (34.8%)	0.088*	0.273 ^v
Normal	6 (37.5%)	15 (65.2%)		
MC level				
Abnormal	12 (75%)	13 (56.5%)	0.317**	0.189 ^v
Normal	4 (25%)	10 (43.5%)		
PDMS-2				
Gross motor skills				
Abnormal	11 (68.7%)	2 (8.7%)	<0.001**	0.627 ^v
Normal	5 (31.3%)	21 (91.3%)		
Fine motor skills				
Abnormal	8 (50%)	4 (17.4%)	0.041**	0.348 ^v
Normal	8 (50%)	19 (82.6%)		
Total motor skills				
Abnormal	10 (62.5%)	4 (17.4%)	0.007**	0.463 ^v
Normal	6 (37.5%)	19 (82.6%)		

BBDT, Beery–Buktenica Developmental Test; PDMS-2, Peabody Developmental Motor Scales-2; VMI, visual motor integration; VP, visual perception; MC, motor coordination.

*Chi-square test.

**Fisher's exact test, statistical significance ($p < 0.05$).

^vCramer's V.

abnormal gross motor, fine motor, and total motor skills were significantly higher in IVB group than in LPC group ($p < 0.05$). Regarding PDMS-2 subtest results, incidences of abnormal locomotion, grasping, and visual motor test outcomes were found to be significantly higher in IVB group than in LPC group ($p < 0.05$).

Discussion

The current study shows that VMI and motor development skills were poorer at 2–6 years of age after being treated with IVB compared to premature infants treated with LPC therapy. This is the first study to show the burden of IVB and LPC treatments on long-term VMI skill and motor development in children with ROP.

Over recent years, IVB treatment has become widespread in ROP and studies have shown higher incidence of favorable structural and functional outcomes following IVB compared to LPC treatment.²⁶ Besides these, investigators demonstrated that IVB significantly reduced plasma VEGF levels with serum drug levels persisting up to two months asserting that IVB can reduce systemic VEGF levels.²⁷ Then, systemic safety of IVB in preterm children has been questioned as VEGF plays a critical role in the developing and adult nervous systems.²⁸ Reduced VEGF expression has been shown to cause decreased neural stem progenitor cell

Table 5. PDMS-2 subtest results among groups

	IVB group	LPC group	P	Effect size
	N (%)	N (%)		
Stationary				
Abnormal	5 (31.3%)	4 (17.4%)	0.444**	0.162 ^v
Normal	11 (68.7%)	19 (82.6%)		
Locomotion				
Abnormal	8 (50%)	2 (8.6%)	0.007*	0.465 ^v
Normal	8 (50%)	21 (91.4%)		
Object manipulation				
Abnormal	6 (37.6%)	6 (26%)	0.453*	0.122 ^v
Normal	10 (62.4%)	17 (74%)		
Grasping				
Abnormal	9 (56.3%)	3 (13%)	0.006**	0.460 ^v
Normal	7 (43.7%)	20 (87%)		
Visual motor				
Abnormal	7 (43.8%)	2 (8.6%)	0.009**	0.409 ^v
Normal	9 (56.2%)	21 (91.4%)		

PDMS-2, Peabody Developmental Motor Scales-2.

*Chi-square test.

**Fisher's exact test, statistical significance ($p < 0.05$).

^vCramer's V.

migration which is essential for the continuation of angiogenic and neurogenic coordination.²⁹

Regarding a potential future systemic effect of IVB in preterm infants, studies have been conducted to evaluate neurodevelopmental status of preterm children following IVB for ROP. Lien *et al.* have found a higher chance of psychomotor impairment in preterm children who received a combination of IVB and laser treatment compared to preterm children who had IVB and laser treatments alone at 2 years of age.¹⁰ The authors attributed this result to higher rate of sedation and anesthesia along with a higher incidence of zone I ROP in preterm infants who had combination treatment. Morin *et al.* have observed lower motor scores in IVB-treated patients than in laser-treated patients, indicating significant neurodevelopmental disabilities in preterm children who received IVB for ROP at 18 months of age.⁹ But in that study, including children with worse stages of ROP and including children with cerebral palsy have been suggested to impact neurodevelopment outcomes. Kennedy *et al.* identified no adverse effect of IVB on neurodevelopmental scores compared to laser treatment at the end of a 2-year follow-up assessment.¹¹ In a small case series study, Martinez-Castellanos *et al.* did not find an apparent deleterious effect of IVB on systemic and neurodevelopmental function in preterm infants by using the Denver Developmental Screening Test II.³⁰ Another study evaluated the two-year neurodevelopmental outcomes of patients with ROP who received IVB as adjunctive therapy using the the Bayley Scales of Infant and Toddler Development III (Bayley III). The authors found that IVB did not contribute to systemic complications other than those already present due to prematurity.³¹ Recently, Fan *et al.* conducted a prospective case-control study to assess neurodevelopmental outcomes after IVB therapy for ROP and found no significant differences of neurodevelopmental function between premature children who had IVB treatment, premature children

with no ROP history and premature children with ROP without treatment between 1 and 3 years of age.³² In another study, Chiang *et al.* did not identify a significant difference of neurodevelopmental function between prematurity without ROP, ROP without treatment, ROP with laser treatment, and ROP with intravitreal anti-VEGF treatment groups. The results showed that intravitreal anti-VEGF treatment for ROP was not associated with adverse neurodevelopment in premature infants.³³ In the study of Çelik *et al.*, it was stated that children treated with bevacizumab with grade 3 and grade 4 intracranial hemorrhage should be carefully monitored for neurodevelopmental problems. This study concluded that the neurodevelopmental outcomes of anti-VEGF therapy applied to infants with postnatal neurological complications should be followed closely.³⁴

In the present study, we ruled out children with systemic, metabolic, and neurologic disorders initially, thus developmental outcomes were evaluated without the influences of such confounding factors. The Beery VMI and PDMS-2 gold standard methods used in neurodevelopment and psychomotor assessment. We observed significantly higher number of children in IVB group having abnormal VMI skill along with abnormal motor skills compared to children in LPC group. These findings suggest retarded VMI and motor development in IVB-treated children when compared to LPC-treated children at 2 to 6 years of age.

Very preterm infants have a variety of neurobehavioral impairments, such as impaired VMI and VP, however the reported results have a wide range. In a meta-analysis reporting the effect of very preterm birth on VP and VMI skills, it was reported that preterm children born with very low BW had moderate to large effect size impairment in visual-spatial skills but not in visual closure perception.³⁵ Molloy *et al.* reported that severe ROP (up to stage 3) was linked to worse results on a variety of neurodevelopmental measures, such as Beery VMI and Bayley III in extremely preterm adolescents.³⁶ Moreover, Petursdottir *et al.* showed differences in VMI scores between a control group of term infants and VLBW infants who had previously undergone ROP screening.¹⁴ Zimmermann *et al.* reported that Beery VMI scores were significantly lower in preterm infants with ROP stages 2 and 3 compared to infants without ROP, and as a result, the negative effect of ROP on VMI skills in preschool age. Interestingly, preterm infants without ROP in that study had almost normal Beery VMI values.¹⁵ In this study, it is noteworthy that the average age of evaluation in the Laser group was made earlier than in the Anti-VEGF group. However, Beery VMI and PDMS-2 are norm-referenced assessment scales. Assessment scores were determined to be “normal” or “abnormal” based on age-dependent normative data. It was determined that low BW children with ROP had impaired VMI, VP, and MC skills. VP abilities and the ability to use visual information to guide motor behavior, called VMI have been found to significantly affect a wide range of adaptive abilities, including motor skills such as handwriting, as well as academic achievement in IVB-treated children with ROP when compared to LPC-treated children at 2–6 years of age.

Prematurity has a damaging effect on visual function with its increasing severity.³⁷ Studies have demonstrated that premature children who received treatment for ROP has limited visual outcomes.^{38,39} In our study, we demonstrated significant differences of visual function between the groups favoring the LPC group. Incidence of abnormal vision was higher in IVB-treated children than in LPC-treated children. These findings suggest better visual performance in children who received LPC treatment in the present cohort. Animal studies have shown that

VEGF plays a key role in functioning of adult retinal neuronal cells as well as maintaining retinal pigment epithelium integrity. The results of these studies indicated that VEGF is required for preservation of the visual function.^{40,41} Importance of visual functional status has been emphasized during neurodevelopmental evaluation in preterm children. Better visual performance significantly predicts motor developmental status.^{42,43} As we observed abnormal visual function in IVB group, this could have a chance to influence motor developmental test scores in the current study.

It has been shown that extreme prematurity, increased severity of ROP and applying laser treatment in ROP induced myopia.⁴⁴ Bevacizumab treatment has been shown to be associated with milder degrees of refractive errors along with a higher chance of having emmetropia.²² The effect of IVB on emmetropization has been hypothesized to be related to continuing expression of local growth factors from peripheral retina.⁴⁵ Our findings regarding refractive status were not consistent with the literature. We could not identify any significant difference of refractive error incidence between IVB and LPC groups at least in this cohort. In our opinion, these results might be due to relatively lower number of subjects in each group and predominantly zone 2 involvement in both IVB and LPC groups.

Premature children with increased severity of ROP have often been sicker newborns during neonatal period suggesting that these children tend to have delayed neurodevelopmental outcomes compared to their age equivalents.⁴⁶ In our study, although we observed no differences of ROP zone and stage between the groups, we identified significantly longer duration of hospitalization in IVB-treated children. This finding was in contrast with that of in the studies by Kennedy *et al.*¹¹ which found shorter hospital stay in IVB group than laser group and Chen *et al.*⁴⁷ which found no significant difference of length of hospital stay between IVB- and laser-treated children during neurodevelopmental assessment. As we could not reach detailed patient records, our finding on hospitalization time might suggest a trend for IVB-treated children to have multiple comorbidity factors such as sepsis, intraventricular hemorrhage, patent ductus arteriosus, increased time of mechanical ventilation and oxygen fluctuation that may have an association with impaired motor developmental scores.⁴⁸ One may find the difference in hospital stays across the present sample suggestive that at least part of the developmental outcome differences observed are likely related to illness level differences between the groups.

The present study has some limitations, including small number of subjects, nonrandomizing the groups and lack of knowledge of multiple comorbid factors during the postnatal hospital period. In addition, outcome times during neurodevelopmental assessment vary between 2 and 6 years when there is likely to have been a significant improvement in function. Furthermore, most reports have used the Bayley III to evaluate neurodevelopmental status in premature children. As we utilized the Beery VMI and PDMS-2 tests, we were not able to identify cognitive, language, social-emotional, and adaptive behavior skills of the children in our study. Nonetheless, these tests have been shown to have higher predictivity and reliability to measure visual motor development and to better reveal motor skills in premature children.^{16,24,49}

Conclusion

In conclusion, significantly lower VMI and motor development features was demonstrated in IVB group than in LPC group

between children 2 and 6 years of age in our study. In this study, the hypothesis that there is a difference in long-term VMI and motor development outcomes between premature infants who have previously received IVB injection and laser therapy is confirmed. Cases treated with IVB had chance to be sicker infants with longer hospital stays, it may therefore not be treatment that was the cause of the development issues but the general level of sickness. Notwithstanding, our results suggest the relevance of IVB injection in impaired motor developmental outcomes in premature children which should be bear in mind. Depending upon visual functional outcomes in our study, we recommend a comprehensive evaluation for IVB-treated children with regard to early physiotherapeutic programs to enhance visual and motor development. Prospective, randomized, case-control, and larger series studies with longer follow-up are needed in order to better ascertain the effect of IVB on neurodevelopment.

Acknowledgments. We thank children, their families, and Asena Ayca Ozdemir who assisted with the statistical analysis.

Financial support. None.

Competing interests. None.

References

- Blencowe H, Lawn JE, Vazquez T, Fielder A, Gilbert C. Preterm-associated visual impairment and estimates of retinopathy of prematurity at regional and global levels for 2010. *Pediatr Res*. 2013; 74(S1), 35–49. DOI: [10.1038/pr.2013.205](https://doi.org/10.1038/pr.2013.205).
- Hartnett ME, Penn JS. Mechanisms and management of retinopathy of prematurity. *N Engl J Med*. 2012; 367(26), 2515–2526. DOI: [10.1056/NEJMra1208129](https://doi.org/10.1056/NEJMra1208129).
- Early Treatment For Retinopathy Of Prematurity Cooperative Group. Revised indications for the treatment of retinopathy of prematurity. *Arch Ophthalmol*. 2003; 121(12), 1684–1694. DOI: [10.1001/archophth.121.12.1684](https://doi.org/10.1001/archophth.121.12.1684).
- Kychenthal A, Dorta P, Katz X. Zone I retinopathy of prematurity: clinical characteristics and treatment outcomes. *Retina*. 2006; 26(7 Suppl), S11–S15. DOI: [10.1097/01.iae.0000244285.79004.e6](https://doi.org/10.1097/01.iae.0000244285.79004.e6).
- Travassos A, Teixeira S, Ferreira P, et al. Intravitreal bevacizumab in aggressive posterior retinopathy of prematurity. *Ophthalmic Surg Lasers Imaging*. 2007; 38(3), 233–237. DOI: [10.3928/15428877-20070501-09](https://doi.org/10.3928/15428877-20070501-09).
- Wu WC, Yeh PT, Chen SN, Yang CM, Lai CC, Kuo HK. Effects and complications of bevacizumab use in patients with retinopathy of prematurity: a multicenter study in taiwan. *Ophthalmology*. 2011; 118(1), 176–183. DOI: [10.1016/j.ophtha.2010.04.018](https://doi.org/10.1016/j.ophtha.2010.04.018).
- Mintz-Hittner HA, Kennedy KA, Chuang AZ. Efficacy of intravitreal bevacizumab for stage 3+ retinopathy of prematurity. *N Engl J Med*. 2011; 364(7), 603–615. DOI: [10.1056/NEJMoa1007374](https://doi.org/10.1056/NEJMoa1007374).
- Malik S, Vinukonda G, Vose LR, et al. Neurogenesis continues in the third trimester of pregnancy and is suppressed by premature birth. *J Neurosci*. 2013; 33(2), 411–423. DOI: [10.1523/JNEUROSCI.4445-12.2013](https://doi.org/10.1523/JNEUROSCI.4445-12.2013).
- Morin J, Luu TM, Superstein R, et al. Neurodevelopmental outcomes following bevacizumab injections for retinopathy of prematurity. *Pediatrics*. 2016; 137(4), e20153218. DOI: [10.1542/peds.2015-3218](https://doi.org/10.1542/peds.2015-3218).
- Lien R, Yu MH, Hsu KH, et al. Neurodevelopmental outcomes in infants with retinopathy of prematurity and bevacizumab treatment. *PLoS One*. 2016; 11(1), e0148019. DOI: [10.1371/journal.pone.0148019](https://doi.org/10.1371/journal.pone.0148019).
- Kennedy KA, Mintz-Hittner HA. Medical and developmental outcomes of bevacizumab versus laser for retinopathy of prematurity. *J AAPOS*. 2018; 22(1), 61–65.e1. DOI: [10.1016/j.jaapos.2017.10.006](https://doi.org/10.1016/j.jaapos.2017.10.006).
- Tsai CY, Yeh PT, Tsao PN, Chung YE, Chang YS, Lai TT. Neurodevelopmental outcomes after bevacizumab treatment for retinopathy of prematurity: a meta-analysis. *Ophthalmology*. 2021; 128(6), 877–888. DOI: [10.1016/j.ophtha.2020.11.012](https://doi.org/10.1016/j.ophtha.2020.11.012).
- Tan H, Blasco P, Lewis T, Ostmo S, Chiang MF, Campbell JP. Neurodevelopmental outcomes in preterm infants with retinopathy of prematurity. *Surv Ophthalmol*. 2021; 66(5), 877–891. DOI: [10.1016/j.survophthal.2021.02.012](https://doi.org/10.1016/j.survophthal.2021.02.012).
- Pétursdóttir D, Holmström G, Larsson E, Böhm B. Visual-motor functions are affected in young adults who were born premature and screened for retinopathy of prematurity. *Acta Paediatr*. 2021; 110(1), 127–133. DOI: [10.1111/apa.15378](https://doi.org/10.1111/apa.15378).
- Zimmermann DL, Schned H, Unterasinger L, et al. Impact of retinopathy of prematurity on visual motor integration. *Neonatology*. 2023; 1-8(3), 317–324. DOI: [10.1159/000529594](https://doi.org/10.1159/000529594).
- Beery KE, Beery NA. *The Beery-Buktenica Developmental Test of Visual-motor Integration (Beery VMI) with Supplemental Developmental Tests of Visual Perception and Motor Coordination and Stepping Stones Age Norms: Administration, Scoring and Teaching Manual*, 2010. NCS Pearson, Minneapolis, MN.
- Dankert HL, Davies PL, Gavin WJ. Occupational therapy effects on visual-motor skills in preschool children. *Am J Occup Ther*. 2003; 57(5), 542–549. DOI: [10.5014/ajot.57.5.542](https://doi.org/10.5014/ajot.57.5.542).
- Section on Ophthalmology American Academy of Pediatrics American Academy of Ophthalmology American Association for Pediatric Ophthalmology and Strabismus. Screening examination of premature infants for retinopathy of prematurity. *Pediatrics*. 2006; 118(3), 1324–1576. DOI: [10.1542/peds.2005-2749](https://doi.org/10.1542/peds.2005-2749).
- International Committee for the Classification of Retinopathy of Prematurity. The international classification of retinopathy of prematurity revisited. *Arch Ophthalmol*. 2005; 123(7), 991–999. DOI: [10.1001/archophth.123.7.991](https://doi.org/10.1001/archophth.123.7.991).
- Cieza A, Keel S, Kocur I, Mccoy M, Mariotti SP. *World Report On Vision*, 2019. World Health Organization, Geneva.
- Quinn GE, Dobson V, Davitt BV, et al. Progression of myopia and high myopia in the early treatment for retinopathy of prematurity study: findings at 4 to 6 years of age. *J Am Assoc Pediatr Ophthalmol Strabismus*. 2013; 17(2), 124–128. DOI: [10.1016/j.jaapos.2012.10.025](https://doi.org/10.1016/j.jaapos.2012.10.025).
- Geloneck MM, Chuang AZ, Clark WL, et al. Refractive outcomes following bevacizumab monotherapy compared with conventional laser treatment: a randomized clinical trial. *JAMA Ophthalmol*. 2014; 132(11), 1327–1333. DOI: [10.1001/jamaophthalmol.2014.2772](https://doi.org/10.1001/jamaophthalmol.2014.2772).
- Rhonda Folio M, Rebecca RF. *Peabody Developmental Motor Scales-2 (PDMS-2) Examiner Manual Second Edition*, 2000. Austin, Texas: Published by Pro-ed.
- Wang HH, Liao HF, Hsieh CL. Reliability, sensitivity to change, and responsiveness of the peabody developmental motor scales-second edition for children with cerebral palsy. *Phys Ther*. 2006; 86(10), 1351–1359. DOI: [10.2522/ptj.20050259](https://doi.org/10.2522/ptj.20050259).
- Beligere N, Perumalswamy V, Tandon M, et al. Retinopathy of prematurity and neurodevelopmental disabilities in premature infants. *Semin Fetal Neonatal Med*. 2015; 20(5), 346–353. DOI: [10.1016/j.siny.2015.06.004](https://doi.org/10.1016/j.siny.2015.06.004).
- VanderVeen DK, Melia M, Yang MB, Hutchinson AK, Wilson LB, Lambert SR. Anti-vascular endothelial growth factor therapy for primary treatment of Type 1 retinopathy of prematurity: a report by the American academy of ophthalmology. *Ophthalmology*. 2017; 124(5), 619–633. DOI: [10.1016/j.ophtha.2016.12.025](https://doi.org/10.1016/j.ophtha.2016.12.025).
- Kong L, Bhatt AR, Demny AB, et al. Pharmacokinetics of bevacizumab and its effects on serum VEGF and IGF-1 in infants with retinopathy of prematurity. *Invest Ophthalmol Vis Sci*. 2015; 56(2), 956–961. DOI: [10.1167/iovs.14-15842](https://doi.org/10.1167/iovs.14-15842).
- Rosenstein JM, Krum JM, Ruhrberg C. VEGF in the nervous system. *Organogenesis*. 2010; 6(2), 107–114. DOI: [10.4161/org.6.2.11687](https://doi.org/10.4161/org.6.2.11687).
- Mani N, Khaibullina A, Krum JM, Rosenstein JM. Vascular endothelial growth factor enhances migration of astroglial cells in subventricular zone neurosphere cultures. *J Neurosci Res*. 2010; 88(2), 248–257. DOI: [10.1002/jnr.22197](https://doi.org/10.1002/jnr.22197).
- Martínez-Castellanos MA, Schwartz S, Hernández-Rojas ML, et al. Long-term effect of antiangiogenic therapy for retinopathy of prematurity up to 5 years of follow-up. *Retina*. 2013; 33(2), 329–338. DOI: [10.1097/IAE.0b013e318275394a](https://doi.org/10.1097/IAE.0b013e318275394a).

31. Araz-Ersan B, Kir N, Tuncer S, *et al.* Preliminary anatomical and neurodevelopmental outcomes of intravitreal bevacizumab as adjunctive treatment for retinopathy of prematurity. *Curr Eye Res.* 2015; 40(6), 585–591. DOI: [10.3109/02713683.2014.941070](https://doi.org/10.3109/02713683.2014.941070).
32. Fan YY, Huang YS, Huang CY, *et al.* Neurodevelopmental outcomes after intravitreal bevacizumab therapy for retinopathy of prematurity: a prospective case-control study. *Ophthalmology.* 2019; 126(11), 1567–1577. DOI: [10.1016/j.ophtha.2019.03.048](https://doi.org/10.1016/j.ophtha.2019.03.048).
33. Chiang MC, Chen YT, Kang EY, *et al.* Neurodevelopmental outcomes for retinopathy of prematurity: a Taiwan premature infant follow-up network database study. *Am J Ophthalmol.* 2023; 247, 170–180. DOI: [10.1016/j.ajo.2022.10.020](https://doi.org/10.1016/j.ajo.2022.10.020).
34. Celik P, Ayranci Sucakli I, Kara C, *et al.* Bevacizumab and neurodevelopmental outcomes of preterm infants with retinopathy of prematurity: should we still worry? *J Matern Fetal Neonatal Med.* 2022; 35(3), 415–422. DOI: [10.1080/14767058.2021.1888913](https://doi.org/10.1080/14767058.2021.1888913).
35. Geldof CJ, van Wassenae AG, de Kieviet JF, Kok JH, Oosterlaan J. Visual perception and visual-motor integration in very preterm and/or very low birth weight children: a meta-analysis. *Res Dev Disabil.* 2012; 33(2), 726–736. DOI: [10.1016/j.ridd.2011.08.025](https://doi.org/10.1016/j.ridd.2011.08.025).
36. Molloy CS, Anderson PJ, Anderson VA, Doyle LW. The long-term outcome of extremely preterm (<28 weeks' gestational age) infants with and without severe retinopathy of prematurity. *J Neuropsychol.* 2016; 10(2), 276–294. DOI: [10.1111/jnp.12069](https://doi.org/10.1111/jnp.12069).
37. Fielder A, Blencowe H, O'Connor A, Gilbert C. Impact of retinopathy of prematurity on ocular structures and visual functions. *Arch Dis Child Fetal Neonatal Ed.* 2015; 100(2), F179–F184. DOI: [10.1136/archdischild-2014-306207](https://doi.org/10.1136/archdischild-2014-306207).
38. Anilkumar SE, Anandi V, Shah PK, Ganesh S, Narendran K. Refractive, sensory, and biometric outcome among retinopathy of prematurity children with a history of laser therapy: a retrospective review from a tertiary care center in South India. *Indian J Ophthalmol.* 2019; 67(6), 871–876. DOI: [10.4103/ijo.IJO_2023_18](https://doi.org/10.4103/ijo.IJO_2023_18).
39. Ng EY, Connolly BP, McNamara JA, Regillo CD, Vander JF, Tasman W. A comparison of laser photocoagulation with cryotherapy for threshold retinopathy of prematurity at 10 years. *Ophthalmology.* 2002; 109(5), 928–935. DOI: [10.1016/s0161-6420\(01\)01017-x](https://doi.org/10.1016/s0161-6420(01)01017-x).
40. Saint-Geniez M, Maharaj AS, Walshe TE, *et al.* Endogenous VEGF is required for visual function: evidence for a survival role on müller cells and photoreceptors. *PLoS One.* 2008; 3(11), e3554. DOI: [10.1371/journal.pone.0003554](https://doi.org/10.1371/journal.pone.0003554).
41. Ford KM, Saint-Geniez M, Walshe T, Zahr A, D'Amore PA. Expression and role of VEGF in the adult retinal pigment epithelium. *Invest Ophthalmol Vis Sci.* 2011; 52(13), 9478–9487. DOI: [10.1167/iov.11-8353](https://doi.org/10.1167/iov.11-8353).
42. Pinello L, Manea S, Visonà Dalla Pozza L, Mazzarolo M, Facchin P. Visual, motor, and psychomotor development in small-for-gestational-age preterm infants. *J AAPOS.* 2013; 17(4), 352–356. DOI: [10.1016/j.jaapos.2013.03.026](https://doi.org/10.1016/j.jaapos.2013.03.026).
43. van Veen S, van Wassenae-Leemhuis AG, van Kaam AH, Oosterlaan J, Aarnoudse-Moens CSH. Visual perceptive skills account for very preterm children's mathematical difficulties in preschool. *Early Hum Dev.* 2019; 129, 11–15. DOI: [10.1016/j.earlhumdev.2018.12.018](https://doi.org/10.1016/j.earlhumdev.2018.12.018).
44. Kaya M, Berk AT, Yaman A. Long-term evaluation of refractive changes in eyes of preterm children: a 6-year follow-up study. *Int Ophthalmol.* 2018; 38(4), 1681–1688. DOI: [10.1007/s10792-017-0642-z](https://doi.org/10.1007/s10792-017-0642-z).
45. Mintz-Hittner HA, Geloneck MM. Review of effects of anti-VEGF treatment on refractive error. *Eye Brain.* 2016; 8, 135–140. DOI: [10.2147/EB.S99306](https://doi.org/10.2147/EB.S99306).
46. Goyen TA, Todd DA, Veddovi M, Wright AL, Flaherty M, Kennedy J. Eye-hand co-ordination skills in very preterm infants < 29 weeks gestation at 3 years: effects of preterm birth and retinopathy of prematurity. *Early Hum Dev.* 2006; 82(11), 739–745. DOI: [10.1016/j.earlhumdev.2006.02.011](https://doi.org/10.1016/j.earlhumdev.2006.02.011).
47. Chen TA, Schachar IH, Moshfeghi DM. Outcomes of intravitreal bevacizumab and diode laser photocoagulation for treatment-warranted retinopathy of prematurity. *Ophthalmic Surg Lasers Imaging Retina.* 2018; 49(2), 126–131. DOI: [10.3928/23258160-20180129-07](https://doi.org/10.3928/23258160-20180129-07).
48. Stoll BJ, Hansen NI, Bell EF, *et al.* Neonatal outcomes of extremely preterm infants from the NICHD neonatal research network. *Pediatrics.* 2010; 126(3), 443–456. DOI: [10.1542/peds.2009-2959](https://doi.org/10.1542/peds.2009-2959).
49. Sutton GP, Barchard KA, Bello DT, *et al.* Beery-Buktenica developmental test of visual-motor integration performance in children with traumatic brain injury and attention-deficit/hyperactivity disorder. *Psychol Assess.* 2011; 23(3), 805–809. DOI: [10.1037/a0023370](https://doi.org/10.1037/a0023370).