

## Review

\*These authors equally contributed as the first author.

**Cite this article:** Abdoli A, Maspi N, Ghaffarifar F, Nasiri V (2018). Viscerotropic leishmaniasis: a systematic review of the case reports to highlight spectrum of the infection in endemic countries. *Parasitology Open* 4, e11, 1–14. <https://doi.org/10.1017/pao.2018.9>

Received: 26 December 2017

Revised: 1 March 2018

Accepted: 2 March 2018

**Key words:**

Case reports; cutaneous leishmaniasis; *Leishmania tropica*; systematic review; visceral leishmaniasis; viscerotropic leishmaniasis

**Author for correspondence:**

Amir Abdoli, E-mail: [a.abdoli@modares.ac.ir](mailto:a.abdoli@modares.ac.ir); [a.abdoli25@gmail.com](mailto:a.abdoli25@gmail.com) and Nahid Maspi, E-mail: [n.maspi@modares.ac.ir](mailto:n.maspi@modares.ac.ir); [nmaspi82@gmail.com](mailto:nmaspi82@gmail.com)

# Viscerotropic leishmaniasis: a systematic review of the case reports to highlight spectrum of the infection in endemic countries

Amir Abdoli<sup>1\*</sup>, Nahid Maspi<sup>2\*</sup>, Fatemeh Ghaffarifar<sup>1</sup> and Vahid Nasiri<sup>3</sup>

<sup>1</sup>Department of Parasitology, Faculty of Medical Sciences, Tarbiat Modares University, Tehran, Iran; <sup>2</sup>Department of Parasitology, Faculty of Paramedicine, Ilam University of Medical Sciences, Ilam, Iran and <sup>3</sup>Department of Parasitology, Razi Vaccine and Serum Research Institute, Karaj, Alborz, Iran

**Abstract**

Visceral leishmaniasis is an important neglected parasitic disease that is generally caused by *Leishmania infantum*, *Leishmania donovani* and *Leishmania chagasi*. However, several causative species of cutaneous leishmaniasis (CL) causes an interstitial form of leishmaniasis which known viscerotropic leishmaniasis. The aim of this paper is a systematic review of the cases of viscerotropic leishmaniasis to present the main causative agents, clinical manifestations, treatment and outcomes of the cases. An electronic search (any date to August 2017) without language restrictions was performed using Medline, PubMed, Scopus and Google Scholar. The searches identified 19 articles with total 30 case reports. Of them, old world *Leishmania* species was reported from 23 (76.7%) cases, including 20 cases of *L. tropica* and three cases of *L. major*; whereas new world *Leishmania* species were reported in seven (23.4%) cases. The infection was more prevalent in male (24/30, 80%) than female (5/30, 16.7%) patients. Co-morbidity/co-infection was observed in 13 out of 30 cases (43.4%), which the most of them was HIV/AIDS (10 out of 13 cases, 76.9%). The results suggested that viscerotropic leishmaniasis should be more attended in the endemic countries of CL and in immunocompromised patients in order to exact discrimination from other endemic infectious diseases.

**Introduction**

Leishmaniasis is a neglected tropical disease with a broad global distribution (Murray et al. 2005). The main clinical forms of leishmaniasis are visceral leishmaniasis (VL), cutaneous leishmaniasis (CL) and mucocutaneous leishmaniasis (MCL) (Murray et al. 2005). The disease has infected 12 million people worldwide and is endemic in 88 countries (Alvar et al. 2012). According to estimation, the annual incidence of CL and VL are 0.7–1.2 and 0.2–0.4 million new cases, respectively, with mortality rates of 20 000–40 000 cases (Alvar et al. 2012).

The causative agents of VL are four species of the genus *Leishmania*, including *L. infantum*, *L. donovani* and *L. archibaldi* in the old world (i.e. Europe, Asia and Africa) and *L. chagasi* in the New World (i.e. the American) (Guerin et al. 2002; Quinnell and Courtenay, 2009). However, in the new classification, clinically and epidemiologically VL is divided into two main forms: (1) zoonotic visceral leishmaniasis (ZVL) caused by *L. infantum* that occurs in Asia, North Africa, Europe, South and Central America. ZVL affects mainly young children and the domestic dogs are its principal reservoirs. (2) Anthroponotic visceral leishmaniasis (AVL) caused by *L. donovani* exists in India, parts of the Middle East and East Africa. AVL affects people of all ages and transmits from human to human by infected sand fly bite (Choi and Lerner, 2001; Lukeš et al. 2007; Quinnell and Courtenay, 2009). CL is caused by *L. tropica*, *L. major* and *L. aethiopica* in the old world and *L. braziliensis*, *L. mexicana*, *L. amazonensis*, *L. guyanensis* and *L. panamensis* in the new world (Murray et al. 2005; Alvar et al. 2012; McGwire and Satoskar, 2014). Also, *L. braziliensis* is a causative agent of MCL in the new world (McGwire and Satoskar, 2014). However, an interstitial form of leishmaniasis, which known as viscerotropic leishmaniasis is caused by main causative agents of CL, in particular *L. tropica* and *L. mexicana* (Barral et al. 1986; Sacks et al. 1995; Monroy-Ostria et al. 2000; Choi and Lerner, 2001; Weiss et al. 2009). Viscerotropic leishmaniasis clinically differs from VL. VL causes signs and symptoms including fever, splenomegaly, lymphadenopathy, emaciation, pancytopenia and hyperglobulinaemia, while viscerotropic leishmaniasis causes non-specific symptoms including high fever, malaise, intermittent diarrhoea and abdominal pain without the classic signs or symptoms of VL (Barral et al. 1986; Sacks et al. 1995; Monroy-Ostria et al. 2000; Choi and Lerner, 2001; Weiss et al. 2009). Hence, we performed a systematic review of the cases of viscerotropic leishmaniasis to present the main causative agents and clinical appearance of the diseases.

**Materials and methods**

An electronic search without language restrictions was performed using Medline, PubMed, Scopus and Google Scholar (any date to August 2017). The search was conducted according to the Preferred Reporting Items for Systematic reviews and Meta-Analyses (PRISMA)

© Cambridge University Press 2018. This is an Open Access article, distributed under the terms of the Creative Commons Attribution licence (<http://creativecommons.org/licenses/by/4.0/>), which permits unrestricted re-use, distribution, and reproduction in any medium, provided the original work is properly cited

**Table 1.** Search strategy and terms used to identify studies on visceral leishmaniasis due to different *Leishmania* species

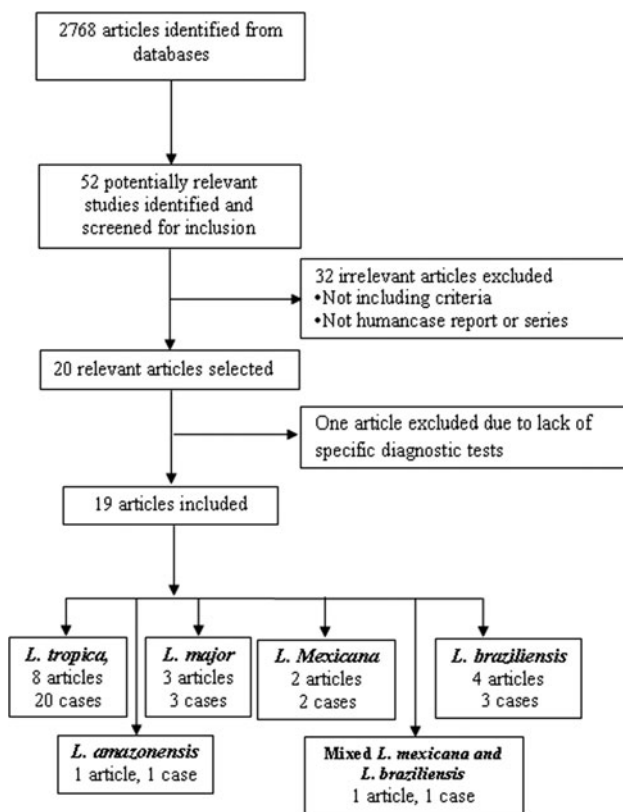
Term	1. <i>Leishmania tropica</i> , 2. <i>Leishmania major</i> , 3. <i>Leishmania braziliensis</i> , 4. <i>Leishmania mexicana</i> , 5. <i>Leishmania amazonensis</i> 6. Visceral, 7. Viscerotropic, 8. Disseminated, 9. Systemic, 10. HIV, 11. AIDS, 12. Immunodeficiency, 13. Immunocompromised.
Strategy	1 OR 2 OR 3 OR 4 OR 5 AND 6 OR 7 OR 8 OR 9 OR 10 OR 11 OR 12 OR 13

statement (Moher et al. 2015). The terms and search strategy are described in Table 1. All titles, abstracts and full texts from each of the searches were examined and reviewed. The search was limited to literatures on humans. Moreover, all selected references were hand-searched for other relevant articles or their citations in Google Scholar. Data selection was also performed after removing duplications by Endnote software (Kwon et al. 2015). Articles were considered eligible for inclusion if they involved case reports or case series of patients with VL who infected with one of *Leishmania* species that regularly causing CL. Also, an article was selected if it reports details of diagnostic tests (e.g. molecular methods or isoenzyme identification) or relevant evidence to confirm the species of *Leishmania* parasite.

## Results

The search identified 52 relevant studies after removing duplicates. Finally, 19 out of the 52 articles met the inclusion criteria (Fig. 1). (Mebrantu et al. 1989; Hernández et al. 1993, 1995a, b; Magill et al. 1993; Sacks et al. 1995; Hanly et al. 1998; Ramos-Santos et al. 2000; Gontijo et al. 2002; Silva et al. 2002; Alborzi et al. 2006, 2008; Aleixo et al. 2006; Karamian et al. 2007; Weiss et al. 2009; Jafari et al. 2010; Mestra et al. 2011; Shafiei et al. 2014; Bamorovat et al. 2015).

The articles describing the history of 30 human cases (Tables 2–5). One article was excluded because the study was retrospectively

**Fig. 1.** Flow of diagram through the different phases of the review.**Table 2.** The number of cases that reported from endemic regions

<i>Leishmania</i> species	Iran	Saudi Arabia	India	Kenya	Afghanistan	Burkina Faso	Brazil	Venezuela	Colombia	Mexico	Total
Old world											
<i>L. tropica</i>	5	8 <sup>a</sup>	4	2	1 <sup>b</sup>						20
<i>L. major</i>	2					1					3
New world											
<i>L. braziliensis</i>							2	1 <sup>c</sup>			3
<i>L. mexicana</i>									1	1	2
<i>L. amazonensis</i>							1				1
Mixed <i>L. braziliensis</i> and <i>L. mexicana</i>								1			1
Total	7	8	4	2	1	1	3	2	1	1	30

<sup>a</sup>Indicated American soldier return from Saudi Arabia.

<sup>b</sup>Indicated an Afghani girl who lived in the USA.

<sup>c</sup>Indicated an Italian man living in Venezuela.

**Table 3.** Visceral leishmaniasis caused by *Leishmania tropica* in human

Sex, age, country, year of case report and ref	Co-morbidity or co-infection	Symptoms	Cutaneous lesion	Diagnostic method	Treatment	Outcome
<ul style="list-style-type: none"> <li>• Male, age was not reported</li> <li>• American soldier who returned from operation desert storm in Saudi Arabia, 1990–1992 (Dillon et al. 1995; Magill et al. 1993)</li> </ul>	No	<ul style="list-style-type: none"> <li>• Adenopathy</li> <li>• Fever</li> <li>• Abdominal pain++</li> <li>• Malaise+</li> <li>• Fatigue++</li> <li>• Hepatosplenomegaly</li> <li>• Headache</li> <li>• Non-productive cough</li> </ul>	No	<ul style="list-style-type: none"> <li>• –Positive antibody to <i>Leishmania</i> by IFA assay</li> <li>• Amastigote in bone-marrow (BM) aspiration</li> <li>• Promastigote in culture of BM aspirates</li> <li>• Enzyme-linked immunosorbent assay (ELISA) with recombinant <i>L. tropica</i> antigens</li> <li>• Isoenzyme analysis</li> </ul>	Responded to sodium antimony gluconate	Signs and symptoms resolved after treatment
<ul style="list-style-type: none"> <li>• Male, 39 years</li> <li>• American soldier who returned from operation desert storm in Saudi Arabia, 1990–1992 (Dillon et al. 1995; Magill et al. 1993)</li> </ul>	No	<ul style="list-style-type: none"> <li>• Fever</li> <li>• Abdominal pain+</li> <li>• Malaise++</li> <li>• Fatigue+</li> <li>• Headache</li> <li>• Non-productive cough</li> </ul>	No	<ul style="list-style-type: none"> <li>• Positive antibody to <i>Leishmania</i> by IFA assay</li> <li>• Amastigote in BM aspiration</li> <li>• Promastigote in culture of BM aspirates</li> <li>• Enzyme-linked immunosorbent assay (ELISA) with recombinant <i>L. tropica</i> antigens</li> <li>• Isoenzyme analysis</li> </ul>	Responded to sodium antimony gluconate	Signs and symptoms resolved after treatment
<ul style="list-style-type: none"> <li>• Male, 20 years</li> <li>• American soldier who returned from operation desert storm in Saudi Arabia, 1990–1992 (Dillon et al. 1995; Magill et al. 1993)</li> </ul>	No	<ul style="list-style-type: none"> <li>• Gastroenteritis</li> <li>• Without fever</li> <li>• Abdominal pain+++</li> <li>• Malaise+++</li> <li>• Fatigue+</li> <li>• Splenomegaly</li> </ul>	No	<ul style="list-style-type: none"> <li>• Positive antibody to <i>Leishmania</i> by IFA assay</li> <li>• Amastigote in BM aspiration</li> <li>• Promastigote in culture of BM aspirates</li> <li>• Enzyme-linked immunosorbent assay (ELISA) with recombinant <i>L. tropica</i> antigens</li> <li>• Isoenzyme analysis</li> </ul>	Responded to sodium antimony gluconate	Signs and symptoms resolved after treatment
Male, age was not reported American soldier who returned from operation desert storm in Saudi Arabia, 1990–1992 (Dillon et al. 1995; Magill et al. 1993)	No	Without symptoms	No	<ul style="list-style-type: none"> <li>• Positive antibody to <i>Leishmania</i> by IFA assay</li> <li>• Amastigote in BM aspiration</li> <li>• Promastigote in culture of BM aspirates</li> <li>• Enzyme-linked immunosorbent assay (ELISA) with recombinant <i>L. tropica</i> antigens</li> <li>• Isoenzyme analysis</li> </ul>	No treatment was recommended	No symptoms after 18 months of follow-up

(Continued)

Table 3. (Continued.)

Sex, age, country, year of case report and ref	Co-morbidity or co-infection	Symptoms	Cutaneous lesion	Diagnostic method	Treatment	Outcome
Male, age was not reported American soldier who returned from operation desert storm in Saudi Arabia, 1990–1992 (Dillon et al. 1995; Magill et al. 1993)	No	<ul style="list-style-type: none"> <li>Chronic fatigue</li> <li>Hepatosplenomegaly</li> <li>Fever</li> <li>Abdominal pain+</li> <li>Malaise+</li> <li>Fatigue+++</li> <li>Headache</li> <li>Non-productive cough</li> </ul>	No	<ul style="list-style-type: none"> <li>Positive antibody to <i>Leishmania</i> by IFA assay</li> <li>Amastigote in BM aspiration</li> <li>Promastigote in culture of BM aspirates</li> <li>Enzyme-linked immunosorbent assay (ELISA) with recombinant <i>L. tropica</i> antigens</li> <li>Isoenzyme analysis</li> </ul>	Responded to sodium antimony gluconate	<ul style="list-style-type: none"> <li>Sever thrombocytopenia developed after treatment and the drug was discontinued after 18 days.</li> <li>Signs and symptoms resolved after treatment</li> </ul>
Male, 35 years American soldier who returned from operation desert storm in Saudi Arabia, 1990–1992 (Magill et al. 1993; Dillon et al. 1995)	No	<ul style="list-style-type: none"> <li>Chronic fatigue</li> <li>Hepatosplenomegaly</li> <li>Adenopathy</li> <li>Without fever</li> <li>Abdominal pain+</li> <li>Malaise+</li> <li>Fatigue+++</li> <li>Headache</li> <li>Non-productive cough</li> </ul>	No	<ul style="list-style-type: none"> <li>Positive antibody to <i>Leishmania</i> by IFA assay</li> <li>Absence of amastigote in BM and liver biopsy</li> <li>Detection of amastigote in lymph node biopsy</li> <li>Positive promastigote in lymph node culture</li> <li>Enzyme-linked immunosorbent assay (ELISA) with recombinant <i>L. tropica</i> antigens</li> <li>Isoenzyme analysis</li> </ul>	Not responded to sodium antimony gluconate	Remained symptomatic
Male, age was not reported American soldier who returned from operation desert storm in Saudi Arabia, 1990–1992 (Magill et al. 1993; Dillon et al. 1995)	HIV	<ul style="list-style-type: none"> <li>Mononucleosis like symptoms</li> <li>Fever</li> <li>Abdominal pain+/-</li> <li>Malaise+++</li> <li>Fatigue+</li> <li>Headache</li> <li>Non-productive cough</li> </ul>	No	<ul style="list-style-type: none"> <li>Positive antibody to <i>Leishmania</i> by IFA assay</li> <li>Amastigote in BM aspiration</li> <li>Promastigote in culture of BM aspirates</li> <li>Positive antibody to <i>Leishmania</i> by IFA assay</li> <li>Amastigote in BM aspiration</li> <li>Enzyme-linked immunosorbent assay (ELISA) with recombinant <i>L. tropica</i> antigens</li> <li>Isoenzyme analysis</li> </ul>	Responded to sodium antimony gluconate	<ul style="list-style-type: none"> <li>Sever thrombocytopenia developed after treatment and the drug was discontinued after 8 days.</li> <li>Signs and symptoms resolved after treatment</li> </ul>
Male, age was not reported American soldier who returned from operation desert storm in Saudi Arabia, 1990–1992 (Magill et al. 1993)	Renal carcinoma	<ul style="list-style-type: none"> <li>Fever</li> <li>Abdominal pain+</li> <li>Malaise++</li> <li>Fatigue++</li> <li>Hepatosplenomegaly</li> </ul>	No		Not treated with sodium antimony gluconate	Remained symptomatic with fatigue, malaise, non-productive cough and low-grade fever 14 months after nephrectomy

Male, 32 years Iran, 2003 (Jafari et al. 2010)	<ul style="list-style-type: none"> <li>• HIV (CD4 count was 180/mm<sup>3</sup>)</li> <li>• Intravenous drug user</li> <li>• HCV</li> <li>• Pulmonary tuberculosis</li> </ul>	<ul style="list-style-type: none"> <li>• Disseminated leishmaniasis with BM involvement</li> <li>• Many non-ulcerative leproid nodules</li> </ul>	Leproid nodules	<ul style="list-style-type: none"> <li>• Negative serological tests (DAT, IFA, rK39 dipstick)</li> <li>• Negative blood culture</li> <li>• Positive amastigote in BM aspiration</li> <li>• Positive promastigote in BM culture</li> <li>• Positive amastigote in skin lesions by direct microscopic examination</li> <li>• <i>L. tropica</i> identified by PCR-RFLP and RAPD-PCR</li> </ul>	<ul style="list-style-type: none"> <li>• Glucantime</li> <li>• Antiretroviral drugs (zidovudine, lamivudine, nelfinavir) plus an antituberculosis regimen</li> </ul>	<ul style="list-style-type: none"> <li>• Improvement of skin lesions</li> <li>• CD4 count increased 300/mm<sup>3</sup> after treatment</li> </ul>
Male, 49 years Iran, 2006 (Jafari et al. 2010)	<ul style="list-style-type: none"> <li>• HIV (CD4 count was 180/mm<sup>3</sup>)</li> <li>• Intravenous drug user</li> </ul>	<ul style="list-style-type: none"> <li>• Disseminated leishmaniasis with BM involvement</li> <li>• Multiple, small, mobile lymph nodes</li> <li>• Mild splenomegaly</li> <li>• A few small lymph nodes in the liver hilum and paraceliac area</li> </ul>	Multiple skin lesions	<ul style="list-style-type: none"> <li>• Positive anti <i>-Leishmania</i> antibodies (DAT, IFA, rK39 dipstick)</li> <li>• Positive amastigote in BM aspiration and skin biopsy</li> <li>• Positive promastigote culture of BM</li> <li>• Abdominal sonography</li> <li>• <i>L. tropica</i> identified by PCR-RFLP and RAPD-PCR</li> </ul>	<ul style="list-style-type: none"> <li>• Glucantime</li> <li>• Antiretroviral drugs (zidovudine, lamivudine, nelfinavir) plus an antituberculosis regimen</li> </ul>	<ul style="list-style-type: none"> <li>• Improvement of skin lesions</li> <li>• CD4 count increased 210/mm<sup>3</sup> after treatment</li> </ul>
Female, 15 years Southern Iran, 2005 (Alborzi et al. 2008)	No	<ul style="list-style-type: none"> <li>• Multiple papulonodular lesions</li> <li>• Hepatosplenomegaly</li> <li>• Multiple intra-abdominal lymph nodes</li> </ul>	Papulonodular lesions	<ul style="list-style-type: none"> <li>• Amastigote in skin lesions</li> <li>• Promastigote in culture of skin lesion biopsy</li> <li>• Positive anti-<i>Leishmania</i> antibody in IFA</li> <li>• Positive leishmanin skin test (LST)</li> <li>• Positive PCR on BM aspirate, skin lesions and whole blood</li> <li>• <i>L. tropica</i> identified by isoenzyme analysis</li> </ul>	<ul style="list-style-type: none"> <li>• Treatment failure with meglumine antimoniate</li> <li>• Unresponse to amphotericin B</li> <li>• Unresponse to a 4-month course of meglumine antimoniate and IFN-<math>\gamma</math></li> <li>• Response to miltefosine after 28 days</li> </ul>	<ul style="list-style-type: none"> <li>• Significant decrease in the size of liver and spleen</li> <li>• Improvement of skin lesions</li> </ul>
Sex and age were not reported. Southern Iran, 2006 (Alborzi et al. 2006)	Not reported	Not reported	Not reported	<ul style="list-style-type: none"> <li>• Amastigote in spleen puncture by direct microscopy</li> <li>• <i>L. tropica</i> identified by PCR</li> </ul>	Not reported	Not reported

(Continued)

**Table 3.** (Continued.)

Sex, age, country, year of case report and ref	Co-morbidity or co-infection	Symptoms	Cutaneous lesion	Diagnostic method	Treatment	Outcome
Male, 50 years Southwest of Iran (Kohgiluyeh va Boyer-Ahmad) 2015 (Sarkari et al. 2016).	No	<ul style="list-style-type: none"> <li>• Fever</li> <li>• Splenomegaly</li> </ul>	No	<ul style="list-style-type: none"> <li>• Amastigote in spleen biopsy</li> <li>• Serological tests</li> <li>• <i>L. tropica</i> identified by PCR</li> </ul>	Sodium stibogluconate	Complete resolution of symptoms
Male, 8 years India (Vaishali), 1984 (Sacks et al. 1995)	No	<ul style="list-style-type: none"> <li>• Malaise</li> <li>• Fever</li> <li>• Weight loss</li> <li>• Hepatosplenomegaly</li> <li>• Anaemia</li> <li>• Leucopenia</li> </ul>	No	<ul style="list-style-type: none"> <li>• Positive amastigote in BM aspiration</li> <li>• Promastigote in culture of BM aspiration</li> <li>• <i>L. tropica</i> identified by PCR, isoenzymes AND monoclonal antibody</li> </ul>	<ul style="list-style-type: none"> <li>• Unresponsiveness to sodium antimony gluconate</li> <li>• Responded to intramuscular pentamidine for 15–20 days</li> </ul>	<ul style="list-style-type: none"> <li>• Improvement in symptoms</li> <li>• Decrease in splenomegaly</li> <li>• Absence of parasites in repeat BM aspirates</li> </ul>
Male, 13 years India (Vaishali), 1990–92 (Sacks et al. 1995)	No	<ul style="list-style-type: none"> <li>• Malaise</li> <li>• Fever</li> <li>• Weight loss</li> <li>• Hepatosplenomegaly</li> <li>• Anaemia</li> <li>• Leucopenia</li> </ul>	No	<ul style="list-style-type: none"> <li>• Positive amastigote in BM aspiration</li> <li>• Promastigote in culture of BM aspiration</li> <li>• <i>L. tropica</i> identified by PCR, isoenzymes AND monoclonal antibody</li> </ul>	Responded to sodium antimony gluconate after 40 days	<ul style="list-style-type: none"> <li>• Improvement in symptoms</li> <li>• Decrease in splenomegaly,</li> <li>• Absence of parasites in repeat BM aspirates</li> </ul>
M, 13 years India (Vaishali), 1990–92 (Sacks et al. 1995)	No	<ul style="list-style-type: none"> <li>• Malaise</li> <li>• Fever</li> <li>• Weight loss</li> <li>• Hepatosplenomegaly</li> <li>• Anaemia</li> <li>• Leucopenia</li> </ul>	PKDL	<ul style="list-style-type: none"> <li>• Positive amastigote in BM aspiration</li> <li>• Promastigote in culture of BM aspiration</li> <li>• <i>L. tropica</i> identified by PCR, isoenzymes AND monoclonal antibody</li> </ul>	Responded to sodium antimony gluconate after 90 days	<ul style="list-style-type: none"> <li>• Required three courses of treatment to improve symptoms</li> <li>• Decrease in splenomegaly</li> <li>• Absence of parasites in repeat BM aspirates</li> </ul>
Male, 8 years India (Samastipur), 1990–92 (Sacks et al. 1995)	No	<ul style="list-style-type: none"> <li>• Malaise</li> <li>• Fever</li> <li>• Weight loss</li> <li>• Hepatosplenomegaly</li> <li>• Anaemia</li> <li>• Leucopenia</li> </ul>	No	<ul style="list-style-type: none"> <li>• Positive amastigote in BM aspiration</li> <li>• Promastigote in culture of BM aspiration</li> <li>• <i>L. tropica</i> identified by PCR, isoenzymes AND monoclonal antibody</li> </ul>	Responded to sodium antimony gluconate after 40 days	<ul style="list-style-type: none"> <li>• Improvement in symptoms</li> <li>• Decrease in splenomegaly,</li> <li>• Absence of parasites in repeat BM aspirates</li> </ul>
Female, 2 years Kenya, 1981–82 (Mebrahtu et al. 1989)	No	<ul style="list-style-type: none"> <li>• Abdominal swelling</li> <li>• Fever</li> <li>• Malaise</li> <li>• Splenomegaly</li> </ul>	No	<ul style="list-style-type: none"> <li>• Positive amastigote in spleen aspiration</li> <li>• <i>L. tropica</i> identified by cellulose acetate electrophoresis using 11 enzymes</li> </ul>	<ul style="list-style-type: none"> <li>• Unresponse to sodium stibogluconate</li> <li>• Treated with pentamidine</li> <li>• Allopurinol</li> </ul>	<ul style="list-style-type: none"> <li>• Improvement in symptoms</li> <li>• Decrease in spleen size</li> <li>• Increase of weight</li> </ul>

Male, 9 years Kenya, 1981–82 (Mebrahtu et al. 1989)	No	<ul style="list-style-type: none"> <li>Splenomegaly</li> <li>BM involvement</li> </ul>	No	<ul style="list-style-type: none"> <li>Positive amastigote in BM</li> <li><i>L. tropica</i> identified by cellulose acetate electrophoresis using 11 enzymes</li> </ul>	<ul style="list-style-type: none"> <li>Unresponsive to sodium stibogluconate</li> <li>IV Glucantime (no improvement)</li> <li>Rifampicin (no improvement)</li> <li>Allopurinol</li> <li>Sbv 20 mg/kg plus allopurinol</li> <li>Pentamidine</li> </ul>	<ul style="list-style-type: none"> <li>Improvement in symptoms</li> <li>Decrease in spleen size</li> <li>Increase of weight</li> </ul>
Female, 17 years an Afghani girl who had lived in the USA, 2009 (Weiss et al. 2009)	Yes	<ul style="list-style-type: none"> <li>Weight loss</li> <li>Abdominal pain</li> <li>Splenomegaly</li> <li>Fatigue</li> <li>Pretibial ulcerations</li> <li>Anaemia</li> <li>Elevation in serum aspartate aminotransferase and alanine aminotransferase levels</li> </ul>	Yes	<ul style="list-style-type: none"> <li>Positive amastigote in histopathologic examination of skin lesion</li> <li>Positive promastigote in culture</li> <li>Positive anti-leishmania antibody in IFA</li> <li><i>L. tropica</i> identified by isoenzyme analysis</li> </ul>	<ul style="list-style-type: none"> <li>Intravenous sodium stibogluconate</li> </ul>	<ul style="list-style-type: none"> <li>Complete resolution of symptoms</li> <li>Resolve in splenomegaly and anaemia</li> <li>Improvement of ulcerations</li> </ul>

reported five cases of VL in the city of Tabuk in Saudi Arabia without evaluation of *Leishmania* species by specific diagnostic tests. We also could not find the full text of the article (Hanly et al. 1998). Also, one case had been reported in two different journals by the same authors in 1993 and 1995 (Hernández et al. 1993, 1995a); but, the last publication described further clinical manifestation of the patient (Hernández et al. 1995a). We also found five articles that reported six cases of VL in dog due to *L. tropica* (Guessous-Idrissi et al. 1997; Lemrani et al. 2002; Hajjaran et al. 2007; Mohebbali et al. 2011; Bamorovat et al. 2015; Sarkari et al. 2016). These cases are presented in supplementary Table 1.

### Countries

According to the Table 2, the cases were reported from 10 countries. *Leishmania tropica* was reported from Iran (five cases) (Alborzi et al. 2006, 2008; Jafari et al. 2010), American soldier returned from operation desert storm in Saudi Arabia (eight cases) (Magill et al. 1993), India (four cases) (Sacks et al. 1995), Kenya (two cases) (Mebrahtu et al. 1989) and the Afghan girl who lived in the USA (one case) (Weiss et al. 2009). *Leishmania major* was reported from Iran (two cases) (Karamian et al. 2007; Shafiei et al. 2014) and Burkina Faso (one case) (Barro-Traore et al. 2008). *Leishmania braziliensis* was reported from Brazil (two cases) (Gontijo et al. 2002; Silva et al. 2002) and an Italian man living in Venezuela (one case) (Hernández et al. 1993). *Leishmania mexicana* was reported from Colombia (Mestra et al. 2011) (one case) and Mexico (one case) (Ramos-Santos et al. 2000). One case of *L. amazonensis* was reported from Brazil (Aleixo et al. 2006) and one case of *Leishmania* variant that shared sequences of *L. braziliensis* and *L. mexicana* from Venezuela (Hernández et al. 1995b) (Table 2).

### Leishmania species

From 30 cases, old and new world *Leishmania* species were reported from 23 (76.7%) and seven (23.4%), respectively (Fig. 2). From the 23 cases with the old world species, *L. tropica* and *L. major* were reported from 20 (86.95%) and three (13.04%) cases, respectively (Tables 2–3). While, new world *Leishmania* species, including *L. braziliensis*, *L. mexicana* and *L. amazonensis* were reported from three (42.8%), two (28.57%) and one (14.28%) cases, respectively. Also, one article reported a case (14.28%) with a variant of *Leishmania* that shared sequences of *L. braziliensis* and *L. mexicana* (Tables 4 and 5).

### Sex and age of the patients

The infection was higher in male (24/30, 80%) than female (5/30, 16.7%) patients (Fig. 3 and Tables 3–5). The sex was not reported in a case report as well (Alborzi et al. 2006). From the old world *Leishmania*-infected patients, *L. tropica* was detected in 16 (80%) and three (15%) out of 20 cases of male and female patients, respectively (Table 1), but the sex was not reported in an *L. tropica*-infected patients (Alborzi et al. 2006). All of the three cases of *L. major* were reported from male patients (Table 4). From the seven cases with the new world *Leishmania*-infection, five (71.4%) and two (28.6%) cases were reported from male and female, respectively (Table 5).

Among the *L. tropica*-infected patients ( $n = 20$  cases), seven and six cases were reported from patients with age ranges of 2–15 and 17–50 years old, respectively. The age was not reported in six out of 20 *L. tropica*-infected patients (Table 3). All of the three *L. major*-infected patients were adult with age ranges of 31–53 years (Table 4). Among the seven patients with the new world *Leishmania* infection, six patients were in the adult aging ranges (19–43 years old) and one case was reported from an 8-year-old *L. amazonensis*-infected patient (Table 5).

**Table 4.** Visceral leishmaniasis caused by *Leishmania major* in human

Sex, age, country, year of case report and ref	Co-morbidity or Co-infection	Symptoms	Cutaneous lesion	Diagnostic method	Treatment	Outcome
Male, 53 years, Northeast Iran, 2012 (Shafiei et al. 2014).	<ul style="list-style-type: none"> <li>• HIV</li> <li>• Intravenous drug use</li> </ul>	<ul style="list-style-type: none"> <li>• Intermittent diarrhoea</li> <li>• Negative hepatosplenomegaly</li> </ul>	–	<ul style="list-style-type: none"> <li>• Positive amastigote in bone-marrow (BM)</li> <li>• Positive anti-<i>Leishmania</i> antibody by DAT</li> <li>• <i>L. major</i> identified by nested-PCR</li> </ul>	<ul style="list-style-type: none"> <li>• HAART therapy (zidovudine, lamivudine, nevirapine)</li> </ul>	Not reported
Male, 31 years, Iran (Bushehr Province), 2003 (Karamian et al. 2007)	HIV	<ul style="list-style-type: none"> <li>• Intermittent fever</li> <li>• Anorexia</li> <li>• Fatigue</li> <li>• Weight loss</li> <li>• Lymphadenopathy</li> <li>• Hepatomegaly</li> <li>• Splenomegaly</li> <li>• Pancytopenia</li> <li>• Anaemia</li> <li>• Leukopenia</li> </ul>	<ul style="list-style-type: none"> <li>• Cutaneous lesions in leg</li> </ul>	<ul style="list-style-type: none"> <li>• Positive amastigote in skin and lymph node smears</li> <li>• Negative amastigote in BM aspirates</li> <li>• Positive anti-<i>Leishmania</i> by IFA</li> <li>• <i>L. major</i> identified by nested-PCR</li> </ul>	<ul style="list-style-type: none"> <li>• No response to meglumine antimoniate</li> <li>• Treated with Amphotericin B</li> </ul>	<ul style="list-style-type: none"> <li>• The patient was successfully treated</li> <li>• No relapse was seen after a 4-year follow-up</li> </ul>
Male, 38 years, Burkina Faso, 2004 (Barro-Traore et al. 2008)	HIV	<ul style="list-style-type: none"> <li>• Disseminated leishmaniasis with BM involvement</li> </ul>	<ul style="list-style-type: none"> <li>• Papulonodular lesions</li> </ul>	<ul style="list-style-type: none"> <li>• –Amastigote in skin and bone marrow</li> <li>• Positive promastigote in culture of bone marrow</li> <li>• <i>Leishmania</i> spp. was identified by <i>L. major</i> zymodeme MON-74</li> </ul>	<ul style="list-style-type: none"> <li>• Antiretroviral therapy</li> <li>• Pentavalent antimonial compound</li> </ul>	Improvement in lesions



**Table 5.** Visceral leishmaniasis caused by *L. braziliensis*, *L. amazonensis* and *L. mexicana* in human

<i>Leishmania</i> species, sex, age, country, year of case report and ref	Co-morbidity or co-infection	Symptoms	Cutaneous manifestation	Diagnostic method	Treatment	Outcome
<i>L. braziliensis</i> , Male, 32 years, Brazil (Minas Gerais), 1996 (Gontijo et al. 2002)	• Kidney transplant recipient	• Cutaneous, visceral and ocular leishmaniasis • Fever • Hepatosplenomegaly • Leucopenia • Anaemia • Conjunctive hyperemia • Intense ocular pain • Bilateral endophthamitis • Low visual acuity • Pain in the legs and thorax	• Skin lesions • Purple pruriginous lesions	• Positive amastigote in BM, aqueous humour and vitreous body • Promastigote in culture of bone-marrow (BM) aspirates • Positive anti- <i>Leishmania</i> by IFA • <i>L. braziliensis</i> identified by PCR-RFLP and RAPD-PCR, isoenzyme analysis and multilocus enzyme electrophoresis (MLEE)	• Methylglucamin, • Topical mydriatic, corticosteroids and acetazolamide plus intravenous amphotericine B lipossomal • Antimonial compounds	Improvement in the haematological picture and regression of the hepatosplenomegaly  • No improvement in visual acuity • Heart failure and death after complication of the diseases
<i>L. braziliensis</i> , Male, 43 years, an Italian man living in Venezuela (Caracas), 1992 (Hernández et al. 1993, 1995a)	• HIV • Oropharyngeal candidiasis • <i>Pneumocystis carinii</i> pneumonia • Pleuro-pericardial tuberculosis	• Fever • Malaise • Anaemia • Dry cough • Dyspnoea • Oral thrush • Tachypnoea • Basal pulmonary rales • Splenomegaly	• Skin pallor • Maculopapular rash	• Positive anti- <i>Leishmania</i> antibody in ELISA • Positive amastigote in BM examination • <i>L. braziliensis</i> identified by PCR and dot-blot hybridization	• Trimethoprim/sulfamethoxasole and fluconazole • Meglumine antimonate • Molgramostim plus meglumine antimonite	• Excellent results in treatment with molgramostim plus meglumine antimonate
<i>L. braziliensis</i> , Female, 19 months, Brazil (Minas Gerais) 1998 (Silva et al. 2002)	HIV	• Fever • Fatigue • Weight loss • Pneumonia • Lymphadenomegaly • Hepatosplenomegaly • Malnutrition • Anaemia	–	• Amastigote in BM aspirate • Promastigote in culture of BM aspirate • Positive anti- <i>Leishmania</i> antibody in IFA • <i>L. braziliensis</i> identified by PCR and hybridization	• Antiretroviral drugs (zidovudine, didanosine) • IV Glucantime antimonial • IV gammaglobulin	The patient died due to respiratory failure and AIDS related pneumocytosis
<i>L. mexicana</i> , Male, 42 years, Northwestern Colombia, 2001 (Mestra et al. 2011)	• Renal transplant recipient • Lupus nephritis • CMV infection	• Anaemia • Thrombocytopenia • Leucopenia • Fever • Hepatosplenomegaly • Delirium • Respiratory symptoms • Bleeding gums • Coagulopathy		• Amastigotes in renal biopsy • Positive promastigote in BM culture • Positive anti- <i>Leishmania</i> antibody in IFA • <i>L. mexicana</i> identified by RFLP-PCR and IFA by monoclonal antibodies	• Benzinidazole • Mycophenolate mofetil • Gancyclovir • Methylprednisolone • Cyclosporine • Glucantime • Nifurtimox	The patient died due to complication of the diseases

(Continued)

Table 5. (Continued.)

<i>Leishmania</i> species, sex, age, country, year of case report and ref	Co-morbidity or co-infection	Symptoms	Cutaneous manifestation	Diagnostic method	Treatment	Outcome
		<ul style="list-style-type: none"> <li>• Pancytopenia</li> </ul>				
<i>L. mexicana</i> , Male, 36 years, Southern Mexico (Chiapas), 1997 (Ramos-Santos et al. 2000)	<ul style="list-style-type: none"> <li>• HIV</li> <li>• <i>Pneumocystis carinii</i> pneumonia</li> </ul>	<ul style="list-style-type: none"> <li>• Fever</li> <li>• Malaise</li> <li>• Hepatosplenomegaly</li> <li>• Dry cough</li> <li>• Dyspnoea</li> <li>• Anaemia</li> </ul>	• -	<ul style="list-style-type: none"> <li>• Positive PCR in BM biopsy</li> <li>• <i>L. mexicana</i> identified by PCR and dot-blot hybridization</li> <li>• Negative amastigote in liver biopsy</li> </ul>	Not reported	Not reported
Mixed <i>L. brazileinsis</i> and <i>L. mexicana</i> , Female, 20 years, Venezuela (Coro) 1992 (Hernández et al. 1995b)	HIV	<ul style="list-style-type: none"> <li>• Fever</li> <li>• Weight loss</li> <li>• Anaemia</li> <li>• Hepatosplenomegaly</li> </ul>	-	<ul style="list-style-type: none"> <li>• Amastigote in BM aspirate</li> <li>• <i>Leishmania</i> strain identified by PCR and dot-blot hybridization</li> </ul>	<ul style="list-style-type: none"> <li>• Meglumine antimonat</li> </ul>	<ul style="list-style-type: none"> <li>• Disappearance of fever</li> <li>• Decrease in spleen and liver size</li> <li>• The patient died due to complication of the diseases</li> </ul>
<i>L. amazonensis</i> , Male, 8 years, Brazil, 2005 (Aleixo et al. 2006)	-	<ul style="list-style-type: none"> <li>• Fever</li> <li>• Hepatosplenomegaly</li> <li>• Generalized adenopathy</li> <li>• Anaemia</li> <li>• Leukopenia</li> </ul>	-	<ul style="list-style-type: none"> <li>• Positive promastigote in culture of lymph nodes</li> <li>• <i>L. amazonensis</i> identified by Isoenzyme analysis</li> </ul>	<ul style="list-style-type: none"> <li>• Meglumine antimoniate</li> </ul>	<ul style="list-style-type: none"> <li>• Improvement in general status and the spleen and liver had</li> <li>• Returned to normal size</li> </ul>

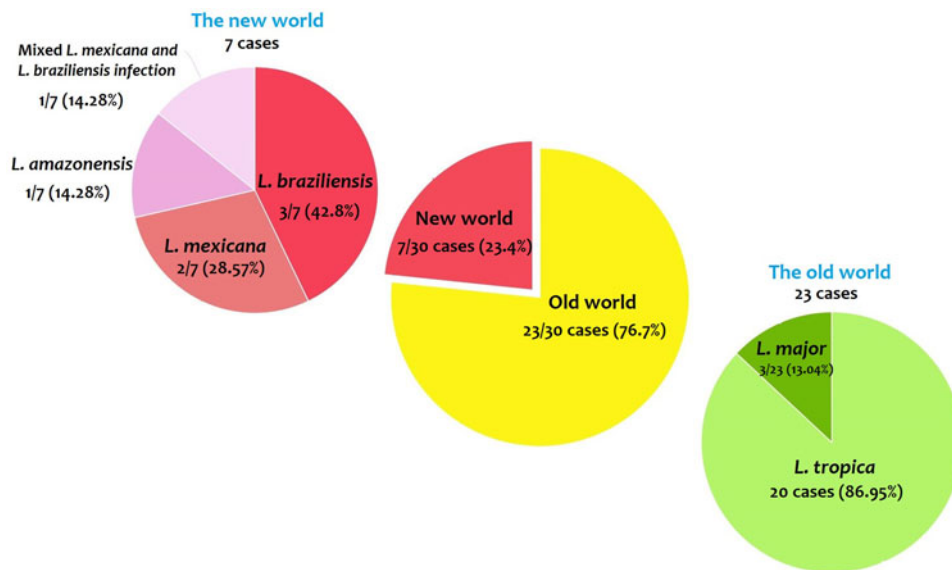


Fig. 2. Prevalence of the old and new world *Leishmania* species.

### Co-morbidity/co-infection

From the 30 cases, 13 (43.4%) patients had co-morbidity or co-infection (Fig. 4 and Tables 3–5). The highest co-morbidity/co-infection rate was reported from patients who infected by the new world *Leishmania* species (six out of seven cases, 85.7%). While seven out of 20 (35%) cases who infected by the new world *Leishmania* species had co-morbidity/co-infection. The most co-morbidity/co-infection was HIV/AIDS (10 out of 13 cases, 76.9%), kidney transplant recipient (two out of 13 cases, 15.4%) and renal carcinoma (one out of 13 cases, 7.69%) (Fig. 5). In patients with the new world *Leishmania* species infection, all three cases of *L. braziliensis* had co-morbidity/co-infection and were reported from a kidney transplant recipient (Gontijo et al. 2002), an HIV-positive patient (Silva et al. 2002) and an HIV-positive patient with *Pneumocystis carinii* pneumonia, oropharyngeal candidiasis and pleuro-pericardial tuberculosis (Hernández et al. 1993, 1995a) (Table 5). Two cases of *L. mexicana* were reported from a CMV-positive kidney transplant recipient (Mestra et al. 2011) and an HIV-positive patient with *P. carinii* pneumonia (Ramos-Santos et al. 2000) (Table 5). Also, the patient with mixed *L. braziliensis* and *L. mexicana* infection was HIV positive (Hernández et al. 1993, 1995a) (Table 5).

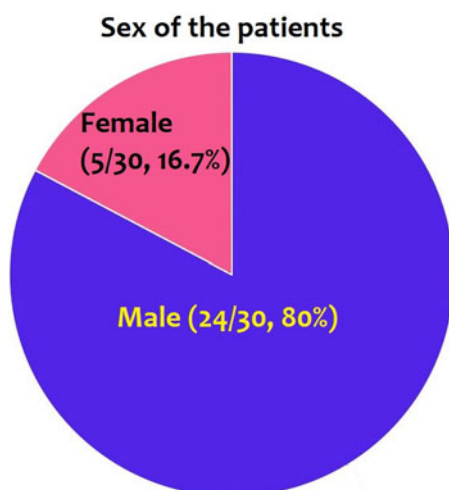


Fig. 3. Prevalence of the infection in males and females.

Co-morbidity/co-infection was reported from 20% (4/20) of *L. tropica*-infected patients (Fig. 5 and Table 3). *Leishmania tropica* was reported from one patient with HIV (Jafari et al. 2010), one patient with HIV–TB–HCV (Jafari et al. 2010) and one patient with renal carcinoma (Magill et al. 1993). All of the three cases of *L. major* were reported from HIV-positive patients (Table 5) (Karamian et al. 2007; Barro-Traore et al. 2008; Shafiei et al. 2014).

### Main clinical manifestations

In most of the patients, there were major symptoms of VL including fever, weight loss, hepatosplenomegaly, anaemia and leucopenia, but some patients had non-specific symptoms such as malaise, headache, cough or no symptoms (Tables 3–5). However, it seems that complication of the disease might be involved in the immunity of the patients so that more severe infections alongside with more non-specific symptoms had reported from patients with co-infection/co-morbidity. Duration of the disease is ambiguous because it not reported in the most of the cases. In addition, some cases had several co-morbidity/co-infection that might impact on the duration of infection (Tables 3–5).

Cutaneous lesions were reported in nine out of 30 cases (30.0%), among them, seven and one patients infected with old and new world *Leishmania* species, respectively. In patients who infected with the old world *Leishmania* species, cutaneous lesions were detected in five out of 20 patients with *L. tropica* infection (two patients had co-infection with HIV/AIDS) and (Alborzi et al. 2008; Weiss et al. 2009; Jafari et al. 2010; Mohebbali et al. 2011), two out of three *L. major*-infected patients (both cases had co-infection with HIV/AIDS) (Karamian et al. 2007; Barro-Traore et al. 2008). Among the patients with the new world *Leishmania* species infection, cutaneous lesions were reported in two cases of *L. braziliensis* infection who was a kidney transplant recipient patient (Gontijo et al. 2002) and an HIV-positive patient (Hernández et al. 1993, 1995a) (Tables 3–5).

### Diagnostic tests

Diagnosis of the infection was conducted by one or more diagnostic tests according to the symptoms of the patients (Tables 3–5).

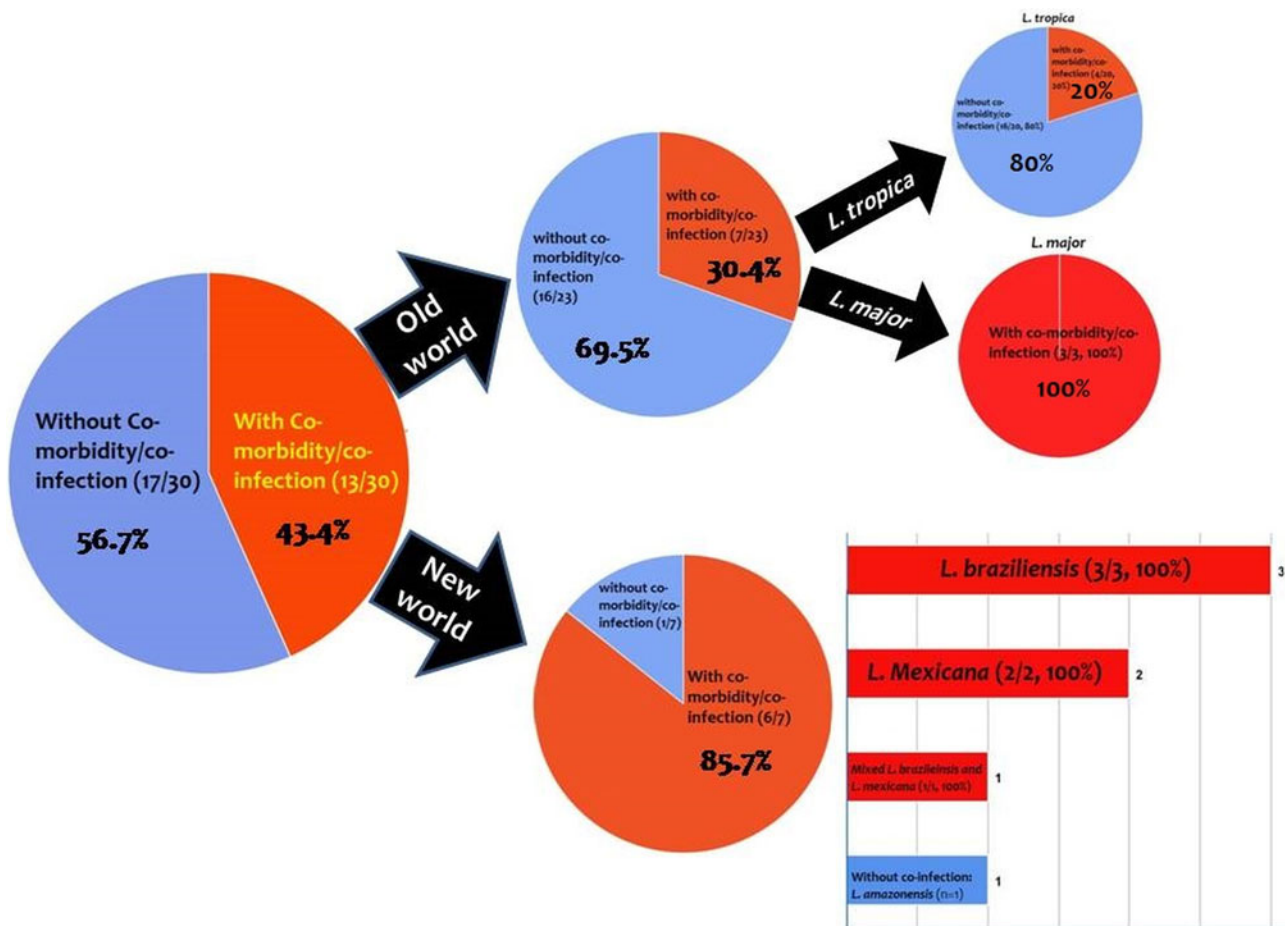


Fig. 4. Prevalence of co-infection/co-morbidity among the cases. Red: with co-infection/co-morbidity and blue: without co-infection/co-morbidity.

**Treatment**

Patients had mainly been treated with antimonial compounds so that the disease symptoms improved and liver and spleen size decreased or returned to normal size after treatment among the majority of the cases (Tables 3–5). However, five patients with *L. tropica* (Mebrahtu et al. 1989; Magill et al. 1993; Sacks et al. 1995; Alborzi et al. 2008) and one patient with *L. major* (Karamian et al. 2007) showed refractory to antimonial compounds and treated with other drugs (such as amphotericin B, pentamidine, miltefosine, etc.) (Tables 3 and 4). Also, one patient with *L. tropica* was resistant to amphotericin B (Alborzi et al. 2008) (Table 3). Some HIV-positive patients had also been

received anti-retroviral therapy (Hernández et al. 1993 1995a; Magill et al. 1993; Ramos-Santos et al. 2000; Silva et al. 2002; Karamian et al. 2007; Barro-Traore et al. 2008; Jafari et al. 2010; Shafiei et al. 2014) (Tables 3 and 5).

**Outcome**

Although most of the patients had healed following common anti-leishmanial therapy alone or in combination with other drugs (Tables 3–5), mortality had occurred in two kidney transplant recipients that infected with *L. braziliensis* (Gontijo et al. 2002) and *L. Mexicana* (Mestra et al. 2011) and one HIV-positive patient with mixed *L. braziliensis* and *L. mexicana* infection (Hernández et al. 1995b) (Table 5).

**Discussion**

Viscerotropic leishmaniasis is an interstitial form of leishmaniasis with some non-specific symptoms. These non-specific symptoms may be considered in endemic regions of CL, and also in immunocompromised patients to help differential diagnosis from other endemic diseases. CL is more distributed than VL worldwide, while the most cases of CL have been reported from Afghanistan, Algeria, Colombia, Brazil, Iran, Syria, Ethiopia, North Sudan, Costa Rica and Peru.

The results revealed that the main causative agent of viscerotropic leishmaniasis is *L. tropica*. In some regions, such as east and southeast of Iran (Sharifi et al. 2015; Karamian et al. 2016), Herat in Afghanistan (Mosawi and Dalimi, 2016) and north-western Pakistan (Khan et al. 2016), *L. tropica* is the predominant

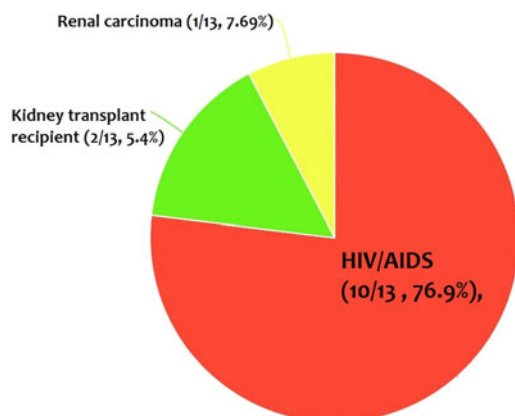


Fig. 5. The most co-infection/co-morbidity among the cases.

*Leishmania* species. In these regions, the viscerotropic manifestations of *L. tropica* should be considered more seriously.

Studies have shown that co-infection of leishmaniasis and HIV/AIDS is an important public health problem in different parts of the world (World Health Organization 2000; Monge-Maillo et al. 2014; Singh, 2014) as well as Iran (Shafiei et al. 2014). Co-morbidity with these two pathogens leads to rapid progression of the disease, development of more severe disease and a poor response to treatment (Singh, 2014). Several atypical presentations have been reported from CL patients, which most of them detected from HIV-infected individuals (Meireles et al. 2017). The results have shown that the majority of patients who infected with the new world *Leishmania* species and *L. major* had co-infection/co-morbidity such as HIV/AIDS (Figs 3 and 4). Therefore, viscerotropic leishmaniasis should be considered in patients with immunocompromising conditions.

Several studies have shown that higher prevalence of VL in male than female individuals (Guerin et al. 2002; Rodriguez et al. 2018), while a similar proportion in males and females had reported from CL patients (Karimkhani et al. 2016). We also found that higher prevalence of viscerotropic leishmaniasis in male than female cases (80% vs 167%). It is well documented that VL due to *L. donovani* infects all age groups, whereas *L. infantum* infects mostly children and immunosuppressed individuals (Chappuis et al. 2007). Also the majority of cases of American VL caused by *L. chagasi* occur in children (Evans et al. 1992; Pearson and de Queiroz Sousa, 1996; D'Oliveira Júnior et al. 1997). The results showed that the majority of the cases of viscerotropic leishmaniasis due to *L. major* and new world *Leishmania* species were reported from adults. In *L. tropica*, seven out of 20 cases were reported in patients under 15 years and the remaining cases were reported in adults (Table 3).

In conclusion, the results provide information regarding the species and clinical spectrum of viscerotropic leishmaniasis. Therefore, viscerotropic manifestations of CL in native people who live in endemic regions of CL should be considered for exact discrimination from other endemic infectious diseases. In patients who infected with *L. tropica*, a viscerotropic form of leishmaniasis should be more attended. Furthermore, viscerotropic leishmaniasis in patients with immunocompromising conditions and in non-native people who travel to the endemic regions of CL should be a greater consideration.

**Acknowledgements.** The authors wish to thank all researchers that their works were used in this review.

**Financial support.** This research received no specific grant from any funding agency, commercial or not-for-profit sectors

**Conflict of interest.** None.

**Ethical standards.** This manuscript is a review article and does not involve a research protocol for human and/or animal experimentation requiring approval by the relevant institutional review board or ethics committee.

**Supplementary Material.** The supplementary material for this article can be found at <https://doi.org/10.1017/pao.2018.9>

## References

- Alborzi A, Rasouli M and Shamsizadeh A (2006) *Leishmania tropica*-isolated patient with visceral leishmaniasis in southern Iran. *American Journal of Tropical Medicine and Hygiene* **74**, 306–307.
- Alborzi A, et al. (2008) Isolation of *Leishmania tropica* from a patient with visceral leishmaniasis and disseminated cutaneous leishmaniasis, southern Iran. *American Journal of Tropical Medicine and Hygiene* **79**, 435–437.
- Aleixo J, et al. (2006) Atypical American visceral leishmaniasis caused by disseminated *Leishmania amazonensis* infection presenting with hepatitis and adenopathy. *Transactions of the Royal Society of Tropical Medicine and Hygiene* **100**, 79–82.
- Alvar J, et al. (2012) Leishmaniasis worldwide and global estimates of its incidence. *PLoS ONE* **7**, e35671.
- Bamorovat M, et al. (2015) *Leishmania tropica* in Stray Dogs in Southeast Iran. *Iranian Journal of Public Health* **44**, 1359–1366.
- Barral A, et al. (1986) Isolation of *Leishmania mexicana amazonensis* from the bone marrow in a case of American visceral leishmaniasis. *The American Journal of Tropical Medicine and Hygiene* **35**, 732–734.
- Barro-Traore F, et al. (2008) Cutaneous leishmaniasis due to *Leishmania major* involving the bone marrow in an AIDS patient in Burkina Faso. *Annales de Dermatologie et de Venereologie* **135**, 380–383.
- Chappuis F, et al. (2007) Visceral leishmaniasis: what are the needs for diagnosis, treatment and control? *Nature Reviews Microbiology* **5**, 873.
- Choi CM and Lerner EA (2001) Leishmaniasis as an emerging infection. *Journal of Investigative Dermatology Symposium Proceedings* **6**, 175–182.
- D'Oliveira Júnior A, et al. (1997) Asymptomatic *Leishmania chagasi* infection in relatives and neighbors of patients with visceral leishmaniasis. *Memórias do Instituto Oswaldo Cruz* **92**, 15–20.
- Dillon DC, et al. (1995) Characterization of a *Leishmania tropica* antigen that detects immune responses in Desert Storm viscerotropic leishmaniasis patients. *Proceedings of the National Academy of Sciences of the United States of America* **92**, 7981–7985.
- Evans TG, et al. (1992) Epidemiology of visceral leishmaniasis in northeast Brazil. *Journal of Infectious Diseases* **166**, 1124–1132.
- Gontijo CM, et al. (2002) Concurrent cutaneous, visceral and ocular leishmaniasis caused by *Leishmania (Viannia) braziliensis* in a kidney transplant patient. *Memorias do Instituto Oswaldo Cruz* **97**, 751–753.
- Guerin PJ, et al. (2002) Visceral leishmaniasis: current status of control, diagnosis, and treatment, and a proposed research and development agenda. *The Lancet Infectious Diseases* **2**, 494–501.
- Guessous-Idrissi N, et al. (1997) Short report: *Leishmania tropica*: etiologic agent of a case of canine visceral leishmaniasis in northern Morocco. *American Journal of Tropical Medicine and Hygiene* **57**, 172–173.
- Hajjaran H, et al. (2007) *Leishmania tropica*: another etiological agent of canine visceral leishmaniasis in Iran. *Iranian Journal of Public Health* **36**, 85–88.
- Hanly M, Amaker B and Quereshi I (1998) Visceral leishmaniasis in North West Saudi Arabia: a new endemic focus of *L. donovani* or further evidence of a changing pathogenic role for *L. tropica*? *Central African Journal of Medicine* **44**, 202–205.
- Hernández D, et al. (1993) *Leishmania braziliensis* causing visceral leishmaniasis in a patient with human immunodeficiency virus infection, identified with the aid of the polymerase chain reaction. *Transactions of the Royal Society of Tropical Medicine and Hygiene* **87**, 627–628.
- Hernández DE, et al. (1995a) Visceral leishmaniasis with cutaneous and rectal dissemination due to *Leishmania braziliensis* in acquired immunodeficiency syndrome (AIDS). *International Journal of Dermatology* **34**, 114–115.
- Hernández DE, et al. (1995b) Visceral leishmaniasis due to a *Leishmania* variant that shares kinetoplast DNA sequences with *Leishmania braziliensis* and *Leishmania mexicana* in a patient infected with human immunodeficiency virus: identification of the *Leishmania* species with use of the polymerase chain reaction. *Clinical Infectious Diseases* **21**, 701–702.
- Jafari S, et al. (2010) Disseminated leishmaniasis caused by *Leishmania tropica* in HIV-positive patients in the Islamic Republic of Iran. *Eastern Mediterranean Health Journal* **16**, 340–343.
- Karamian M, et al. (2007) *Leishmania major* infection in a patient with visceral leishmaniasis: treatment with Amphotericin B. *Parasitology Research* **101**, 1431–1434.
- Karamian M, et al. (2016) Phylogenetic structure of *Leishmania tropica* in the new endemic focus Birjand in East Iran in comparison to other Iranian endemic regions. *Acta Tropica* **158**, 68–76.
- Karimkhani C, et al. (2016) Global burden of cutaneous leishmaniasis: a cross-sectional analysis from the Global Burden of Disease Study 2013. *Lancet Infectious Diseases* **16**, 584–591.
- Khan NH, et al. (2016) Cutaneous Leishmaniasis in Khyber Pakhtunkhwa Province of Pakistan: clinical diversity and species-level diagnosis. *American Journal of Tropical Medicine and Hygiene* **95**, 1106–1114.
- Kwon Y, et al. (2015) Identifying and removing duplicate records from systematic review searches. *Journal of the Medical Library Association: JMLA* **103**, 184–188.

- Lemrani M, Nejjar R and Pralong F** (2002) A new *Leishmania tropica* zymodeme-causative agent of canine visceral leishmaniasis in northern Morocco. *Annals of Tropical Medicine & Parasitology* **96**, 637–638.
- Lukeš J, et al.** (2007) Evolutionary and geographical history of the *Leishmania donovani* complex with a revision of current taxonomy. *Proceedings of the National Academy of Sciences of the United States of America* **104**, 9375–9380.
- Magill AJ, et al.** (1993) Visceral infection caused by *Leishmania tropica* in veterans of Operation Desert Storm. *New England Journal of Medicine* **328**, 1383–1387.
- McGwire BS and Satoskar AR** (2014) Leishmaniasis: clinical syndromes and treatment. *QJM* **107**, 7–14.
- Mebrahtu Y, et al.** (1989) Visceral leishmaniasis unresponsive to pentostam caused by *Leishmania tropica* in Kenya. *American Journal of Tropical Medicine and Hygiene* **41**, 289–294.
- Meireles CB, et al.** (2017) Atypical presentations of cutaneous leishmaniasis: a systematic review. *Acta Tropica* **172**, 240–254.
- Mestra L, et al.** (2011) Transfusion-transmitted visceral leishmaniasis caused by *Leishmania (Leishmania) mexicana* in an immunocompromised patient: a case report. *Transfusion* **51**, 1919–1923.
- Mohebbi M, et al.** (2011) Disseminated leishmaniasis caused by *Leishmania tropica* in a Puppy from Karaj, Central Iran. *Iranian Journal of Parasitology* **6**, 69–73.
- Mohr D, et al.** (2015) Preferred reporting items for systematic review and meta-analysis protocols (PRISMA-P) 2015 statement. *Systematic Reviews* **4**, 1.
- Monge-Maillo B, et al.** (2014) Visceral leishmaniasis and HIV coinfection in the Mediterranean region. *PLoS Neglected Tropical Diseases* **8**, e3021.
- Monroy-Ostria A, Hernandez-Montes O and Barker DC** (2000) Aetiology of visceral leishmaniasis in Mexico. *Acta Tropica* **75**, 155–161.
- Mosawi S and Dalimi A** (2016) Molecular detection of *Leishmania* spp. isolated from cutaneous lesions of patients referred to Herat regional hospital, Afghanistan. *Eastern Mediterranean Health Journal* **21**, 878–884.
- Murray HW, et al.** (2005) Advances in leishmaniasis. *Lancet* **366**, 1561–1577.
- Pearson RD and de Queiroz Sousa A** (1996) Clinical spectrum of leishmaniasis. *Clinical Infectious Diseases* **22**, 1–13.
- Quinnell RJ and Courtenay O** (2009) Transmission, reservoir hosts and control of zoonotic visceral leishmaniasis. *Parasitology* **136**, 1915–1934.
- Ramos-Santos C, et al.** (2000) Visceral leishmaniasis caused by *Leishmania (L.) mexicana* in a Mexican patient with human immunodeficiency. *Memorias do Instituto Oswaldo Cruz* **95**, 729–733.
- Rodríguez NE, et al.** (2018) Epidemiological and experimental evidence for sex-dependent differences in the outcome of *Leishmania infantum* infection. *American Journal of Tropical Medicine and Hygiene* **98**, 142–145.
- Sacks DL, et al.** (1995) Indian kala-azar caused by *Leishmania tropica*. *Lancet* **345**, 959–961.
- Sarkari B, et al.** (2016) Molecular evaluation of a case of visceral leishmaniasis due to *Leishmania tropica* in southwestern Iran. *Iranian Journal of Parasitology* **11**, 126–130.
- Shafiei R, et al.** (2014) Emergence of co-infection of visceral leishmaniasis in HIV-positive patients in northeast Iran: a preliminary study. *Travel Medicine and Infectious Disease* **12**, 173–178.
- Sharifi I, et al.** (2015) A comprehensive review of cutaneous leishmaniasis in Kerman Province, Southeastern Iran-narrative review article. *Iranian Journal of Public Health* **44**, 299–307.
- Silva ESd, et al.** (2002) Visceral leishmaniasis caused by *Leishmania (Viannia) braziliensis* in a patient infected with human immunodeficiency virus. *Revista do Instituto de Medicina Tropical de São Paulo* **44**, 145–149.
- Singh S** (2014) Changing trends in the epidemiology, clinical presentation, and diagnosis of *Leishmania*-HIV co-infection in India. *International Journal of Infectious Diseases: Official Publication of the International Society for Infectious Diseases* **29**, 103–112.
- Weiss F, et al.** (2009) *Leishmania tropica*-induced cutaneous and presumptive concomitant viscerotropic Leishmaniasis with prolonged incubation. *Archives of Dermatology* **145**, 1023–1026.
- World Health Organization** (2000) *Who Report on Global Surveillance of Epidemic-Prone Infectious Diseases*. Geneva: World Health Organization.